

## Ruptured hepatocellular carcinoma in a patient with chronic hepatitis C and a sustained viral response

Kalıcı viral yanıtı olan kronik hepatit C hastasında hepatosellüler kanser rüptürü

✉ Firdevs TOPAL<sup>1</sup>, ✉ Sabiye AKBULUT<sup>2</sup>, ✉ Fatih Esad TOPAL<sup>3</sup>, ✉ Şebnem KARASU<sup>4</sup>

Departments of <sup>1</sup>Gastroenterology, <sup>3</sup>Emergency and <sup>4</sup>Radiology, Katip Çelebi University Atatürk Training and Research Hospital, İzmir, Turkey

Department of <sup>2</sup>Gastroenterology, University of Health Sciences, Kartal Koşuyolu Yüksek İhtisas Training and Research Hospital, İstanbul, Turkey

Dear Editor,

Hepatitis C virus (HCV) is one of the most common causes of chronic liver disease in the world (1). The goal of chronic hepatitis C therapy is to prevent cirrhosis of the liver and hepatocellular carcinoma (HCC) by achieving a sustained virologic response (SVR). It has been reported that telaprevir-based triple therapy enabled 60%–70% SVR in genotype 1 (G1) patients (2,3).

The 74-year-old male patient was diagnosed with chronic hepatitis C 6 years ago, and peginterferon (P) + ribavirin (R) therapy was initiated. As HCV-RNA positivity continued in the 24<sup>th</sup> week of treatment, the patient was considered unresponsive, and his treatment was concluded. With the introduction of telaprevir into the therapy approximately one year later, the G1b patient was started on a triple therapy (telaprevir, PR) for 12 weeks followed by a 36-week course of double therapy (PR); thereby, his treatment was completed in a total of 48 weeks. The patient, who now had SVR, has been followed up in the 4 years since the completion of his therapy by carrying out tests on his HCV-RNA and alpha-fetoprotein (AFP) levels, alongside abdominal ultrasonography (ABD USG) performed every 6 months.

The patient, who presented to the emergency department with a complaint of severe abdominal pain reflecting on his right shoulder about 4 months after his latest follow-up, had a heterogeneous solid mass about 6 cm in size in his eighth liver segment alongside free fluid in the perihepatic and pelvic areas, as revealed by ABD USG. The results of testing showed that the patient had a high AFP level of 36 ng/mL (0–8.1).

The results of all abdominal computed tomography scans carried out in view of these findings showed that the patient's liver was of a normal size with no pronounced undulation of the contours. A heterogeneous solid mass lesion about 67 × 73 × 68 mm in size growing toward the subdiaphragmatic space in liver segment 8 was observed to reveal a hyperdense, possibly arterial contrasting image; the presence of high-density fluid around the mass in the subdiaphragmatic space was also visualized. Consequently, the rapidly contrasting arterial mass on the hepatic dome was diagnosed as HCC (?), hepatic adenoma (?), and a ruptured mass, and it was recommended that the patient undergo dynamic magnetic resonance (MR). A T1A hypointense, T2A mildly hyperintense heterogeneous solid mass, 63 × 70 mm in size with fine borders and irregular contours, was visualized on the dome level of the eighth segment of the right lobe (Figure 1).

As a result, the patient was diagnosed with spontaneous rupture of the mass because of his high AFP levels, the presence of a solid mass concordant with HCC, contour irregularity neighboring the superior, and signs of hemoperitoneum observed in the perihepatic area. The patient was taken into surgery and died in the perioperative period.

The risk of HCC development in patients with SVR through direct-acting antiviral (DAA) has proven to be a controversial issue (4,5). Patients with SVR through DAA administration should be followed up every 6 months with regards to ABD USG results and AFP levels.

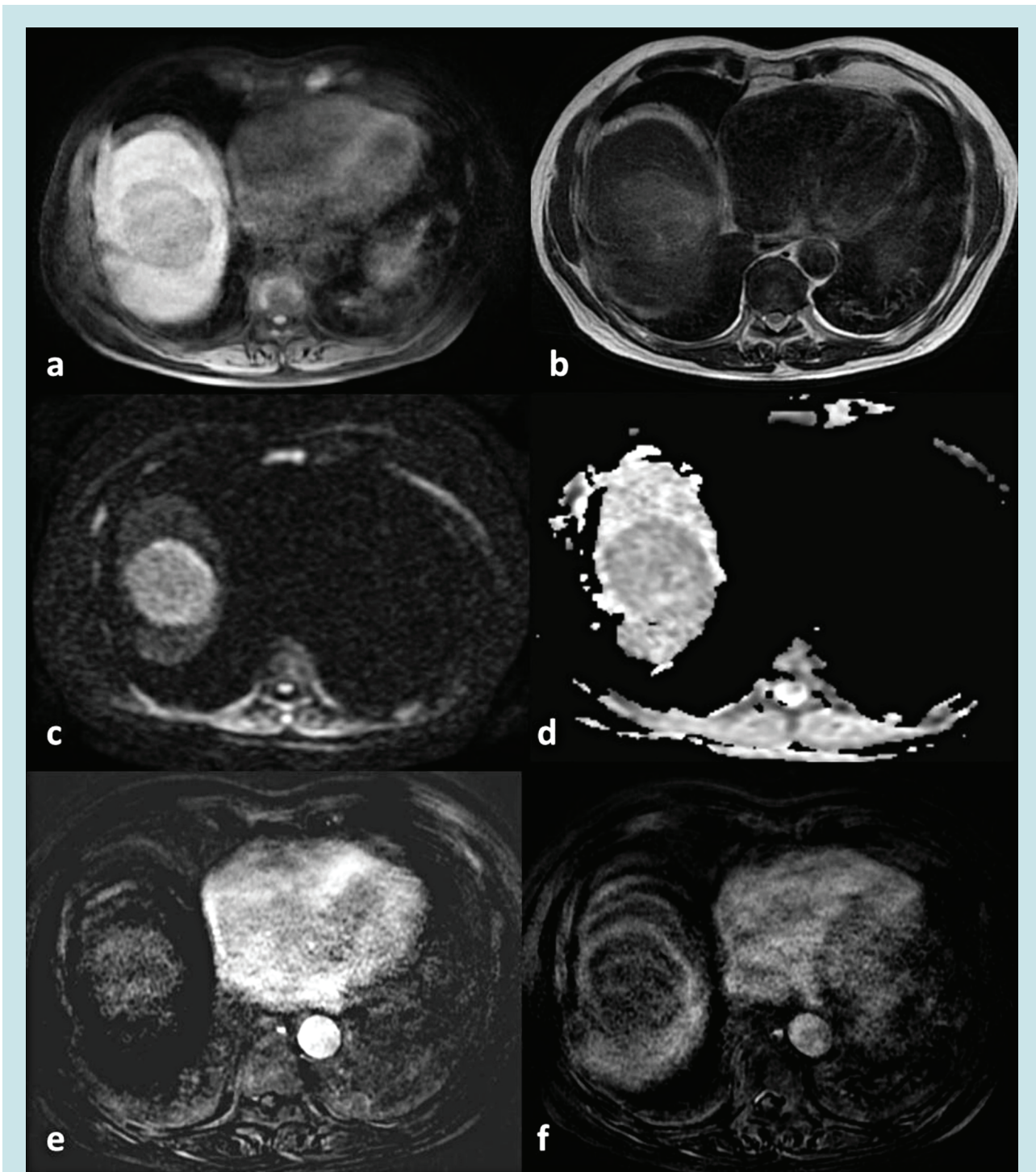
*This manuscript was presented at the Turkish Association for the Study of the Liver (TASL) and the European Association for the Study of the Liver (EASL) Educational Conference as a poster presentation on March 03, 2018 in İstanbul/Turkey*

*Topal F, Akbulut S, Topal FE, et al. Ruptured hepatocellular carcinoma in a patient with chronic hepatitis C and a sustained viral response. The Turkish Journal of Academic Gastroenterology 2019;18:126-128. DOI: 10.17941/agd.682162*

**Geliş Tarihi:** 06.08.2018 • **Kabul Tarihi:** 10.10.2018

**İletişim:** Sabiye AKBULUT

Department of Gastroenterology, University of Health Sciences, Kartal Koşuyolu High Specialty Training and Research Hospital, İstanbul, Turkey  
Tel: +90 216 459 63 21 • E-mail: sabiye4@hotmail.com



**Figure 1.** On abdominal MR images, the hepatocellular carcinoma is seen as a T1 hypointense (a), T2 mildly hyperintense (b) solid mass in the right liver lobe. It is hyperintense on diffusion-weighted images (c) and hypointense on the apparent diffusion coefficient (ADC) map images (d), which is compatible with diffusion restriction. The mass is enhanced in the arterial phase of dynamic contrast-enhanced images (e) and is washed out in the portal venous phase (f), which is the typical contrast enhancement pattern of hepatocellular carcinoma.

## REFERENCES

1. Mangia A, Foster GR, Berg CP, et al; PegBase Group Investigators. Efficacy and safety profile of boceprevir- or telaprevir-based triple therapy or dual peginterferon alfa-2a or alfa-2b plus ribavirin therapy in chronic hepatitis C: The real-world PegBase observational study. *Ann Gastroenterol* 2017;30:327-43.
2. Furusyo N, Ogawa E, Nakamuta M, et al; Kyushu University Liver Disease Study (KULDS) Group. Telaprevir can be successfully and safely used to treat older patients with genotype 1b chronic hepatitis C. *J Hepatol* 2013;59:205-12.

3. Jacobson IM, McHutchison JG, Dusheiko G, et al; ADVANCE Study Team. Telaprevir for previously untreated chronic hepatitis C virus infection. *N Engl J Med* 2011;364:2405-16.
4. Waziry R, Hajarizadeh B, Grebely J, et al. Hepatocellular carcinoma risk following direct-acting antiviral HCV therapy: A systematic review, meta-analyses, and meta-regression. *J Hepatol* 2017;67:1204-12.
5. Alberti A, Piovesan S. Increased incidence of liver cancer after successful DAA treatment of chronic hepatitis C: Fact or fiction? *Liver Int* 2017;37:802-8.