

A Case of Silent Choledochal Cyst

Sessiz Koledok Kisti Olgusu

Dr. A. Melih Özel / Maltepe University, School of Medicine, Department of Gastroenterology

Dr. Gülbüz Sezgin / Baskent University, Medical Practice and Research Center, Department of Radiology

Dr. Burçak Gümüő / Maltepe University, School of Medicine, Department of Radiology

Dr. Evrim Dođan Köse / Baskent University, Medical Practice and Research Center, Department of Radiology

Dr. Evrim Bozkaya / Baskent University, Medical Practice and Research Center, Department of Radiology

Dr. Rahmi Çubuk / Maltepe University, School of Medicine, Department of Radiology

Dr. M. Nuri Kalkay / Maltepe University, School of Medicine, Department of Gastroenterology

Dr. Oya Uygur Bayramiçli / Maltepe University, School of Medicine, Department of Gastroenterology

ÖZET

Amaç: Koledok kistleri biliyer sistemin tamamını tutabilen ender hastalıklardır. Burada, üst abdominal distansiyon ile müracaat eden ve koledok kisti ile asemptomatik olarak 73 yaşına ulaşmış bir hasta sunulmaktadır.

Olgu: Karın şişliđi ile müracaat ettiđinde hipotansiyonu, asiti ve sađ üst kadranda yumuőak, hassas bir kitlesi mevcuttu. MRCP'de intrahepatik safra kanallarında dilatasyonla birlikte koledokun kistik dilatasyonunun varlıđı ile koledok kisti tanısı konuldu. Kardiyak deđerlendirme, sol kalp yetmezliđi ve sol atrial trombus varlıđını ortaya koydu. Kalp yetmezliđinin tedavisi ile asit düzeldi. Hastanın ko-morbiditeleri nedeni ile ne ERCP ne de cerrahi bir seçenek olarak deđerlendirildi. Porta hepatis seviyesinde koledoka bir pig-tail kateter yerleőtirildi ve gerekli drenaj sađlandı. Kesin cerrahi girişime karar vermeden önce bekleyip gözlemeye karar verildi. İki hafta sonra daha önce yerleőtirilen transabdominal kateter içerisinden bir kılavuz tel üzerinden bir internal stent yerleőtirildi. Birkaç gün içerisinde abdominal distansiyon tamamen kayboldu ve safra drenajı sađlandı. İzleyen günlerde hastanın kalp sorunları yinelendi ve stent uygulanmasından bir hafta sonra tromboembolik komplikasyonlarla hayatını kaybetti. Bu kadar uzun süre ile neden asemptomatik kaldıđı ve neden koledok kistine ait komplikasyonların gelişmediđi konuları oldukça şaşırtıcıdır.

Sonuç: Radikal bir cerrahi girişim öncesinde semptomatik tedavi ve "bekle ve gör" yaklaşımı dođru karar olabileceđi ve cerrahiye bir alternatif olarak perkütan girişimlerin daima akılda tutulması gerektiđini düşünüyöyoruz.

Anahtar Kelimeler: koledok kisti, asemptomatik, erişkin hasta, perkütan girişim

ABSTRACT

Objective: We report here a male patient with marked upper abdominal distention, hypotension, ascites and a mass on his right upper abdomen.

Case: He had cystic dilatation of choledochus with dilated intrahepatic biliary ducts in MRCP (choledochal cyst). He also had congestive heart failure with left atrial thrombus. A percutaneous pig tail catheter inserted in the choledochus provided drainage. Before deciding on definitive treatment we decided to wait and observe. Two weeks later, an internal stent was inserted. Abdominal distention disappeared and bile drainage was complete. He died of thromboembolic complications of cardiac failure a week after stent insertion. Why he remained asymptomatic and did not develop any complications for so long is an intriguing question.

Results: We believe that before deciding on surgery, symptomatic treatment and "wait and see" attitude could be the right decision, and percutaneous interventions should be kept in mind as an alternative.

Key Words: choledochal cyst, asymptomatic, adult patient, percutaneous intervention

INTRODUCTION

Choledochal cysts are very rare and controversial disorders that involve the entire (intra- and extrahepatic) biliary ductal system. The incidence of choledochal cyst in western countries has been reported to be 1:100,000 to 1:150,000(1). However, markedly higher incidence is reported, in the range of 1:1,000 in far eastern countries especially in Japan(2). In addition, there is also an unexplained higher incidence in female gender. Choledochal cysts occur more commonly in female than male individuals with a ratio as high as 8:1(3). Herein, we present an interesting case of silent choledochal cyst (type IV) in an elderly Turkish male who remained asymptomatic as far as choledochal cyst is concerned until the age of 73 when he presented to our hospital with a marked upper abdominal distention.

CASE REPORT

A 73-year-old male patient presented with anorexia and abdominal distention for two weeks. His past medical history revealed congestive heart failure for more than ten years. He has had a coronary angiography and stent placement recently. Pertinent physical findings were hypotension, ascites and a palpable mass on his right upper abdominal quadrant which was soft and mildly tender with apparent margins. He did not have jaundice, fever and any other gastrointestinal symptoms or signs. An abdominal Computed tomography revealed a markedly distended gall bladder (hydrops), mild dilatation of intrahepatic biliary ducts and a markedly dilated choledochus. Pancreatic head was heterogenous and edema was apparent on pancreatic head and uncinete process.

Laboratory findings showed no abnormalities except for moderate elevations of gamma glutamyl transpeptidase and alkaline phosphatase along with a high level of CA 19-9. Upper abdominal ultrasound showed ascites and mild dilation of right and left intrahepatic biliary ducts without significant dilatation in the distal intrahepatic biliary ducts were the findings. Choledochus was also dilated up to the level of the porta hepatis.

To evaluate biliary ducts abdominal MR and MRCP were ordered and revealed a cystic dilatation of choledochus with a diameter of 30 mm at its widest diameter. Intrahepatic biliary ducts were also dilated. Distal intrahepatic biliary ducts were normal. Main pancreatic duct was also dilated (8 mm) and tortuous throughout the length of the pancreas (Figure 1).

Our diagnosis was choledochal cyst (type IV) with accompanying distention of the gall bladder and chronic pancreatitis.

Cardiac evaluation and echocardiography revealed congestive heart failure (CHF) with atrial fibrillation and left atrial thrombus. Ascites was thought to be due to CHF and with appropriate medical treatment heart failure resolved,

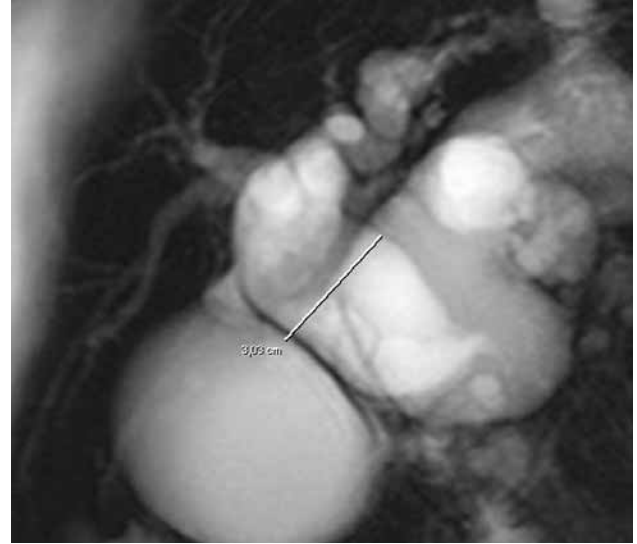


Figure-1a. MRCP revealed cystic dilatation of choledochus with a diameter of 30 mm at its widest diameter. Intrahepatic biliary ducts were also dilated. Distal intrahepatic biliary ducts were normal. Superposition of cyst and gall bladder was apparent

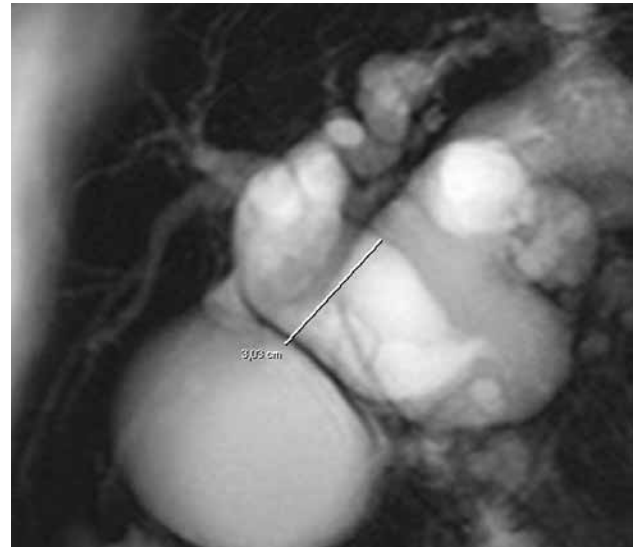


Figure-1b. Main pancreatic duct was dilated (8 mm) and tortuous throughout the length of the pancreas (arrows)

ascites regressed.

Neither ERCP with the fear of causing infection nor surgery was an option for biliary drainage because of his co-morbid conditions. We decided to obtain biliary drainage through percutaneous intervention. A pig tail catheter was inserted by the radiologist in the choledochus at the level of the porta hepatis under ultrasound guidance which provided the required biliary drainage. Culture and sensitivity, cytology, amylase and lipase levels were normal in biliary drainage fluids.

Before making a decision on the definitive surgical treatment we decided to wait and observe his progress. The patient's cardiac and biliary complaints regressed remarkably within couple of days after intervention. He

was discharged home with appropriate cardiac medications and biliary drainage catheter. A week after his discharge he was readmitted to the hospital with copious amount of drainage of retained bile, dehydration and pre-renal azotemia. Standard treatment for renal insufficiency resolved the problems. Two weeks later, an internal stent was inserted over a guide wire through the previously inserted percutaneous trans-abdominal catheter (Figure 2).

In the following days his abdominal distention disappeared and bile drainage was complete through the stent. Unfortunately the patient's cardiac problems recurred and he died of thromboembolic complications a week after stent insertion.

DISCUSSION

Since its first description in 1723, discussions about the etiopathogenesis, clinical signs and symptoms, complications, classification and optimal treatments of choledochal cysts continue unabated: Is it a congenital disorder? Is it an acquired disorder? Is it a combination of both? Are choledochal cysts different diseases lumped together for the sake of simplification? After 300 years since its first description, these questions are still being hotly debated with no convincing answers (4).

Our patient, according to Todani modification (5) of Alonso-Lej classification (6), can be classified as type IV (Figure 1). Consequently we remained puzzled about our patient as to why he remained asymptomatic for so long?

When we searched the medical literature with this question in mind we found very little convincing answers (4,7,8). However Drs Singham, Yoshida and Scudamore in their recent extensive 3-part review article on choledochal cysts postulated that abnormal pancreaticobiliary duct junction (APBDJ) and amount of reflux of pancreatic juices into biliary ductal system play the most important role in etiopathogenesis of choledochal cysts. The more the reflux is, the more the cysts development and its complications are. On the other hand low level of reflux causes more insidious illness and complications. Consequently signs and symptoms of the disease appear later in life. We believe that this theory could describe our patient's condition the best. The most common reported presenting symptom in the literature in adult patients with choledochal cysts is abdominal pain. Our patient did not have pain, instead he presented with abdominal distention. Other commonly reported symptoms like weight loss and jaundice were also absent in our case. The literature also states that almost all patients who did not undergo cystectomy or hepaticoenterostomy develops malignancy (4). Interestingly, our patient did not have any malignancy.

Usually the symptoms of choledochal cysts are caused by complications of the primary illness such as ascending cholangitis, pancreatitis, stone formation, jaundice, spontaneous rupture of cyst's content and ensuing bile

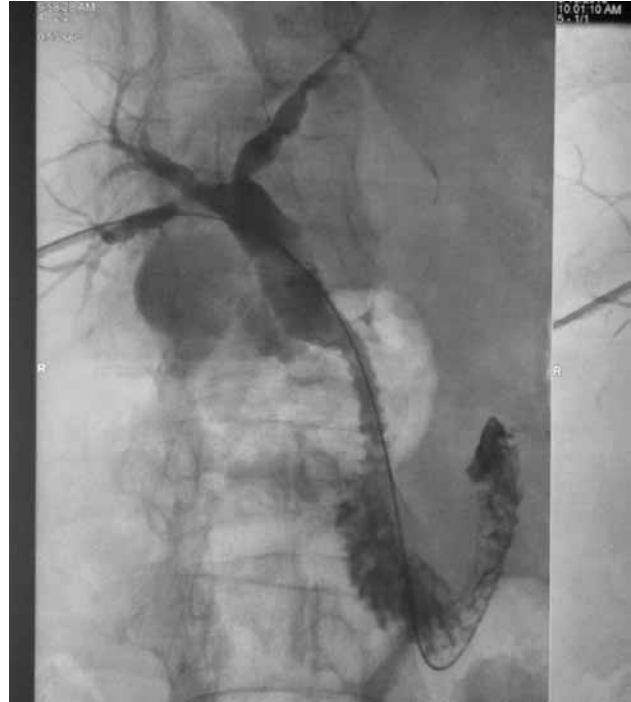

Figure-2a. An internal stent (arrow) was inserted over a guide wire through the previously inserted percutaneous trans-abdominal catheter

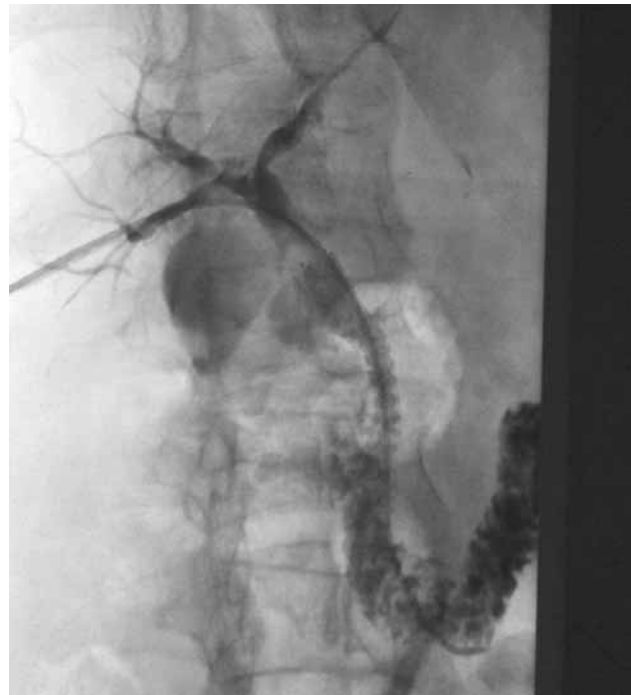

Figure-2b. Drainage of contrast material through the stent was immediate

peritonitis and carcinogenesis (7,8).

Why our patient did not develop any of these complications? Or was he a very stoic man, simply ignored his complaints? Although MRCP and PTC in our patient showed the evidence of chronic pancreatitis such as

tortuous and dilated pancreatic ducts, he has had no pain and no evidence of endocrine or exocrine pancreatic insufficiency. Neither did he have jaundice, biliary stone formation, fever or carcinoma.

There is always an exception to the rule. Maybe in some patients things are not as gloomy as medical literature insinuates. Before subjecting an elderly patient, like ours, to a radical surgical treatment, symptomatic treatment and "wait and see" attitude sometimes could be the right decision, and percutaneous interventions should always be kept in mind as an alternative to surgery.

REFERENCES

- 1) de Vries JS, de Vries s, Aronson DC. Choledochal cysts: age of presentation, symptoms, and late complications related to Todani's classification. *J Paediatr Surg.* 2002; 37: 1568-1573.
- 2) Mujano T, Yamataka A. Choledochal cyst. *Curr Opin Pediatr.* 1997;9:283-288.
- 3) Soreide K, Korner H, Havnen J. Soreide JA. Bile duct cysts in adults. *Br J Surg* 2004; 91: 1538-1548.
- 4) Singham J, Yoshida EM, Scudamore CH. Choledochal cysts. *Can J Surg* 2009; 52: 434-511.
- 5) Todani T, Watanabe Y, Narusue M, et al. Congenital bile duct cysts: classification, operative procedures, and review of thirty-seven cases including cancer arising from choledochal cyst. *Am J Surg.* 1977; 134: 263-269.
- 6) Alonso-Lej F, Rever WB Jr, Pessagno DJ. Congenital choledochal cyst, with a report of 2, and an analysis of 94, cases. *Int Abstr Surg.* 1959; 108: 1-30.
- 7) Edil BH, Cameron JL, Reddy S, Lum Y, Lipsett PA, et al. Choledochal cyst disease in children and adults: a 30-year single-institution experience. *J Am Coll Surg.* 2008; 206: 1000-1005.
- 8) Visser BC, Suh I, Way LW, Kang SM. Congenital Choledochal Cysts in Adults. *Arch Surg.* 2004; 139: 855-862.