

ATRIOVENTRICULAR BLOCK THAT REQUIRED PACEMAKER IMPLANTATION IN A PATIENT WITH ANEURYSMAL CORONARY ARTERY DISEASE

KORONER ARTER ANEVİZMASI OLAN BİR HASTADA PACEMAKER İMPLANTASYONU GEREKTİREN ATRİOVENTRİKÜLER BLOK

Gökhan ERTAŞ, Ertan URAL, Teoman KILIÇ, Ahmet VURAL, Ender EMRE, Dilek URAL*

ABSTRACT

Aneurysmal coronary artery disease (ACAD) is an uncommon disease. The majority of the cases are detected accidentally by diagnostic coronary angiography during the evaluation of symptoms which developed due to myocardial ischemia. Although the relation between ACAD and myocardial ischemia was reported previously, there is no knowledge about whether ACAD itself or ACAD related myocardial ischemia are associated with development of conduction system disorder. In this case report, a patient with ACAD and who developed atrioventricular block that required pacemaker implantation is reported.

Key words: Coronary artery aneurysm, pacemaker, atrioventricular block

ÖZET

Anevizmal koroner arter hastalığı (AKAH) nadir görülen bir hastalıktır. Vakaların çoğu tesadüfen miyokardiyal iskemi nedeniyle oluşan semptomların koroner anjiyografi ile değerlendirilmesi sırasında saptanır. AKAH'nın miyokardiyal iskemi ile olan ilişkisi bilinmesine rağmen AKAH'na bağlı miyokardiyal iskemi sonucu oluşan ileti sistemi bozukluğu hakkında yeterli bilgi yoktur. Bu vakada kalp pili implantasyonu gerektiren atrioventriküler blok gelişen AKAH olan bir hasta sunuldu.

Anahtar kelimeler: Koroner arter anevizması, kalp pili, atrioventriküler blok

INTRODUCTION

Aneurysmal coronary artery disease (ACAD) has been defined as any coronary dilatation ≥ 1.5 -2 times the diameter of the normal adjacent or reference segments (1). The most common etiologic factor for coronary aneurysms is atherosclerotic coronary artery disease, but they can also be congenital or secondary to inflammatory or connective tissue disorders (3). Symptoms, if present, are usually related to myocardial ischemia. The relation between ACAD and severe conduction disorder has not been reported previously. In this report we present a case of ACAD developed atrioventricular block that required pacemaker implantation.

CASE

A 61 years old male was admitted to emergency service with bradycardia and presyncope. Patient had been complaining from *dizziness* for two weeks. He had hypertension for ten years. He was a non-smoker. There was no history of infectious, infiltrative, degenerative, metabolic or rheumatic disease and a drug use which could be a reason for AV block. Both of his parents had a history of myocardial infarction in their early ages. On admission, the ECG showed right bundle branch block (RBBB) with 2:1 AV block (Figure-1a). Echocardiography showed normal left ventricular systolic function and no valve or ring calcification. As symptomatic 2:1 AV block insisted, a VDDR pacemaker implantation had been performed successfully (Figure-1b). Coronary angiography had been performed because of severe chest pain one month before index presentation. There was no

conduction disorder except RBBB at that particular time. The coronary angiography revealed a diffuse coronary artery aneurysm and a slow flow without any narrowing in all three main coronary arteries (Figure-2). As all three coronary arteries were diffusely aneurysmatic, medical therapy was the unique alternative treatment strategy. The patient was managed conservatively with aspirin, statin and angiotensin-converting enzyme inhibitor after coronary angiography. One month later after this presentation, the dizziness and the presyncope have developed. The patient's complaints improved after pacemaker implantation and remained asymptomatic during follow-up.

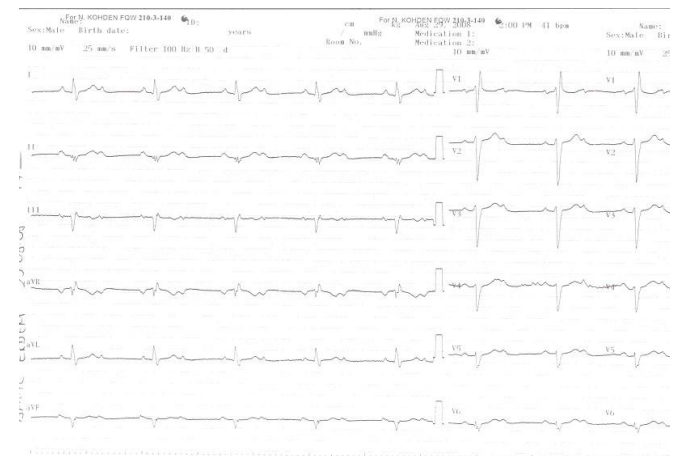


Figure 1a. Patient electrocardiogram on admission

Date received/Dergiye geldiği tarih: 01.02.2010 - Dergiye kabul edildiği tarih: 26.11.2010

* Kocaeli Üniversitesi Tıp Fakültesi, Kardiyoloji Anabilim Dalı, Kocaeli, Türkiye
(İletişim kurulacak yazar: drgokanertas@yahoo.com)

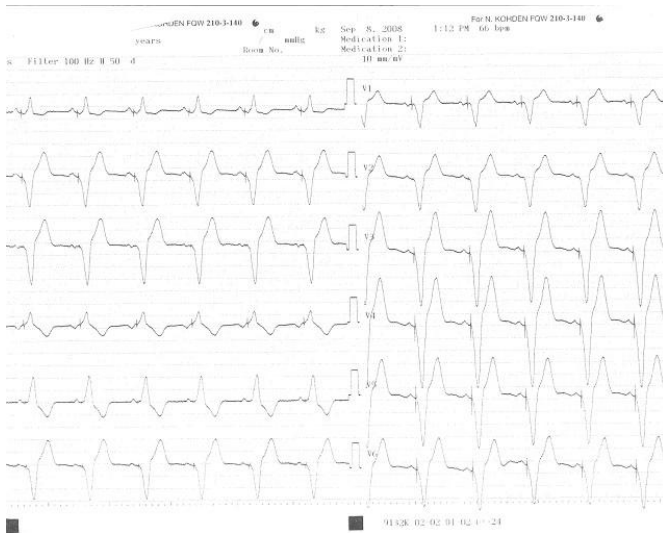


Figure 1b. Patient electrocardiogram after pacemaker implantation

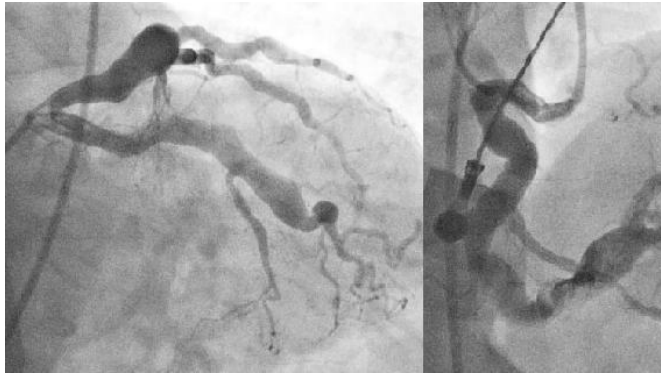


Figure 2. Left anterior descending coronary artery, circumflex coronary artery and right coronary artery aneurysm

DISCUSSION

ACAD is a rare cardiovascular pathology. Incidence of angiographic coronary aneurysmal disease has been reported between 0.3 to 4.9% (2). ACAD may be detected in the absence of symptoms, but the most common symptom is angina (3,4). However patients rarely present with myocardial infarction or sudden death.

Our case presented with a typical angina at the beginning. However the dizziness and the presyncope developed due to recent AV block during follow up.

Atrioventricular block may develop due to fibrosis and sclerosis of the conduction system, ischaemic heart disease, increased vagal tone, or drugs. Drugs that can reduce AV conduction include digitalis, calcium antagonists, β -blockers, quinidine and amiodarone. AV block inducing medications had not been given to the patient. There were no reasons such as infectious and metabolic causes, rheumatic or degenerative diseases, neuromuscular disorders or infiltrative processes that can cause AV block. So we suggested that this AV block might have developed due to aneurysmal coronary artery disease. This case demonstrates an unusual cause of symptomatic AV block. The slow flow in the right aneurysmal coronary artery might have caused an ischemia in the AV nodal artery which progressed to an AV block. To our knowledge, causal relationship between ACAD and the AV block has not been reported previously.

CONCLUSION

Our case demonstrates that ACAD and slow flow in the coronary artery can be one of the reasons of AV conduction block, which can be very severe to require a pacemaker implantation.

REFERENCES

1. Chrissoheris MP, Donohue TJ, Young RSK, Ghantous A. Coronary artery aneurysms. *Cardiology in Review* 16 : 116-123, 2008.
2. Giannoglou G, Antoniadis A, Chatzizisis Y, Damvopoulou E, Parcharidis GE, Louridas GE. Prevalence of ectasia in human coronary arteries in patients in northern Greece referred for coronary angiography. *Am J Cardiol* 98: 314-318, 2006.
3. Nichols L, Lagana S, Parwani A. Coronary artery aneurysm: a review and hypothesis regarding etiology. *Arch Pathol Lab Med* 132:823-828, 2008.
4. Yu WQ, Shou HS, Tao QS. Surgical treatment of giant coronary artery aneurysm. *Asian Cardiovasc Thorac Ann* 9:215-217, 2001.