

RECURRENT MENINGITIS AND HOLOCORD SUBDURAL ABSCESS CAUSED BY SPINAL DERMOID CYST

SPİNAL DERMİD KİSTE BAĞLI REKÜRRENT MENENJİT VE HOLOKORD SUBDURAL ABSE

Atilla ARSLANOĞLU*, Bayram ÇIRAK**

ABSTRACT

Spinal subdural abscess caused by spread of infection via the dermal sinus tract is rare in children. Here, we present a hydrocephalus caused by recurrent meningitis arising from subdural abscess and infected dermoid tumor. A 4 year-old-boy was admitted to our clinic with the diagnosis of meningitis. Further evaluation disclosed a spinal dermoid tumor and subdural abscess associated with hydrocephalus. Dermoid tumor was resected surgically and antibiotherapy was started. A ventriculoperitoneal shunt has been inserted for hydrocephalus. In conclusion, recurrent meningitis may be caused by infected spinal dermoid tumor. In rare cases, spinal dermoid tumor may even cause subdural abscess. Thus, spinal evaluation of recurrent meningitis is mandatory. A clear cerebrospinal fluid (CSF) obtained using a ventricular puncture does not exclude spinal infectious foci.

Key words: Dermoid tumor, dermoid sinus, recurrent meningitis, spinal subdural abscess.

ÖZET

Dermal sinus enfeksiyonunun yayılımıyla oluşan spinal subdural abse çocuklarda nadirdir. Bu olguda enfekte dermoid tümör ve subdural abseye bağlı gelişen rekürren menenjit ve hidrosefali sunulmuştur. 4 yaşındaki erkek çocuk menenjit tanısıyla kliniğimize kabul edilmiştir. Sonrasında hastada spinal dermoid tumor ve hidrosefali ile seyreden subdural abse saptanmıştır. Dermoid tumor rezekt edilip antibiyotik tedavisine başlanmıştır. Hidrosefali tedavisi için ventriküloperitoneal shunt yerleştirilmiştir. Sonuç olarak, rekürren menenjit, enfekte dermoid tümöre bağlı gelişebilmektedir. Daha da nadir olarak da spinal dermoid tumor subdural abseye neden olabilmektedir. Bu nedenle rekürren menenjitlerde spinal inceleme gerekmektedir. Ventriküler ponksiyondan normal beyin omurilik sıvısı (BOS) gelmesi spinal enfeksiyon odağını ekarte ettirmektedir.

Anahtar kelimeler: Dermoid tümör, dermoid sinüs, rekürren menenjit, spinal subdural abse

INTRODUCTION

Spinal subdural abscess caused by spread of infection via the dermal sinus tract is rare in children (5). A child with a midline dimple or pit is one of the most common referrals to a pediatric neurosurgeon (10). Recurrent meningitis and hydrocephalus are also frequent consequences of infected spinal dermoid cyst and subdural abscess (2, 5, 6). Here, we present a child admitted to our clinic with the diagnosis of meningitis and hydrocephalus. Further evaluation of this child disclosed an infected intramedullary dermoid tumor and subdural abscess.

CASE

A 4 year-old-boy presented to the Department of Pediatrics with the complaints of fever, headache and decreased consciousness. On the examination, he was found apathic; his co-

operation and orientation were decreased and he had meningeal irritation findings. Informed consent was obtained from his family after the nature of the procedure to be performed had been explained. Following an emergent cranial tomography (CT), demonstrating diffuse meningeal enhancement and ventricular dilatation, a ventricular puncture was performed. Evaluation of the cerebrospinal fluid (CSF) disclosed streptococcal meningitis. He had been treated with appropriate antibiotics. Then, a ventriculoperitoneal shunt system was inserted. He became conscious and cooperative. A control lumbar puncture at the end of the antibiotherapy revealed a purulent fluid and streptococci were cultured. Control cranial CT was normal and control ventricular puncture was clear. A spinal pathology was suspected and a spinal radiologic examination including X-ray, and spinal magnetic resonance imaging (MRI) was performed. On MRI, there was an enhanced

Date received/Dergiye geldiği tarih: 02.12.2005

* Van Military Hospital, Department of Radiodiagnosics, Van
(Correspondence to: atilla02002@yahoo.com)

** Pamukkale University, Department of Neurosurgery, Denizli

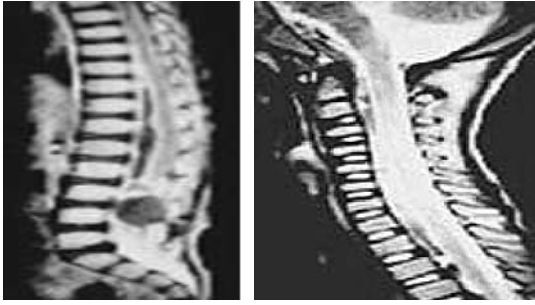


Figure 1. Sagittal a) enhanced T1 weighted thoracolumbar and b) T2 weighted cervical MRI sections demonstrating the intramedullary dermoid tumor (arrow) and subdural abscess all along the spinal cord.

lesion of the conus region and subdural abscess all along the spinal cord (Figure 1a, b). He was operated on through a dorsal midline approach and an intramedullary dermoid tumor including hairy contents was removed totally. A fistula tract ending at the subcutaneous level was noticed during the surgery. After all, he was treated with intravenous antibiotics for subdural abscess. He did well postoperatively. On his last control examination 6 months after the surgery, he was normal and the shunt was doing well.

DISCUSSION

Spinal intramedullary tumors may be congenital or acquired. Sometimes lumbar puncture for any reason may also cause spinal tumor (4, 8). They may present with neurological motor and sensorial deficits (1, 6). Some tumors such as embryonic tumors-dermoid cysts, craniopharyngiomas, teratomas and malignant gliomas may present with the episodes of chemical meningitis, single or multiple in patients with no neurological symptoms (2, 7, 8, 9). In these cases, differential diagnosis from aseptic meningitis, especially from Mollaret aseptic meningitis, is essential (8). A careful physical and neurological examination is important. Especially skin examination of the dorsal midline and inter gluteal regions for the dermal sinus tract is a must in meningitis and recurrent meningitis cases. A child with a midline dimple or pit is one of the most common referrals to a pediatric neurosurgeon. Regardless of their depth, those below the top of the intergluteal crease end blindly and never extend intraspinally. Families can be reassured that there is no infection or mechanical risk to the developing nervous system. A high index of suspicion must be maintained for all dimples above the intergluteal fold despite a normal examination or neuroradiologic studies. The midline must be carefully inspected when a child of any age suffers meningitis, especially when an unusual organism is cultured (3). Spinal congenital dermal sinus (CDS) is a rare entity which supposedly results from the failure of the neuroectoderm to separate from the cutaneous ectoderm during the process of neurulation. The lesions are most frequent at the lumbosacral followed by the occipital region. CDS of the thoracic region is very rare. The patients with spinal CDS present with meningitis and/or mass effect caused by the associated inclu-

sion tumor. They are usually dermoid or epidermoid cysts. Teratoma is rarely associated with this condition (4, 8). Conservative management of dermal sinuses is not justified, and these lesions should be electively resected at the time of diagnosis. Dermal sinuses and inclusion tumors may lead to spinal cord tethering and progressive neurologic deterioration. Surgery in advance of deficits maintains normal neurologic function, and children can develop unencumbered by infection, motor, or bladder paralysis. Radiologic diagnosis of the dermoid tumors is generally dependent on MRI. In the literature, most of the lesions were iso- to hyperintense to CSF on T2-weighted images. Some demonstrates a mixed intensity pattern on all sequences; dominant component gives short T1 and short T2 values, consistent with fat (3). Dermal sinus tract may not be observed in all cases. In our case, we thought that there had been a dermal sinus associated with the intramedullary dermoid tumors. Then, the sinus had been infected and caused self obliteration and development of subdural abscess all along the spinal cord. At the end, when meningitis has developed the child's family noticed the symptoms. Ventricular puncture drained a very clear CSF, but lumbar puncture drained a viscous infected fluid at the end of the antibiotherapy for the meningitis.

CONCLUSION

This case indicates that meningitis can develop secondary to a congenital dermal sinus and dermoid tumors. So every child with central nervous system infection should be evaluated for dorsal midline defects. In cases of dermal sinus presence, exclusion of the intramedullary tumor and spinal abscess is a must to prevent recurrent meningitis and neurologic deficits caused by spinal abscess and tumors. In dermal sinus cases, an enhanced MRI evaluation of the spinal cord will help us to detail the pathology and to help for surgical management.

REFERENCES

1. Akhaddar A, el Hassani MY, Ghadouane M, Hommadi A, Chakir N, Jiddane M, Boukhrissi N. Dermoid cyst of the conus medullaris revealed by chronic urinary retention. Contribution of imaging. *J Neuroradiol* 1999; 26:132-136.

2. Andiran N, Coskun T, Ozaydin E, Secmeer G. Recurrent meningitis associated with congenital paravertebral dermal sinus tract. *Turk J Pediatr* 1998; 40: 121-125.
 3. Barkovich AJ, Edwards M, Cogen PH. MR evaluation of spinal dermal sinus tracts in children. *AJNR Am J Neuroradiol* 1991; 12:123-129.
 4. Borrego O, Pomerance HH, Vega M. Pathological case of the month. Intrapinal dermoid cyst. *Arch Pediatr Adolesc Med* 1995; 149: 701-702.
 5. Chen CY, Lin KL, Wang HS, Lui TN. Dermoid cyst with dermal sinus tract complicated with spinal subdural abscess. *Pediatr Neurol* 1999; 20: 157-160.
 6. Cokca F, Meco O, Arasil E, Unlu A. An intramedullary dermoid cyst abscess due to *Brucella abortus* biotype 3 at T11-L2 spinal levels. *Infection* 1994; 22: 359-360.
 7. Kriss TC, Kriss VM, Warf BC. Recurrent meningitis: the search for the dermoid or epidermoid tumor. *Pediatr Infect Dis J* 1995; 14: 697-700.
 8. Lunardi P, Missori P. Cranial and spinal tumors with meningitic onset. *Ital J Neurol Sci* 1990; 11: 145-151.
 9. Maroun FB, Jacob JC, Heneghan WD, Cooper AR, Kennedy RF, Lewis K. Recurrent meningitis in a child. *Indian J Pediatr* 1984; 51: 355-357.
 10. Wang KC, Yang HJ, Oh CW, Kim HJ, Cho BK. Spinal congenital dermal sinus—experience of 5 cases over a period of 10 years. *J Korean Med Sci* 1993; 8: 341-347.
-