




# Aydın Dental Journal

Journal homepage: <http://dergipark.ulakbim.gov.tr/adj>



## ENDODONTIC TREATMENT IN MANDIBULAR FIRST MOLAR WITH SIX CANALS: A CASE REPORT

DergiPark  
AKADEMİK

Saad Shahnawaz AHMED<sup>1</sup>, Mohsin QADEER<sup>2</sup>, Alia AHMED<sup>3</sup>

### ABSTRACT

Root canal anatomy can show great variation in molar teeth. The lower mandibular six also shows complex morphology (typically it has 2 canals in mesial root and 1 canal in distal). This case report attempts to document the non-surgical endodontic treatment of a molar tooth with three canals in the mesial root and three in the distal root. Having more than 3 canals is unusual. Prognosis of endodontic treatment is poor if the clinician fails to locate all the present canals in a tooth. Non-surgical

endodontic treatment was done and later restored by core build up followed by crown placement. It is to be greatly emphasized that the prognosis of a root canal treatment in a case with anatomic variation can be adverse if the clinician is unable to detect the presence of extra root canals.

**Keywords:** *Morphology, prognosis, core buildup, non-surgical endodontic treatment, composite restoration.*

<sup>1</sup> Post graduate resident of Operative Dentistry,

<sup>2</sup> House Officer of Operative Dentistry Department.

<sup>3</sup> HOD of Operative Department, Islamic International Hospital Islamabad.

Corresponding Author: e-mail: [saadahmed552@hotmail.com](mailto:saadahmed552@hotmail.com)

## ALTI ADET KÖK KANALLI BULUNAN MANDİBULAR BİRİNCİ MOLARIN ENDODONTİK TEDAVİSİ: BİR VAKA RAPORU

### ÖZ

Kök kanal anatomisi azı dişlerinde büyük farklılıklar gösterebilir. Özellikle alt mandibular birinci molar diş karmaşık morfolojileri ile öne çıkmaktadır. (Tipik olarak mesial kökte 2, distalde 1 kanal vardır). Bu olgu sunumu bir alt birinci molar dişin cerrahi olmayan endodontik tedavisinde, mesial kökte üç kanal ve distal kökte üç kanal varlığının tespitini belgelendirmeyi amaçlamaktadır. Alt molar dişlerde üçten fazla kanal olması bile alışılmadık bir durumdur. Endodontik tedavinin prognozu, eğer klinisyen mevcut tüm kanalları tespit edip gerekli şekillendirme ve dolum

işlemlerini yapamazsa kötüdür. Bu vakada cerrahi olmayan endodontik tedavi yapıldı ve daha sonra post-kor uygulaması ve ardından kronlama işlemi ile restore edildi. Bu vaka raporunda, anatomik değişkenlik gösteren bir olguda kök kanal tedavisinin prognozunun, eğer klinisyen ekstra kök kanallarının varlığını tespit edemediğinde olumsuz olabileceği vurgulanmalıdır.

*Anahtar Kelimeler:* Dental morfoloji, Prognoz, Dental post-core, Cerrahi olmayan endodontik tedavi, kompozit restorasyon.

### INTRODUCTION

Endodontic treatment aims at cleaning and disinfecting the root canal system along with sealing it to eliminate or decrease the load of microorganisms from within the canals. To achieve this goal in teeth with unusual canal anatomy, the clinician should be acquainted with the knowledge of morphology, skill and magnifying armamentarium so that precise number and location of canals can be determined.<sup>1</sup> Adequate de-roofing of the pulp chamber, providing proper access and visualization of the root canal orifices is the key, enabling the clinician in identifying any distinction in the number and positioning of the root canals.<sup>2</sup>

Mandibular molars can be found having variety of root morphologies which may include single root to multiple roots, taurodontism, radix entamolaris, radix paramolaris, variant canal morphologies which include middle mesial, middle distal and C-shaped. However, a mesial root having four canals is a very rare discovery.<sup>3</sup> The factors deciding on intrinsic multiplicity of the root canals can either be inherited or arise as a result of the ageing processes of secondary

dentin deposition forming segregations and elaborate differentiations of the canals leading to unique canal morphology.<sup>4</sup>

An unusual canal anatomy should be suspected and investigated further when a pre-treatment radiograph is suggestive of an unconventional tooth shape and contour. The matter should further be probed by taking additional radiographs at differing angles or cone-beam computed tomograph as confirmatory tests.<sup>5</sup>

The focus of this clinical case report is on a mandibular right first molar with two roots and six root canals revealed during a routine endodontic procedure.

### CASE PRESENTATION

A 45-year old male patient was referred to operative department for root canal treatment of his right mandibular 1<sup>st</sup> molar with non-contributory medical history and pain on mastication. A clinical diagnosis of pulp necrosis was made. The tooth had no response to palpation and the tooth mobility was found to be within physiological limits, however

there was tenderness observed to percussion. The associated soft tissue appeared clinically normal. A negative thermal pulp test confirmed the clinical diagnosis.

Pre-operative radiograph evaluation showed the tooth having usual root canal anatomy and a lesion present peri-apically. To initiate a pain-free procedure, a standard inferior alveolar nerve block with 1.8ml of 2% lidocaine and 1:100,000 epinephrine (Medicaine, Korea) was injected. Single tooth isolation was done with rubber dam to achieve proper isolation and prevent salivary contamination. Standard coronal access opening was performed with a fast hand piece round bur (Mani, Japan) under irrigation. On access to pulp chamber, the pulp floor revealed unusual morphology. Careful canal scouting with DG-16 probe under 6x magnifying loupes disclosed six orifices. Further cleaning and assessment unveiled the presence of MM (middle mesial) and MD (middle distal) canals situated between the 2 mesial (MB and ML) and 2 distal (DB and DL) root canals respectively. Using a 10-K (Mani, Japan) file for negotiating the canals, working length was determined by apex locator (J. MORITA, Japan) and verified radiographically. Independent apical foramens were identified with vertucci classification type VIII in mesial and distal roots respectively [fig.1]. Canal preparation and glide path was achieved using a 20-K file (Mani, Japan). Irrigation was performed with 2.5% sodium hypochlorite solution (NaOCl) and 17% EDTA (Metabiomed, Korea). Using Hyflex CM (Coltene) files canal cleaning and shaping was performed with pecking motion under continuous file rotation. After three rounds, the instrument was retracted from the canal and cleaned.

To check canal patency, a 15-K file was taken to the working length for recapitulation followed by proper irrigation between each rotary file. The procedure was repeated for all canals until patency till the working length was achieved [fig1]. Subsequently, canal rinsing was performed using 5ml of 17% EDTA followed by 10ml of 2.5% sodium hypochlorite solution during the canal instrumentation. [fig. 2]

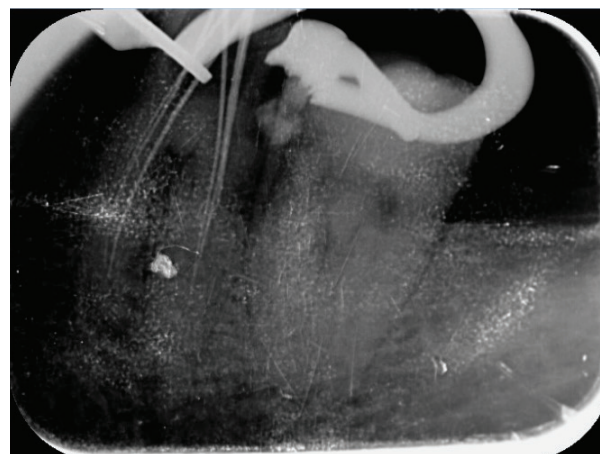


Figure 1: Working length determination after cavity access preparation

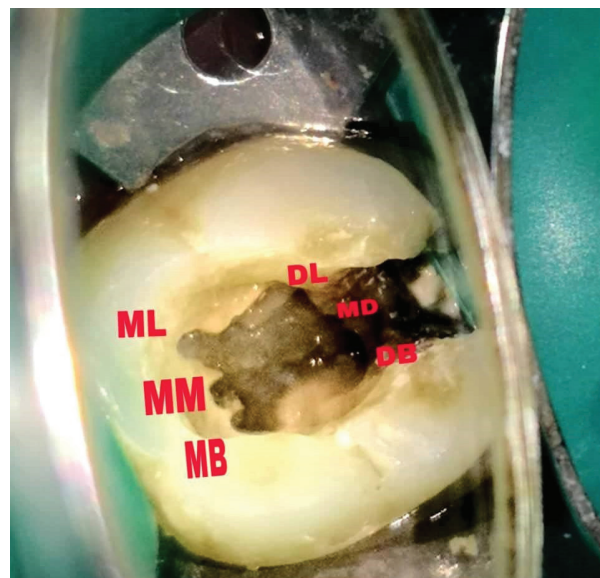


Figure 2: Pulp chamber with six canals (ML,MM,MB,DL,MD and DB) after canal preparation

The patient was recalled after 5 days and reported to be asymptomatic. The tooth obturation was done after 5 days from the initial visit by using single cone cold lateral condensation technique using Gutta Percha points with Adseal sealer (Metabiomed,korea). [fig. 3]

Core buildup was done with composite (coltene) over the endodontically treated tooth. [fig. 4] [fig. 5]

On completion of three weeks after obturation a crown was placed over the treated tooth and a post op radiograph was taken. [fig.6] A six-month follow-up was conducted. The tooth was found to be clinically sound and asymptomatic with a significant reduction in the periapical lesion.

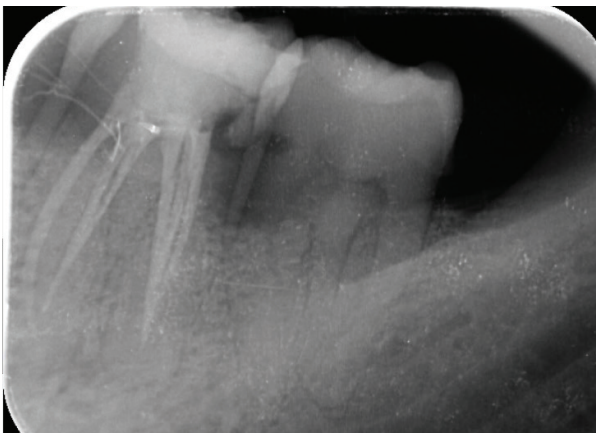


Figure 3: Periapical radiograph taken 1 week post obturation by the bisecting angle technique.

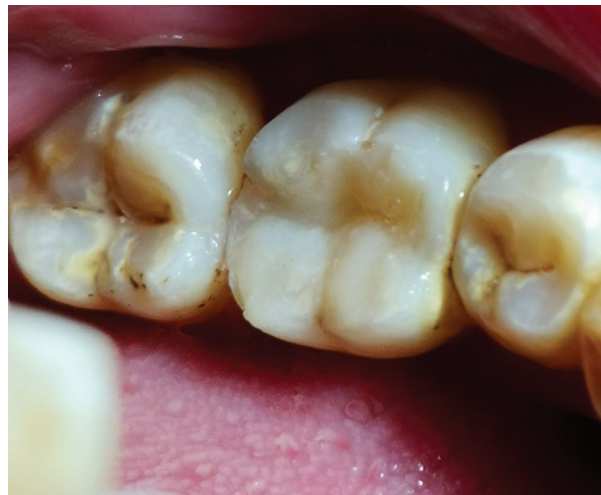

Figure 4: Occlusal view of Composite core build/up on tooth number 46

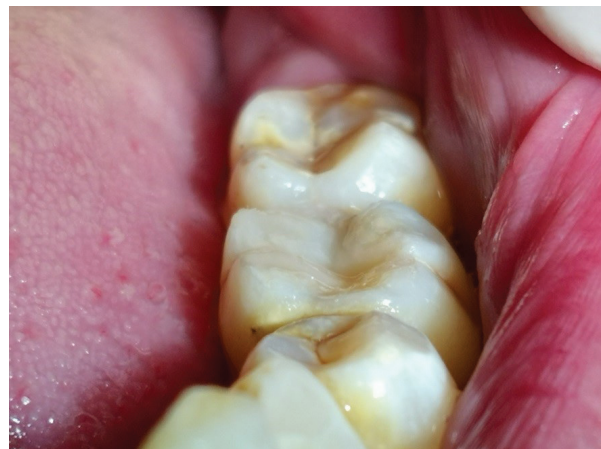

Figure 5: Anterior occlusal view of composite core build up performed 5 days after obturation.

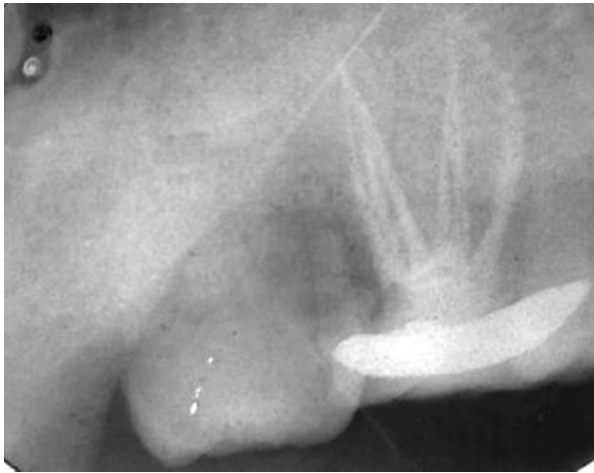


Figure 6: 3 week follow up after restoration with a porcelain fused to metal (PFM) crown. All six canals obturated are visible and apical bone health is optimal with a periapical index score of 0

## DISCUSSION

A root canal treatment is intended to carry out an exhaustive mechanical and chemical decontamination of the tooth canals and obturation with an inert material. All canals should be perfectly filled and sealed because otherwise they can serve as pathways for leakage or reinfection. Inadequately sealed root canals form the most common reason of endodontic failures. To avoid these kinds of failures, a thorough knowledge and understanding of the normal anatomy of root canals as well as the possible anatomic variations is imperative.<sup>6</sup>

According to research the percentage of two canals in mesial and single canal in distal root is found to be 65% whereas presence of two canals in both is 30%. The incidence of middle mesial canal is reported to be 1-15% and middle distal canal 0.2-3% in mandibular first molars.<sup>7,8</sup>

Various studies including those conducted by Vande Voorde et al.<sup>9</sup> Martinez-Berna and Badanelli<sup>10</sup> and Fabra-Campos<sup>11</sup> emphasize that it is essential to clinically evaluate the presence of a possible fourth or fifth root canal to ensure the success of endodontic treatment of a mandibular molar.

The incidence of mandibular first molars requiring endodontic treatment is higher compared to other teeth of the permanent dentition owing to two reasons; their early eruption in the oral cavity and lower success rate of treatment.<sup>12</sup> Endodontic procedures fail in this tooth mainly because of improper treatment, leaving microorganisms and pulp tissue remnants behind in the canals as well as due to complex root canal anatomy. Therefore, for a good prognosis, the clinicians need to have sound knowledge of the root canal anatomy of this tooth.<sup>13</sup>

Table 1: Literature review about previously reported treatments of molar teeth with six root canal

No	Author/date of publication	Tooth number	Number of canals	Vertucci classification	Method of obturation
1.	Ahmad H Jabali, February 2018	36	6	MB,MM and ML (type 8) DB,MD and DL (type 8)	Cold lateral condensation (single cone)
2.	Dilip Jain, 1 <sup>st</sup> September 2015	36	6	MB, ML-MB (type 2) Both distal canals (type 1)	Cold lateral condensation (single cone)
3.	<a href="#">Claudio Maniglia Ferreira</a> , 16 December 2014	36	6	All canals MB,MM, ML, DB,MD and DL (type 1)	continuous wave of condensation technique
4	Arturo Martinez-Berna, September 1983	16	6	All MB,MM,MP,DB,DP and Palatal (type 1)	Cold lateral condensation
5.	Mohammad Ahmad Alenezi, December 2015	46	6	MB,MM, ML (3–2 canal type) DB ,MD and DL (3–1 canal type)	Cold lateral condensation
6.	Sreenath N September 2018	36	6	(MB, MM, ML, DB, DM, DL)	Cold lateral condensation (single cone)

The present-day advances in endodontic practice like introduction of apex locators, operating microscopes, digital radiography and cone-beam computed tomography have greatly uplifted the standard of care. A study conducted by De Carvalho and Zuolo describes the utility of microscopes for detection of accurate location of root canal orifices which greatly improves the chances of success of treatment.<sup>14</sup> Despite not having used the operating microscopes and digital radiography in this particular clinical case, it was through thorough and accurate clinical inspection that the unusual anatomic feature of the tooth was identified.

A complex anatomy calls for more isthmi present between the canals, making their negotiation even more challenging. If this complicated anatomy is not accommodated for, it can adversely affect the outcomes of the treatment.<sup>15</sup>

### CONCLUSION

This case report describes a clinical experience with a mandibular first molar having six root canals. Albeit a rare finding, such variations may exist and the clinician should always be vigilant enough to identify their presence and treat them accordingly. In addition to this, the accessory canals in mandibular molars should be detected and treated so that proper irrigation

and filling of otherwise non-negotiable isthmi could be carried out. The prognosis of treatment is largely dependent upon accurate diagnosis and effective treatment.

### CONFLICT OF INTEREST

No prospective conflict of interest was disclosed.

### REFERENCES

1. Alenezi MA, Aldajani M, Al-Qathami HO, Al-Shommrani S. Endodontic management of a permanent mandibular first molar with unusual root canal configurations: Two case reports. *Saudi Endod J* 2017; 7: 181-185
2. Nagmode PS, Patel AV, Satpute AB, Gupta PL. Endodontic management of mandibular first molars with mid mesial canal: A case series. *J Conserv Dent* 2017; 20: 137-140.
3. Jain D, Reddy S, Venigalla BS, WKamishetty S. Endodontic management of a mandibular first molar with six root canal systems. *J Conserv Dent* 2015; 18: 419-422.
4. Claudio Maniglia-Ferreira, Fabio de Almeida Gomes, and Bruno Carvalho Sousa, "Management of Six Root Canals in Mandibular First Molar," *Case Reports in Medicine*, 2015
5. Patel S, Horner K. The use of cone beam computed tomography in endodontics. *Int Endod J*, 2009; 42: 755-756.
6. Vertucci, F. Root canal morphology and its relationship to endodontic procedures. *Endodontic Topics*, 10(1): 3-29.
7. Reuben J, Velmurugan N, Kandaswamy D. The evaluation of root canal morphology of the mandibular first molar in an Indian population using spiral computed tomography scan: An in vitro study. *J Endod* 2008; 34: 212-215.
8. Sert S, Bayirli GS. Evaluation of the root canal configurations of the mandibular and maxillary permanent teeth by gender in the Turkish population. *J Endod* 2004; 30: 391-398.
9. Vande Voorde HE, Odendahl D, Davis J. Molar 4<sup>th</sup> canals: Frequent cause of endodontic failure? *Ill Dent J* 1975; 44: 779-786.
10. Badanelli P, Martinez-Bern A. Obturation of a lower molar with five canals. In: Lasala A, editor. *Endodoncia*. Barcelona: Salvat S.A.; 1979. p. 407.
11. Fabra-Campos H. Unusual root anatomy of mandibular first molars. *J Endod*, 1985; 11: 568-572.
12. Zaatari EI, Al-Kandari AM, Alhomaidah S, Yasin IMA. Frequency of endodontic treatment in Kuwait: Radiographic evaluation of 846 endodontically treated teeth. *Journal of Endodontics*. 1997; 23(7): 453-456.
13. Chen G, Yao H, Tong C. Investigation of the root canal configuration of mandibular first molars in a Taiwan Chinese population. *International Endodontic Journal*. 2009; 42(11): 1044-1049.
14. de Carvalho MC, Zuolo ML. Orifice locating with a microscope. *J Endod*, 2000; 26: 532-534.
15. Mannocci F, Peru M, Sherriff M, Cook R, Ford TRP. The isthmuses of the mesial root of mandibular molars: a micro-computed tomographic study. *International Endodontic Journal*. 2005; 38(8): 558-563.