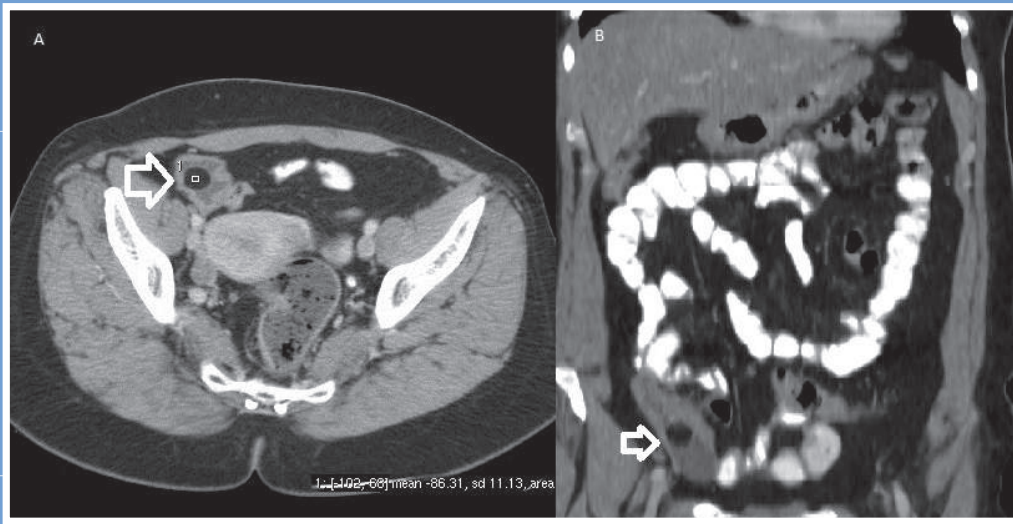


THE TURKISH JOURNAL OF ACADEMIC GASTROENTEROLOGY

AKADEMİK GASTROENTEROLOJİ DERGİSİ



Axial (a) and coronal (b) reformatted MDCT images of a cecal lipoma (arrows).

ISSN 1303-6629

Nisan/April 2018
Cilt/Volume 17
Sayı/Number 1

