



Laryngeal inflammatory myofibroblastic tumor mimicking advanced stage malignancy

Ayşegül Gönen¹, Necati Enver², İrem Sahver İşgör³, Leyla Cinel³, Çağatay Oysu²

¹Department of Otorhinolaryngology Head and Neck Surgery, Kırklareli State Hospital, Kırklareli, Turkey

²Department of Otorhinolaryngology Head and Neck Surgery, Marmara University Medical Faculty Research and Training Hospital, Istanbul Turkey

³Department of Pathology, Marmara University Medical Faculty Research and Training Hospital, Istanbul Turkey

ABSTRACT

Inflammatory myofibroblastic tumors (IMTs), also known as inflammatory pseudotumors, plasma cell granulomas or inflammatory fibrosarcomas, are neoplastic lesions which primarily occur in children and are most frequently described in the lungs. They rarely affect the head and neck region. A 63-year-old female patient presented with an extremely large tumor which obstructed the airway. Total laryngectomy was performed. The diagnosis was atypical spindle cell proliferation and inflammatory cells without necrosis and an increased mitotic activity compatible with an IMT. The definitive diagnosis was achieved with positive cytoplasmic anaplastic lymphoma kinase-1 (ALK)-1 immunoreactivity. In conclusion, it is critical to evaluate patients carefully to distinguish IMT from mimicking diseases through endoscopic, radiological, histopathological, and immunohistochemical assessment to make tailor the treatment plan.

Keywords: Immunohistochemistry, inflammatory myofibroblastic tumor, larynx.

Inflammatory myofibroblastic tumors (IMT), also known as inflammatory pseudotumors, plasma cell granulomas or inflammatory fibrosarcoma, are neoplastic lesions which primarily occur in children and are most frequently described in the lungs.^[1] These tumors tend to be locally aggressive, benign, may grow slowly or rapidly, and usually manifest with progressive symptoms referable to the mass effect.^[2] Inflammatory myofibroblastic tumors mainly affect the lungs, mesentery and omentum, and rarely the head and neck region. To date, less than 50 cases of IMT of the larynx have been reported in the English literature.^[3] In this

article, we report a case of IMT in the larynx of a 63-year-old female.

CASE REPORTS

A 63-year-old female patient presented with a six-year history of hoarseness and two-year history of dysphagia. She underwent tracheotomy due to respiratory distress five months ago. She had diabetes mellitus and hypertension, which were controlled by medical therapy. She was a non-smoker and did not drink alcohol. Her surgical history revealed microlaryngoscopy and biopsy of a glottic mass at an external center five month ago. Histopathology revealed no exact diagnosis,

Received: April 26, 2020 Accepted: July 09, 2020 Published online: September 21, 2020

Correspondence: Ayşegül Gönen, MD. Kırklareli Devlet Hastanesi Kulak Burun Boğaz Kliniği, 39000 Kırklareli, Türkiye.

e-mail: aysegul068@hotmail.com

Doi: <http://dx.doi.org/10.5606/Tr-ENT.2020.51422>

Citation:

Gönen A, Enver N, Sahver İşgör İ, Cinel L, Oysu Ç. Laryngeal inflammatory myofibroblastic tumor mimicking advanced stage malignancy. Tr-ENT 2020;30(2):66-70.

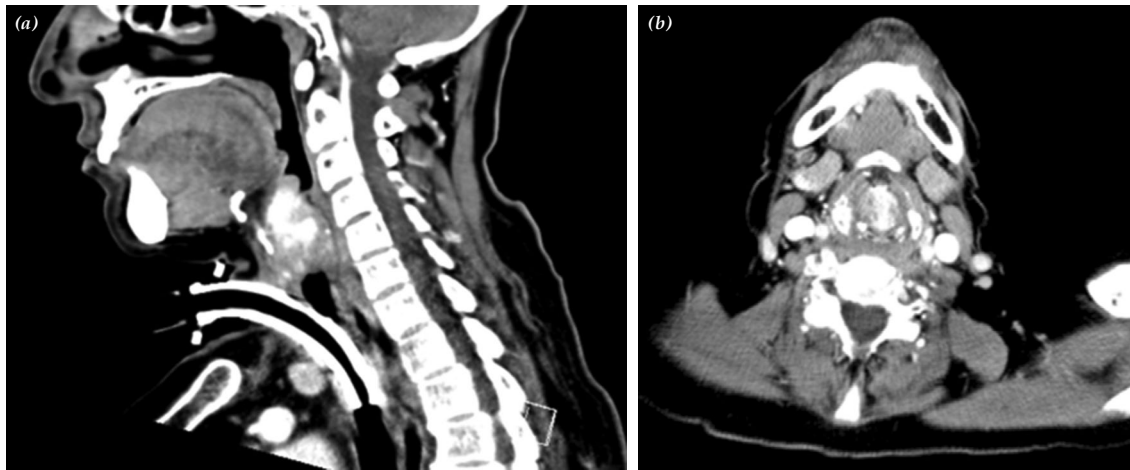


Figure 1. Radiological appearance of tumor, hyperdense tumoral lesion obstructing airway completely. (a) Lateral view, (b) anterior view.

and IMT or a spindle cell carcinoma were among the possible diagnoses. She was accepted as having a spindle cell carcinoma, despite the inexplicit diagnosis and received three cycles of a docetaxel-cisplatin-5-fluorouracil chemotherapy protocol. After completion of chemotherapy, the patient underwent positron emission tomography (PET) and computed tomography (CT) for the evaluation of the

treatment response and staging. The PET-CT showed a large mass with soft tissue density, 29×28×43 mm in size, originating from the supraglottic portion of the larynx, extending to the anterior commissure, and completely obstructing the airway. The origin of the mass could not be exactly identified during the

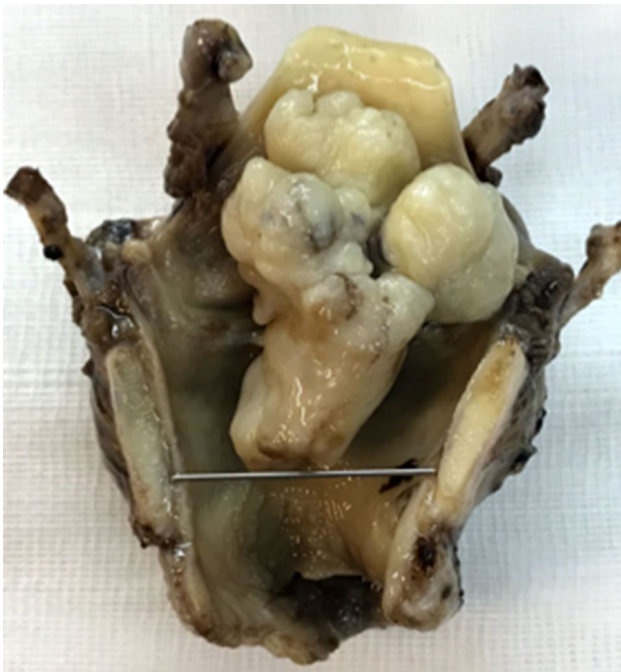

Figure 2. A macroscopic view of specimen.

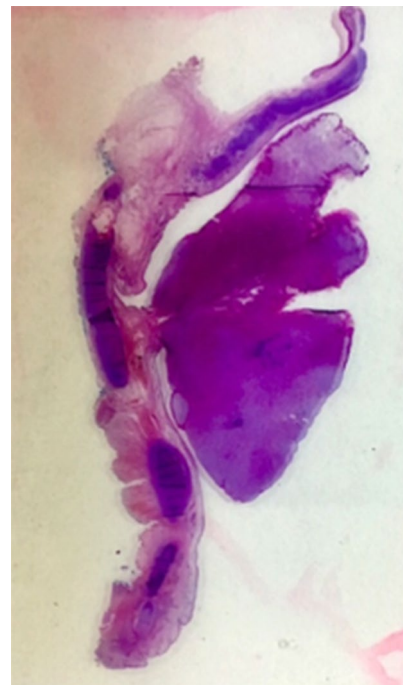


Figure 3. An exophytic polypoid tumor attached to vocal fold with a stalk (mega cassette slide, H-E).

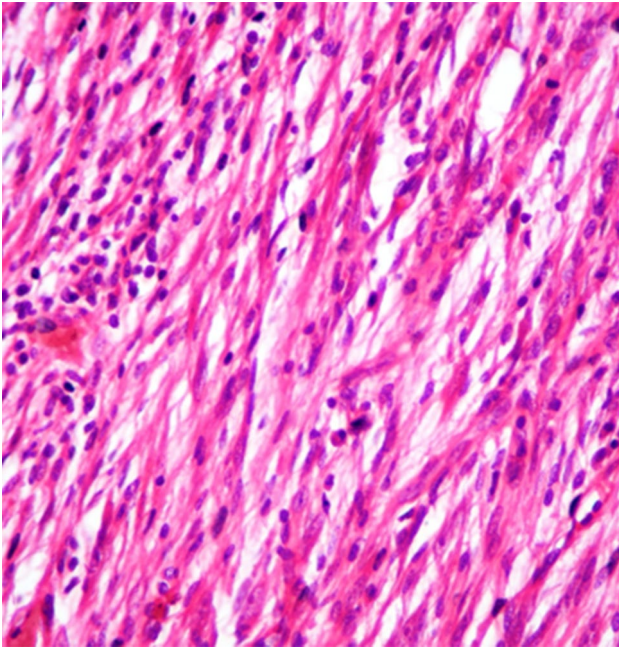


Figure 4. Atypical spindle cell proliferation intermixed with inflammatory cells (H-E, ×400).

preoperative radiological evaluation, and it was completely filling the glottis and supraglottic level (Figures 1a, b). The fluorodeoxyglucose-18 (FDG-18) uptake of the mass was very high (SUV_{max} : 22.3). Despite treatment, progression of the disease occurred, and she was referred to Marmara University Medical Faculty Hospital.

Indirect laryngoscopy showed an exophytic supraglottic mass, completely obstructing the airway. The vocal folds could not be evaluated. Based on the tumor size, endoscopic view of the larynx, radiological reports, preoperative histopathological diagnosis, and unresponsiveness to medical treatment, a high-grade tumor was considered and total laryngectomy was decided as the definitive therapy. A written informed consent was obtained from the patient. Gross examination revealed an exophytic polypoid transglottic tumor, 48×37×23 mm in size, attached to the anterior commissure and right vocal fold with a thin stalk (Figures 2 and 3).

On microscopic examination, atypical spindle cell proliferation and inflammatory cells without necrosis and an increased mitotic activity were seen (Figure 4). In addition, the

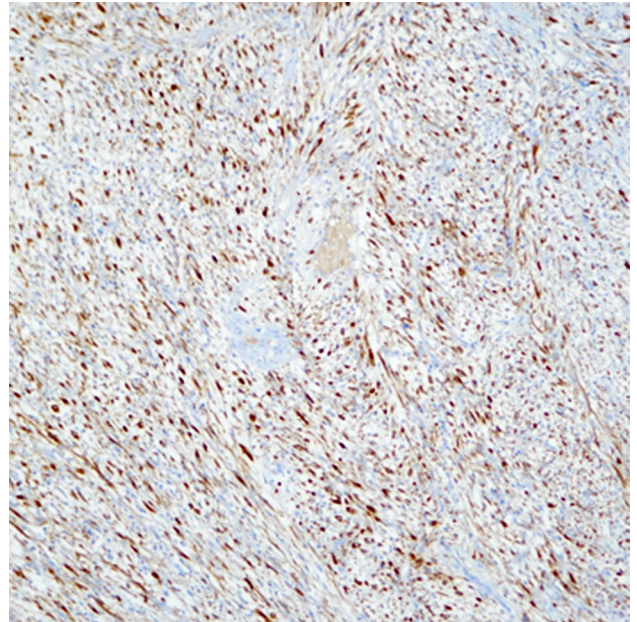


Figure 5. ALK-1-positive immunoreexpression (histochemical staining ×100).
ALK: Anaplastic lymphoma kinase.

spindle cells showed cytoplasmic anaplastic lymphoma kinase-1 (ALK)-1 immunoreactivity (Figure 5). These findings supported previous histopathological reports and the definitive diagnosis of IMT was obtained. Currently, the patient has been stable for six months with no evidence of disease recurrence.

DISCUSSION

The World Health Organization (WHO) classification currently defines IMT as an intermediate soft-tissue tumor comprising spindle cells which exhibit myofibroblast differentiation and numerous inflammatory cells, plasma cells, and/or lymphocytes.^[4] These tumors mostly affect the larynx.^[3] An IMT behaves as a benign, locally aggressive lesion, clinically and radiologically mimicking a neoplastic process.^[5] The etiology of IMT still remains unclear. With the discovery of cytogenetic aberrations and subsequent recognition of ALK gene rearrangements, the hypothesis of an inflammatory origin has been refuted by some researchers.^[6] Possible factors predisposing to IMT are trauma, foreign bodies, Epstein-Barr virus (EBV), human herpes virus-8 (HHV-8), surgery, and smoking.^[7,8] It must be kept in mind that, in the absence of these factors,

the diagnosis of IMT cannot be eliminated. Indeed, our patient had none of these disease-promoting factors.

Patients with an IMT usually present with non-specific symptoms and a mass, similar to that for malignant tumors. The mass, then, grows and oppresses the surrounding tissues, increasing the likelihood of local corresponding symptoms accompanied by pain, fever, and weight loss.^[8] Anemia and an accelerated erythrocyte sedimentation rate may be also present in laboratory examinations.^[8] In our case, there was hoarseness, dysphagia, and difficulty of breathing depending on the mass effect of the progressively growing lesion, mimicking malignancy of the larynx.

It is difficult to make a definitive diagnosis without a histological examination. A histopathological differential diagnosis of IMT is crucial for prognosis and to tailor the treatment strategy; however, diagnosis is also challenging due to the complex histopathological patterns. Based on the histopathological pattern, there is a long list of differential diagnoses mimicking these findings including an inflamed/infected leiomyosarcoma, nodular fasciitis, immunoglobulin (Ig) G4-related disease, fibromatosis, myofibroblastoma, fibrous histiocytoma, inflammatory malignant fibrous histiocytoma, sarcomatoid carcinoma, and benign and malignant smooth muscle tumor. The ALK, which is used in the diagnosis of anaplastic large cell lymphomas, is expressed in 50% of IMTs caused by chromosomal translocation of the ALK gene with a partner gene (nucleophosmin or others), which is useful in confirming the diagnosis.^[9] An IMT must be differentiated from a spindle cell squamous carcinoma. The absence of atypical mitosis despite the presence of mitotic figures and no cytokeratin expression are the key features of IMT which distinguish it from a spindle cell squamous carcinoma.^[10]

In the literature, organ-preserving treatment modalities are the most prioritized approaches. The therapeutic approach varies from medical treatment with steroids, chemotherapy or radiotherapy to surgical treatment with local excision using laser or cold dissection.^[7] The most optimal therapy for laryngeal IMTs is

complete removal of the tumor with clear margins, with supplementation by carbon dioxide (CO₂) laser light with or without steroid therapy.^[11] In patients with recurrence, conservative laryngeal surgery can be chosen; chemo-radiotherapy is suitable for only a few patients, if malignant transformation occurs.^[11] In the present case, the patient received three cycles of a docetaxel-cisplatin-5-fluorouracil chemotherapy regimen; however, the tumor continued to grow progressively. This indicates the probable superiority of surgical treatment over chemotherapy.

In the case presented above, the non-distinguishing histopathological diagnosis of a spindle cell carcinoma in direct laryngoscopy preparations may have been the cause of overtreatment. Furthermore, the lack of a radiological evaluation of the origin of the mass, which was attached to the vocal fold by a thin stalk, may be another factor. In the literature, endoscopic examinations of cases presented previously showed that the masses were limited in size; none of them exceeded the tumor size of our case. Although the excessive size and endoscopic view of the tumor could bring malignancy to mind, it suggests that IMTs can reach a large size, even larger enough to obstruct the airway. Total laryngectomy should be the last choice of treatment due to its association with morbidity and impaired quality of life. It can be selected only for highly recurrent cases, despite repeated excisions.

The recurrence rate of laryngeal IMTs is about 8 to 18% and recurrence occurs from two months to 12 months.^[2] Alhumaid et al.^[2] reported a literature review of 31 cases of IMT. Recurrence appeared in nine cases and they concluded that the factors which may have led to recurrence included partial or incomplete excision and steroid therapy alone. The patient presented herein has been stable for six months with no evidence of disease recurrence.

In conclusion, IMTs are rarely seen in the larynx. However, they should be considered in the differential diagnosis of lesions involving the larynx. In general, the disease process shows a benign course and usually manifests with progressive symptoms attributable to the

mass effect. It is critical to evaluate patients carefully to distinguish IMTs from mimicking diseases through endoscopic, radiological, histopathological, and immunohistochemical evaluation to tailor the treatment more appropriately. The primary treatment is complete surgical removal of the tumor to prevent recurrence.

Declaration of conflicting interests

The authors declared no conflicts of interest with respect to the authorship and/or publication of this article.

Funding

The authors received no financial support for the research and/or authorship of this article.

REFERENCES

1. Karnak I, Senocak ME, Ciftci AO, Çağlar M, Bingöl-Koloğlu M, Tanyel FC, et al. Inflammatory myofibroblastic tumor in children: diagnosis and treatment. *J Pediatr Surg* 2001;36:908-12.
2. Alhumaid H, Bukhari M, Rikabi A, Farahat M, Mesallam TA, Malki KH, et al. Laryngeal myofibroblastic tumor: case series and literature review. *Int J Health Sci (Qassim)* 2011;5:187-95.
3. Do BA, Varshney R, Zawawi F, Levental M, Caglar D, Young J. Inflammatory myofibroblastic tumor of the larynx-a case report. *J Voice* 2014;28:258-61.
4. Coffin CM, Fletcher JA. Inflammatory myofibroblastic tumour. In: Fletcher CDM, Bridge JA, Hogendoorn PCW, Mertens F, editors. *World Health Organization classification of tumours. WHO classification of soft tissue and bone*. 4th ed. Lyon: IARC Press; 2013. p. 83-4.
5. Segawa Y, Yasumatsu R, Shiratsuchi H, Tamae A, Noda T, Yamamoto H, et al. Inflammatory pseudotumor in head and neck. *Auris Nasus Larynx* 2014;41:321-4.
6. Coffin CM, Watterson J, Priest JR, Dehner LP. Extrapulmonary inflammatory myofibroblastic tumor (inflammatory pseudotumor). A clinicopathologic and immunohistochemical study of 84 cases. *Am J Surg Pathol* 1995;19:859-72.
7. Biron VL, Waghray R, Medlicott SA, Bosch JD. Inflammatory pseudotumours of the larynx: three cases and a review of the literature. *J Otolaryngol Head Neck Surg* 2008;37:E32-8.
8. Tao J, Zhou ML, Zhou SH. Inflammatory myofibroblastic tumors of the head and neck. *Int J Clin Exp Med* 2015;8:1604-10.
9. Jacob SV, Reith JD, Kojima AY, Williams WD, Liu C, Vila Duckworth L. An Unusual Case of Systemic Inflammatory Myofibroblastic Tumor with Successful Treatment with ALK-Inhibitor. *Case Rep Pathol* 2014;2014:470340.
10. Corsi A, Ciofalo A, Leonardi M, Zambetti G, Bosman C. Recurrent inflammatory myofibroblastic tumor of the glottis mimicking malignancy. *Am J Otolaryngol* 1997;18:121-6.
11. Suh SI, Seol HY, Lee JH, Lee YH, Kim TK, Lee NJ, et al. Inflammatory myofibroblastic tumor of the larynx. *Head Neck* 2006;28:369-72.