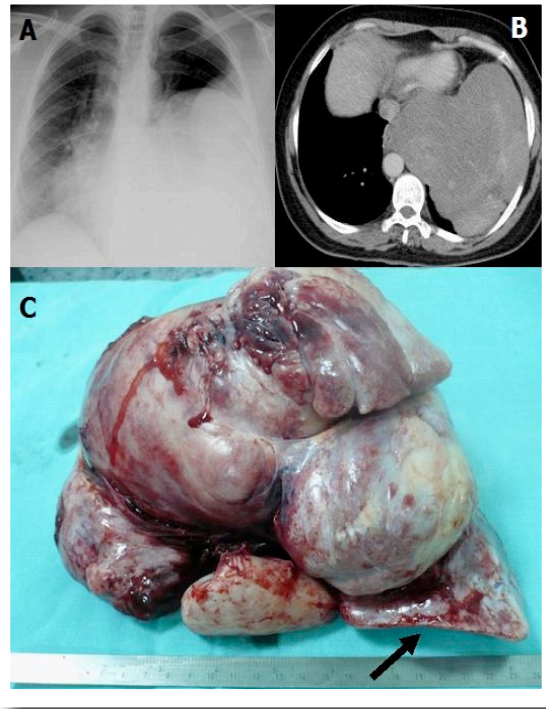


# CURRENT THORACIC SURGERY



When you cite this journal, use the following abbreviation  
Curr Thorac Surg

## **Aims and Scope**

The Current Thoracic Surgery is a current periodical, peer-reviewed and open access e-journal. It is the official e-journal of the Turkish Society of Thoracic Surgery and published three times annually.

The Current Thoracic Surgery publishes articles in branches of thoracic surgery, thoracic surgery anesthesia and thoracic disease (lung disease, cardiac disease, esophagus disease).

The Current Thoracic Surgery is dedicated to publishing clinical research, clinical analysis, laboratory and experimental studies, editorials, invited current reviews, case reports, interesting images and “How to Do It” papers. There is no fee involved throughout the publication process.

Being a peer-reviewed journal, the manuscripts sent will be evaluated by consultants and should be appropriate for the current version of common rules indicated for biomedical manuscripts as defined by the International Committee of Medical Journal Editors (ICMJE).

The journal accepts English language manuscripts. Articles will not be accepted for evaluation if they have been published or if they are considered for publication elsewhere and if they are not prepared according to the publication rules of the journal.

## **Official e-Publication of:**

Turkish Society of Thoracic Surgery (TSTS)

## **Conflict of Interest Statement**

Authors should declare that there is no conflict of interest and also, if there is any, the status for their financial support should be clear in the cover letter and article.

## **Disclaimer**

The Owner and Editors cannot be held responsible for errors or any consequences arising from the use of information contained in this journal; the views and opinions expressed do not necessarily reflect those of the Owner and Editors, neither does the publication of advertisements constitute any endorsement by the Owner and Editors of the products advertised.

For submission instructions, subscription and all other information, please visit [dergipark.gov.tr](http://dergipark.gov.tr)

© 2017 Current Thoracic Surgery



**TURKISH SOCIETY OF THORACIC SURGERY**  
***TÜRK GÖĞÜS CERRAHİSİ DERNEĞİ***

**President**

Levent Elbeyli, MD

**Secretary**

Berkant Özpolat, MD

**Treasurer**

Ertan Aydın, MD

**Members**

Korkut Bostancı, MD

Ali Kılıçgün, MD

Celalettin Kocatürk, MD

Hakan Kutlay, MD

Özgür Samancılar, MD

Salih Topçu, MD

**Past Presidents**

Şinasi Yavuzer (1998-2000)

İlker Ökten (2000-2002) (2002-2004) (2004-2006)

Şevket Kavukçu (2006-2009) (2009-2012)

Mustafa Yüksel (2012-2013)

---

**Owner**

Levent Elbeyli, MD, Gaziantep, Turkey  
On behalf of Turkish Society of Thoracic Surgery

**Editor-in-Chief**

Berkant Özpolat, MD, Kırıkkale, Turkey

**Editors**

Korkut Bostancı, MD, İstanbul, Turkey  
Ali Kılıçgün, MD, Bolu, Turkey  
Özgür Samancılar, MD, İzmir, Turkey

**Managing Editor**

Cabir Yüksel, MD, Ankara, Turkey

**Associate Editors**

Ertan Aydın, MD, Ankara, Turkey  
Mehmet Bilgin, MD, Kayseri, Turkey  
Reha Çelik, MD, Malatya, Turkey  
Sedat Demircan, MD, Ankara, Turkey  
Koray Dural, MD, Kırıkkale, Turkey

Atilla Eroğlu, MD, Erzurum, Turkey  
Celalettin Kocatürk, MD, İstanbul, Turkey  
Hakan Kutlay, MD, Ankara, Turkey  
Salih Topçu, MD, Kocaeli, Turkey  
Erdal Yekeler, MD, Ankara, Turkey

**International Editorial Board**

Michele Carbone, MD, Hawaii, USA  
John Dark, MD, Newcastle uponTyne, UK  
Jose Ribas Milanez De Campos, MD  
Peter Goldstraw, MD, London, UK  
Felix J. Herth, MD, Heidelberg, Germany  
Chien-Li Holmes-Liew, MD, Adelaide, Australia  
Walter Klepetko, MD, Vienna, Austria  
Antoon Lerut, MD, Leuven, Belgium  
Peter Bjorn Licht, MD, Odense, Denmark  
Marcello Martinez Ferro, MD, Buenos Aires, Argentina

Douglas Mathisen, MD, Boston, USA  
Harvey Pass, MD, New York, USA  
Hans K. Pilegaard, MD, Aarhus, Denmark  
Erino A. Rendina, MD, Rome, Italy  
Diego Gonzales Rivas, MD, Coruna, Spain  
Alan Sihoe, MD, Shenzhen, China  
Lorenzo Spaggiari, MD, Milano, Italy  
Gonzalo Varela, MD, Salamanca, Spain  
Jean-Marie Wilhm, MD, Strasbourg, France

## Table of Contents

Volume 2

Number 1

April 2017

e-ISSN 2548-0316

### Original Articles

- 1 Laparoscopic Heller myotomy is equally efficient and safe in patients who had pre-myotomy endoscopic interventions when compared with those with no interventions**  
Zeynep Bilgi, Adamu Issaka, Hasan Fevzi Batirel
- 5 Upregulated mRNA expression of mTOR in surgically resected early stage non-small cell lung carcinoma: a potential molecular targeted therapy**  
Muhammet Sayan, Ali Çelik, Şevki Mustafa Demiröz, Hacer İlke Önen, Nalan Akyürek, Ece Konaç, İsmail Cüneyt Kurul, Abdullah İrfan Taştepe
- 11 Diagnosis and treatment approaches of the lung hydatid cysts in childhood**  
Özgür Katrancıoğlu, Ekber Şahin, Şule Karadayı, Melih Kaptanoğlu
- 15 Solitary fibrous tumours, should they always considered to be benign gigantic masses?**  
Soner Gürsoy, Banu Yoldaş, Ahmet Üçvet, Ozan Usluer, Serkan Yazgan, Zekiye Aydoğdu Dinç

### Case Reports

- 20 Video-assisted thoracoscopic removal of esophageal leiomyoma in a patient with aberrant right subclavian artery**  
Zeynep Bilgi, Okan Dericioğlu, Hakan Ömercikoğlu, Çağatay Çetinkaya, Hasan Fevzi Batirel
- 23 Isolated giant chest wall metastasis of papillary thyroid carcinoma; case report**  
Kemal Karapınar, Celalettin İbrahim Kocatürk, Ali Cevat Kutluk, Nural Ören
- 27 A giant mediastinal ectopic goiter causing dyspnea and dysphagia**  
Ali Cevat Kutluk, Yunus Seyrek, Celalettin İbrahim Kocatürk, Mehmet Ali Bedirhan

### Reviews

- 30 Endobronchial Coils – therapeutic innovations for severe emphysema**  
Martin Hetzel
- 36 Endoscopic lung volume reduction in chronic obstructive airway disease using one-way valves.**  
Konstantina Kontogianni, Ralf Eberhardt

To cite this article: Bilgi Z, Issaka A, Batirel HF. Laparoscopic Heller myotomy is equally efficient and safe in patients who had pre-myotomy endoscopic interventions when compared with those with no interventions. *Curr Thorac Surg* 2017; 2(1): 1-4.

## Original Article

# Laparoscopic Heller myotomy is equally efficient and safe in patients who had pre-myotomy endoscopic interventions when compared with those with no interventions

Zeynep Bilgi<sup>1a</sup>, Adamu Issaka<sup>2</sup>, Hasan Fevzi Batirel<sup>3</sup>

<sup>1</sup>Department of Thoracic Surgery, Kars Harakani State Hospital, Kars, Turkey

<sup>2</sup>Department of Thoracic Surgery, Tamale Teaching Hospital, Tamale, Ghana

<sup>3</sup>Department of Thoracic Surgery, Faculty of Medicine, Marmara University, Istanbul, Turkey

### ABSTRACT

**Background:** Endoscopic treatment (ET) methods for achalasia such as balloon dilatation and botulinum toxin injection has good success for short and medium term management of achalasia. However some patients either need repeat attempts or referred to surgery. In this study we analyzed and compared the perioperative and disease specific quality of life outcomes of achalasia patients who either underwent surgery as a first line treatment and the ones who underwent ET method prior to surgery.

**Materials and Methods:** The patients who underwent standard of care diagnostic workup and surgery for achalasia by the same surgical team between 2007 and 2014 were recorded in a prospective database. The patients who underwent surgery as a first line treatment (Group 1, n = 55) and the patients who underwent prior ET (Group 2, n = 33) were identified. Demographic data, perioperative complications, length of hospital stay, pre- and postoperative Eckardt scores were recorded and analyzed.

**Results:** A total of 88 patients out of 105 were available for follow up with average follow up time of  $61.9 \pm 35.8$  months. The mean age was  $43.3 \pm 15.6$ . Mean hospital stay was  $2.3 \pm 0.8$  days and there was no mortality. Average duration of the effectivity of ET before myotomy was  $5.7 \pm 7.7$  months. Perioperative complications not significantly accumulated in either group. Both groups showed comparable drop in Eckardt scores.

**Conclusions:** Heller myotomy and Dor fundoplication is a safe and durable option for treatment of achalasia for both treatment naive patients and patients with previous repeated ET modalities.

**Key Words:** Achalasia, Heller myotomy, botulinum toxin, surgery

---

Corresponding Author<sup>®</sup>: Zeynep Bilgi, Kars Harakani State Hospital, Department of Thoracic Surgery, Kars, Turkey.

E-mail: zeynep.bilgi@gmail.com

Received 18.11.2016 accepted 20.02.2017

## Introduction

Achalasia is a motility disorder of the esophagus characterized by loss of neurons in myenteric plexus, impaired coordinated relaxation of lower esophageal sphincter (LES) and aperistalsis of the body of the esophagus, resulting in progressive dysphagia and esophageal dilation due to food stasis. If untreated, it leads to a poor quality of life with pain / difficulty in swallowing, retrosternal pain, regurgitation, weight loss, respiratory issues secondary to aspiration [1, 2]. The severity of the symptoms is mostly assessed by using the Eckardt scoring system [1]. Although the exact cause of achalasia is unknown, most of the promising research focuses on viral and autoimmune etiologies. Currently treatment strategies offer symptomatic and functional relief through relaxation of LES barrier, there is also evidence of partial return of the peristaltic function of the esophagus after long term resolution of the outflow obstruction [3]. Endoscopic treatments like balloon dilatation and botulinum toxin injection can provide quick relief with low morbidity and mortality but repeated attempts may be needed to maintain quality of life [4]. Myotomy on the other hand, can be achieved either by minimally invasive surgery or per oral endoscopic myotomy (POEM). Laparoscopic Heller myotomy and partial fundoplication is a well-established surgical procedure for achalasia with long term data on patient selection, complications, hospital stay and overall effectiveness [5]. POEM is a promising new technique delivering good symptom relief, but concerns over lack of long term data, learning curve and post procedure gastroesophageal reflux still remain [6].

Since there is a wide range of approaches available for treatment of achalasia and not a single option is firmly established as a gold standard for first choice. There is a significant subset of patients who received previous single / multiple endoscopic treatments and then referred for surgery due to the persistence of symptoms. Balloon dilatation / botulinum toxin injection can induce anatomic disruptions, loss of tissue planes, fibrosis/scar tissue around gastroesophageal junction (GEJ) and interfere with safety of standard surgical myotomy technique. We report our results of laparoscopic Heller myotomy and Dor fundoplication for patients who had previous balloon dilatation in comparison to patients who underwent surgery as a first line treatment.

## Materials and Methods

112 achalasia cases were operated on in our institution between 2007 and 2015 and were recorded in a prospective database. All patients underwent appropriate informed consent procedure, agreeing for further follow up, recording and usage of anonymized medical data for scientific and medical purposes. All procedures followed were in accordance with the ethical standards of the responsible committee on human experimentation (institutional and national) and with the Helsinki Declaration of 1975, as revised in 2008.

88 patients were available for long term follow up. Patients were assigned into two groups as Group 1 (n=55); surgery as first line treatment, Group 2 (n=33); surgery after prior endoscopic treatment. All patients had standard workup for esophageal motility disorders (esophageal standard and/or high resolution manometry, esophagogram) and their demographic data, pre/post-operative Eckardt scores, length of hospital stays and perioperative complications were recorded.

Heller Myotomy and Dor Fundoplication was performed by the same surgical team. The operation was conducted laparoscopically with 4 port placements, typically three 5 mm trocars and one 10 mm trocar.

Data was analyzed using SPSS 11.0 software. Mann Whitney U test was used for evaluating pre and post-surgery changes in Eckardt scores, Student's T test was used for group comparison.

## Results

Out of 112 patients who underwent laparoscopic Heller myotomy and Dor fundoplication, 88 were available for long term follow up and consented to participate in the study. Patient characteristics and demographic data are summarized in Table 1. Group 1 and 2 had an even distribution of patient gender and age. Average duration of effectivity per attempt of endoscopic treatment was 5.7 months (1-12 months). Perioperative results and outcomes are summarized in Table 2. Both groups enjoyed comparable relief of symptoms measured by decreased Eckardt scores after surgery (Group 1=86%, Group 2=85%) (Figures 1 and 2). There was no mortality and major morbidity in either group. Average hospital stay and perioperative complications did not differ between the two groups.



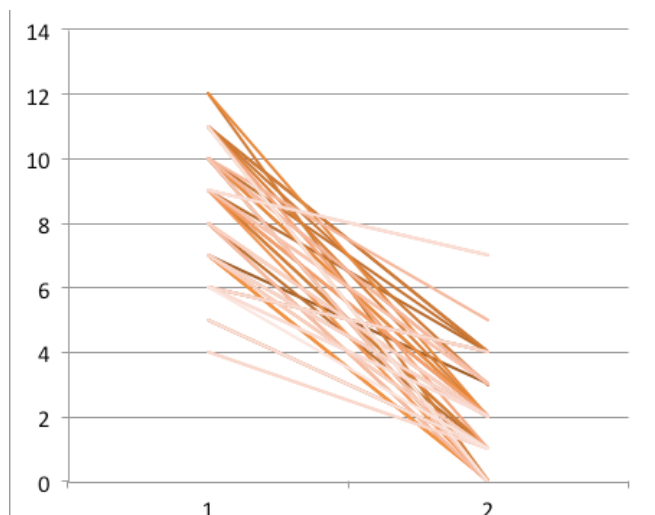


Figure 1. Pre/Postoperative Eckardt Scores for Group 1

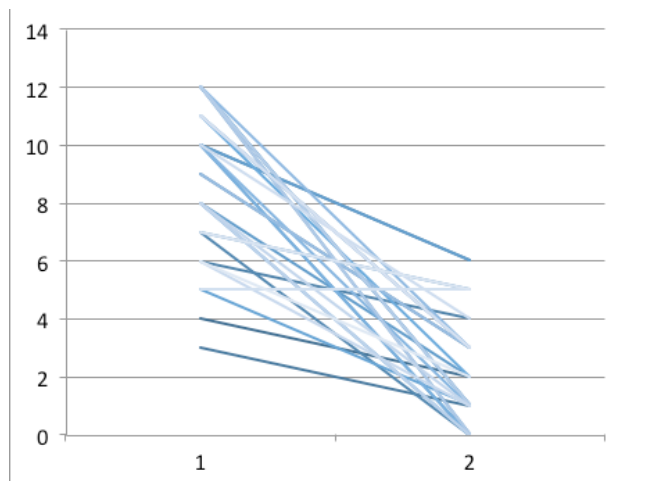


Figure 2. Pre/Postoperative Eckardt Scores for Group 2

Table 2. Perioperative results and outcomes			
	Group 1	Group 2	P value
Mean hospital stay (days)	2.3 ± 0.7	2.5 ± 0.8	NS
Perioperative complications	Mucosal perforation and repair n=2 Arrhythmia n=1 Pneumothorax n=1	Mucosal perforation and repair n=3 Incomplete Myotomy n=1	NS
Preoperative Eckardt Score	8.2 ± 2	8.7 ± 2.6	NS
Postoperative Eckardt Score	1.8 ± 1.7	1.8 ± 0.3	NS

### Discussion

Laparoscopic Heller Myotomy and Dor fundoplication offers a durable, safe and effective solution for patients both as a first and second line treatment strategy. In terms of technical difficulty, anatomic changes and fibrosis related to stasis, dilatation and loss of normal tissue planes can be shown histologically and may be exacerbated by prior endoscopic treatment attempts [7], but this fact did not necessary translate itself into decreased benefit from surgery, increased hospital stay / morbidity. Both patient groups benefited from surgery as expected, demonstrated by drop in their dysphagia scores, correlating with existing literature [8].

Even though our data reveals that average duration of symptom control after an endoscopic treatment modality is close to 6 months, there is a wide range of distribution. There are studies for balloon dilatation as a first line technique and show the same pattern as well. From a clinical point, this variation in response to treatment, low morbidity and mortality and possibility of equally safe surgery after endoscopic treatment forms the rationale for a trial of endoscopic treatment as a first line option for many gastroenterologists [4]. The outcome from laparoscopic Heller myotomy is shown to be durable beyond 1 year (86% vs 76%) with very low relapse rates when compared with balloon dilatation [9]. At 2 years, a significant subset of patients (15-30%) will require symptom control for dysphagia after balloon dilatation [9,10] (Table 3).

Table 1. Patient characteristics		
	Group 1 (Primary surgery) (n=55)	Group 2 (Prior ET) (n=33)
Mean age (years)	42.6 ± 15.4 (21-68)	44.5 ± 15.6 (25-80)
Male/Female	27/28	12/21
Comorbidities	Hypertension : 3 Hypothyroidism : 2 Previous abdominal surgery : 4	Hypertension : 8 Hypothyroidism : 2 Asthma : 1
Endoscopic treatment method		Balloon dilatation x 1 = 14 x 2 = 13 x >2 = 4
x Number of attempts = Number of patients		Botox injection x 1 = 1 x 2 = 1
Follow up (months)	55 ± 33	61 ± 37

**Table 3.** Comparison of various treatment methods for achalasia

Study	Technique	Number of patients	Morbidity/ Mortality	Rate of success	Follow-up
Chang/2004 (12)	Endoscopic	66	4% perforation		5 years
Kilic/2009 (11)	LHM	46	NR	96%	6.4 years
Sharata/2015 (6)	POEM	100	6% Intra-tunnel leak: 3 Hemorrhage: 2 Prolonged intubation: 1	97% (as improvement in Eckardt score)	1 year

For patients failing to respond optimally to endoscopic treatment options, referral for surgery seems to be just as safe and also a definitive solution for outflow obstruction. It results in return of peristaltic function of esophagus and potentially better long term functionality [3].

POEM also shows promising results [6], but there is no long term data available. Large case series show it to be an option comparable to surgery and caution should be exercised for patients with long standing disease and for patients who are not treatment naïve. Technical impossibility of adding an antireflux barrier procedure to POEM and already increased risk of esophageal cancer in achalasia patients may be a point of concern in the future.

In conclusion, endoscopic treatment modalities for achalasia have variable durations of symptomatic control with low risk of morbidity and do not preclude surgery for more definitive solution. Laparoscopic Heller Myotomy and Dor fundoplication results in equally favorable outcomes in both endoscopically treated and treatment naïve patients, also may provide for return of esophageal motility in long term (Table 3). POEM proponents have published encouraging results but the procedural safety itself and long term results for inability to include an anti-reflux barrier needs to be evaluated.

### Declaration of conflicting interests

The author declared no conflicts of interest with respect to the authorship and/or publication of this article.

### Funding

The author received no financial support for the research and/or authorship of this article.

### References

- Alexander J, Eckardt, Volker F, Eckardt Treatment and surveillance strategies in achalasia: an update. *Nat Rev Gastroenterol Hepatol* 2011; 8: 311-319.

- Gupta M, Ghoshal UC, Jindal S, Misra A, Nath A, Saraswat VA. Respiratory dysfunction is common in patients with achalasia and improves after pneumatic dilation. *Dig Dis Sci* 2014; 59: 744-52.
- Roman S, Kahrilas PJ, Mion F, Nealis TB, Soper NJ, Poncet G, et al. Partial recovery of peristalsis after myotomy for achalasia: more the rule than the exception. *JAMA Surg* 2013; 148: 157-64.
- Richter JE, Boeckxstaens GE. Management of achalasia: surgery or pneumatic dilation. *Gut* 2011; 60: 869-76.
- Krishnamohan P, Allen MS, Shen KR, Wigle DA, Nichols FC 3rd, Cassivi SD, et al. Long-term outcome after laparoscopic myotomy for achalasia. *J Thorac Cardiovasc Surg* 2014; 147: 730-6.
- Sharata AM, Dunst CM, Pescarus R, Shlomovitz E, Wille AJ, Reavis KM, et al. Peroral endoscopic myotomy (POEM) for esophageal primary motility disorders: analysis of 100 consecutive patients. *J Gastrointest Surg* 2015; 19: 161-70; discussion 170.
- Bloomston M, Fraiji E, Boyce HW Jr, Gonzalvo A, Johnson M, Rosemurgy AS. Preoperative intervention does not affect esophageal muscle histology or patient outcomes in patients undergoing laparoscopic Heller myotomy. *J Gastrointest Surg* 2003; 7: 181-8; discussion 188-90.
- Schoenberg MB, Marx S, Kersten JF, Rösch T, Belle S, Kähler G, et al. Laparoscopic Heller myotomy versus endoscopic balloon dilatation for the treatment of achalasia: a network meta-analysis. *Ann Surg* 2013; 258: 943-52.
- Yaghoobi M, Mayrand S, Martel M, Roshan-Afshar I, Bijarchi R, Barkun A. Laparoscopic Heller's myotomy versus pneumatic dilation in the treatment of idiopathic achalasia: a meta-analysis of randomized, controlled trials. *Gastrointest Endosc* 2013; 78: 468-75.
- Boeckxstaens GE, Annese V, des Varannes SB, Chaussade S, Costantini M, Cuttitta A, et al. Pneumatic dilation versus laparoscopic Heller's myotomy for idiopathic achalasia. *N Engl J Med* 2011; 364: 1807-16.
- Kilic A, Schuchert MJ, Pennathur A, Gilbert S, Landreneau RJ, Luketich JD. Long-term outcomes of laparoscopic Heller myotomy for achalasia. *Surgery* 2009; 146: 826-31; discussion 831-3.
- Chan KC, Wong SK, Lee DW, Mui WL, Chan AC, Ng EK, et al. Short-term and long-term results of endoscopic balloon dilation for achalasia: 12 years' experience. *Endoscopy* 2004; 36: 690-4.

To cite this article: Sayan M, Çelik A, Demiröz ŞM, Önen Hİ, Akyürek N, Konaç E, Kurul İC, Taştepe Aİ. Upregulated mRNA expression of mTOR in surgically resected early stage non-small cell lung carcinoma: a potential molecular targeted therapy. *Curr Thorac Surg* 2017; 2(1): 5-10.

## Original Article

# Upregulated mRNA expression of mTOR in surgically resected early stage non-small cell lung carcinoma: a potential molecular targeted therapy

Muhammet Sayan<sup>1a</sup>, Ali Çelik<sup>2</sup>, Şevki Mustafa Demiröz<sup>3</sup>, Hacer İlke Önen<sup>4</sup>, Nalan Akyürek<sup>5</sup>, Ece Konaç<sup>4</sup>, İsmail Cüneyt Kurul<sup>2</sup>, Abdullah İrfan Taştepe<sup>2</sup>

<sup>1</sup>Department of Thoracic Surgery, School of Medicine, Kahramanmaraş Sütçü İmam University, Kahramanmaraş,

<sup>2</sup>Department of Thoracic Surgery, School of Medicine, Gazi University, Ankara,

<sup>3</sup>Department of Thoracic Surgery, Atatürk Chest Diseases and Thoracic Surgery Training and Research Hospital, Ankara

<sup>4</sup>Department of Medical Biology and Genetics, School of Medicine, Gazi University, Ankara

<sup>5</sup>Department of Pathology, School of Medicine, Gazi University, Ankara, Turkey

## ABSTRACT

**Background:** Non-small cell lung cancer (NSCLC) comprises about 85% of all lung cancers. Although many attempts for early detection and treatment, prognosis of NSCLC is still poor. In recent years the pathways and the genes that play role in lung cancer development were researched widely. PI3K/AKT/MTOR which is thought to be efficacious in the development of many cancer which controls the expression of many genes playing an important role in cell proliferation, metastasis, resistance to apoptosis and angiogenesis. Also the increase in CCND1 expression was shown in several cancer types. The aim of this study is to search the mRNA expression profile of AKT, MTOR and CCND1 genes which has been thought to play role in NSCLC development, and their expression in different pathological stages and histological types of the disease.

**Materials and Methods:** Forty-four NSCLC patients who didn't get neoadjuvant therapy were included in this study. The samples from tumor and matched normal lung tissue were obtained from resection specimens (lobectomy or pneumonectomy). Total cellular RNA was isolated from the samples. The mRNA expression levels of AKT1, mTOR and CCND1 genes were measured by quantitative real-time polymerase chain reaction (qPCR).

**Results:** Our findings revealed a statistically significant increase of mTOR expression on mRNA levels ( $P < 0.05$ ). Although AKT and CCND1 expression slightly increased in malign tissues, these changes in the expression were not significant ( $P > 0.05$ ). The mRNA expression of mTOR was also upregulated and it was statistically significant for early stage disease and adenocarcinoma subtype ( $P < 0.05$ ).

**Conclusions:** Inhibition of mTOR gene expression at mRNA level might be potential target for future treatment strategies of NSCLC.

**Key Words:** non-small cell lung cancer, mRNA expression, AKT1, mTOR, CCND1

Corresponding Author<sup>®</sup>: Muhammet Sayan, MD. Department of Thoracic Surgery, School of Medicine, Avşar Kampüsü, Kahramanmaraş, Turkey.

E-mail: drsayann@gmail.com

Received 26.12.2016 accepted 15.02.2017

## Introduction

Non-small cell lung cancer (NSCLC) which comprises about 85% of all lung cancers is one of the most common causes of malignancy-related death in developed countries [1,2]. Smoking is the leading risk factor for developing lung cancer, but not all of the smokers develop cancer, suggests that environmental and genetic factors contributes to the risk of cancer development [3]. Although new techniques are developed to detect lung cancer at an early stage, the prognosis is still poor [4]. Hence, development of new therapeutic strategies is still a need for achieving better survival rates.

Clinical course of NSCLC can highly differ from patient to patient within same stage and between different age groups. The wide variation in the clinical behavior of similar tumors is related to the difference in the genetic code that underpins the biology of these tumors. Therefore, comprehensive genomic profiling may play a pivotal role in identifying these leading genomic alterations. They could potentially be targeted by molecular agents, which would undeniably change the poor outcome of this devastating disease [5].

Over activation of phosphoinositide 3-kinase (PI3K)/protein kinase B (AKT), the mechanistic target of rapamycin (mTOR) pathway, plays a pivotal role in tumor growth, invasion, and angiogenesis [6]. AKT is an upstream positive regulatory of the mammalian target of rapamycin (mTOR). In fact, mutation and alteration of gene expressions involved in PI3K/AKT/mTOR pathway are shown to contribute NSCLC development [7].

The key downstream molecular target of PI3K/AKT/mTOR pathway is mTOR [8]. The aberrant expression of mTOR was previously shown in NSCLC [9]. Activation of mTOR results in elevated protein synthesis and G1 cell cycle progression [10]. Furthermore, it was reported that inhibition of mTOR leads to suppression of cyclin D1 and consequently, inhibition of proliferation [11].

The goal of this study was to compare mRNA expression of AKT1, mTOR, and CCND1 (cyclin D1) genes in matched normal and malignant NSCLC tissue samples. Moreover, we also aimed to determine mRNA expression profile of these genes in different pathological stages and histological types of NSCLC.

## Materials and Methods

### *Patients Characteristics*

The study population consisted of 44 newly diagnosed patients with non-small cell lung carcinoma (NSCLC) who underwent curative surgical treatment between March 2011 and December 2011 at Gazi University Thoracic Surgery Department. The study protocol was approved by the Local Ethics Committee of Gazi University Faculty of Medicine and written informed consents were obtained from all patients. The exclusion criteria were, received neoadjuvant treatment (chemotherapy or radiotherapy), radiologic tumor size < 2 cm and tumors which occupy nearly all of the resection material (there is almost no grossly normal tissue). Just after the surgical resection (lobectomy or pneumonectomy) matched tumor and adjacent normal (at least 4 cm apart from the tumor) tissue samples were collected from the resection specimen. The fresh specimens were cut into ~1 g pieces in operation room and frozen in liquid nitrogen. Then, tissue samples were immediately transferred to -80 °C freezer. All tumor specimens were confirmed by histological examination to contain at least 70% of neoplastic tissue, while all macroscopically normal tissue samples were confirmed to be “normal” by the same pulmonary pathologist.

### *RNA extraction*

Total cellular RNA was extracted using peqGOLD Tri-Fast™ reagent (Peqlab, Erlangen, Germany) according to the supplier's recommendations. Tissue samples were placed in 1 mL Trizol and homogenized using an Ultra Turrax® T10 homogenizer (IKA Werke GmbH & Co. KG, Staufen, Germany). To remove potential traces of DNA, total RNA samples were incubated with DNase (DNaseI, Roche Diagnostics, GmbH, Mannheim, Germany) for 30 min at 37 °C. Then, all samples were washed with 75% ethanol and resuspended in sterile RNase-free H<sub>2</sub>O. RNA samples were kept at -80 °C until further analysis. Nanodrop spectrophotometer (NanoDrop ND-1000, Montchanin, DE, USA) was used for measuring RNA concentration precisely.

### *Complementary DNA (cDNA) Synthesis*

Transcriptor First Strand cDNA Synthesis Kit (Roche Diagnostics GmbH, Mannheim, Germany) was used to reverse transcribe cDNA from 1 µg of RNA by the help of random hexamer primer. cDNA reactions were carried out in an Eppendorf Mastercycler EP gradient S thermal cycler (Eppendorf, Hamburg, Germany). Then, all samples were stored at -20 °C until assayed.

### Analysis of Gene Expression by mRNA

Gene-specific intron spanning primer pairs and their appropriate probes were chosen relevant to the Universal Probe Library (UPL) Assay Design Center (<https://www.universalprobelibrary.com>). Primers sequences of the studied genes and UPL probe numbers were listed in Table 1. The crossing points (Cp) were calculated for each transcript using the Light Cycler®480 instrument (Roche Diagnostics GmbH, Mannheim, Germany). Quantitative real-time PCR (qPCR) conditions were as follows; 50 cycles, kept at 95 °C for 15 seconds and at 60 °C for 20 seconds and then the samples were cooled to 40 °C. Gene expression levels of the studied genes were normalized to the housekeeping gene glyceraldehyde-3-phosphate dehydrogenase (GAPDH). All qPCR reactions were repeated three times.

**Table 1.** Primer sequences and UPL probe numbers used in mRNA analysis

Gene	Forward primer	Reverse primer	UPL prob no
AKT1	5'- CTGTCATC-GAACGCAC-CTT-3'	5'- GTCTG-GATGGCGGTT-GTC -3'	52
mTOR	5'- TGCTGGAA-GCCTTTGTC-TATG-3'	5'- CGCTTGTT-GCCTTTGG-TATT-3'	75
CCND1	5'- TGTCCTAC-TACCGCCT-CACA -3'	5'- CAGGGCTTC-GATCTGCTC -3'	16
GAPDH	5'-AGCCA-CATCGCTCA-GACAC-3'	5'-GCC-CAATACGAC-CAAATCC-3'	60

### Statistical analysis

Relative gene expression results of AKT1, mTOR and CCND1 genes were compared through “REST (2009 V2.0.13)” software using “Pair-wise Fixed Reallocation Randomization” statistical analysis test [12]. The  $P < 0.05$  was considered to be significant.

### Results

The details of the patient characteristics are presented in Table 2. The patient group consisted of 41 (93.2%) males and 3 (6.8%) females. The mean age was 61.1 (41-80) years. The exposure to smoking was at an average of 60 pack-years. Only two of the patients had no history of smoking. Histopathologic examination revealed 18 (40.9%) adenocarcinoma and 26 (59.1%) squamous cell

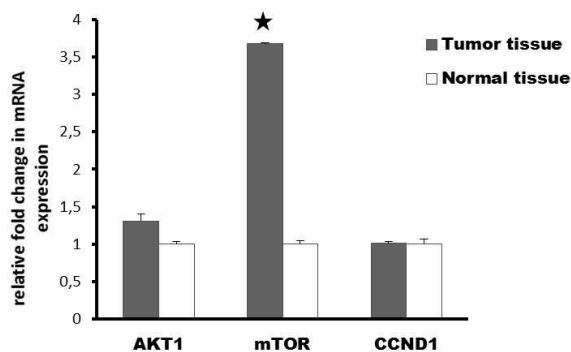
carcinoma. According to pathological staging, there were 8 (18.2%) patients with stage 1A, 9 (20.5%) patients with stage 1B, 16 (36.3%) patients with 2A, 4 (9.1%) patients with stage 2B, and 7 (15.9%) patients with stage 3A disease. The types of surgery performed were as follows; 33 (75%) lobectomy, 10 (22.7%) pneumonectomy, and 1 (2.3%) bilobectomy. Mediastinal lymph node dissection was performed in all patients for an effective pathologic staging (averagely 25 lymph nodes were dissected).

**Table 2.** Clinicopathologic characteristics of patients.

	Study population (n=44)	%
<b>Gender</b>		
Male	41	93.2
Female	3	6.8
Age (mean ± SD)	61 ± 0.1	
<b>Age range (years)</b>		
≤60	22	50
>60	22	50
<b>Smoking status</b>		
Never-smoker	2	4.5
Current or ex-smoker	42	95.5
Smoking (mean) (PY) <sup>a</sup>	56.9	
<b>Histology</b>		
Squamous Cell Carcinoma	26	59.1
Adenocarcinoma	18	40.9
<b>Pathologic Stage</b>		
I	17	38.6
II	20	45.5
III	7	15.9
<b>Surgical Treatment</b>		
Pneumonectomy	10	22.7
Lobectomy	33	75
Bilobectomy	1	2.3

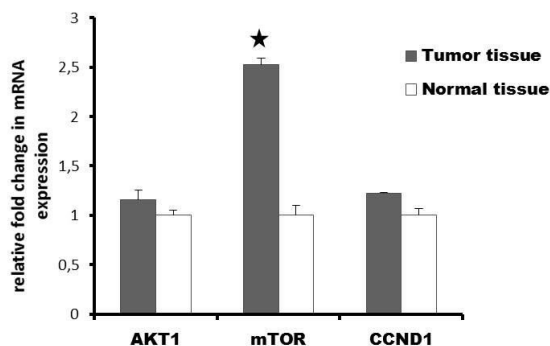
<sup>a</sup>PY= *packet/year*

mRNA expression levels of AKT1 in the tumor tissue was 1.1 times higher than in the matched normal lung tissue, but this increase was not significant ( $P > 0.05$ ). On the other hand the mRNA expression level of mTOR gene was elevated by 2.5 fold ( $P < 0.05$ ) in tumor tissue when compared to matched normal lung tissue. Also there was a 1.2 fold increase in the expression level of CCND1 in tumor tissue when compared to the matched normal lung tissue, and this increase was not also significant ( $P > 0.05$ ). mRNA expression levels of studied genes were demonstrated in Figure 1.



**Figure 1.** Comparison of AKT1, CCND1, and mTOR mRNA expression levels in tumor tissues and matched normal lung tissues. \*Denotes a statistically significant difference between tumor tissues and matched normal lung tissues.

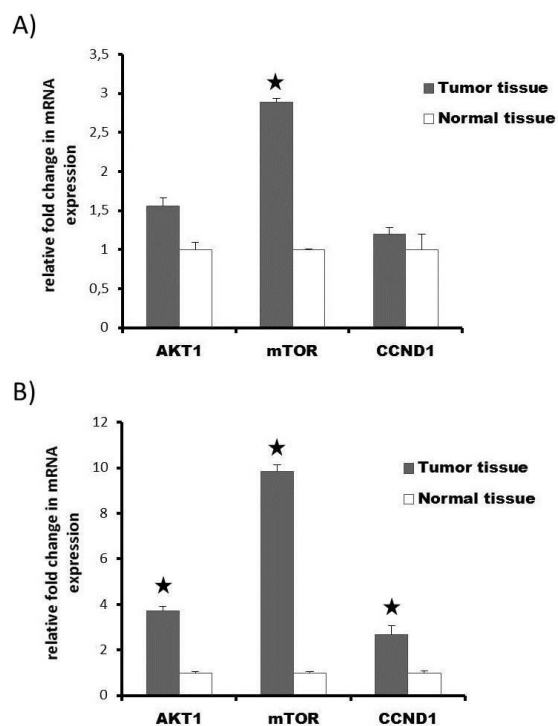
The subtype analyze according to the histologic type of NSCLC revealed statistically significant elevation of mTOR mRNA expression (3.6 fold) in adenocarcinoma (ADC) ( $P < 0.05$ ) (Figure 2). A slight upregulation of mTOR expression levels is also found in squamous cell carcinoma (SCC) but this increase was not statistically significant ( $P > 0.05$ ). We failed to find significant differences in AKT1 and CCND1 expression levels among these two histologic types ( $P > 0.05$ ).



**Figure 2.** Comparison of AKT1, CCND1, and mTOR mRNA expression levels in ADCs and matched normal lung tissues. \*Denotes a statistically significant difference between tumor tissues and matched normal lung tissues.

mRNA expressions of studied genes were also analyzed in accordance with pathological stage. mRNA expression levels of mTOR in stage 1 tumors were 2.8 times higher than in the matched normal lung tissue ( $P < 0.05$ ) (Figure 3A). More detailed analysis revealed that there was a 9.8 fold increase in the expression level of mTOR in stage 1A tumors, when compared to match normal lung tissue ( $P < 0.05$ ). Two other studied genes, AKT1 and CCND1 were also upregulated 3.7 and 2.6 fold times, respectively ( $P < 0.05$ ) (Figure 3B). We also found important changes (range 1.9–3.5 fold) for mTOR

mRNA expression in other stages between tumor tissue and matched normal lung tissue, but these differences did not make statistical significance (data not shown).



**Figure 3.** (A) Comparison of AKT1, CCND1, and mTOR mRNA expression levels in stage 1 tumors and matched normal lung tissues. (B) Comparison of AKT1, CCND1, and mTOR mRNA expression levels in stage 1A tumors and matched normal lung tissues. \*Denotes a statistically significant difference between tumor tissues and matched normal lung tissues.

### Discussion

NSCLC accounts for 85% of all lung cancers, which adenocarcinomas and squamous cell carcinomas constitute approximately 80% of this type of lung cancer [13]. It is accepted that, the successful discovery, validation and implementation of specific molecular markers for early diagnosis and subsequent timely clinical intervention could vastly improve the appalling mortality rate for this devastating cancer [14].

Yue et al. showed an elevated mRNA expression levels of AKT1 gene, as compared to adjacent-tumor tissue [15]. In the present study, the expression of AKT1 mRNA was increased in the tumor tissue as compared to matched normal tissue, but the upregulation was not statistically significant. However, the analysis according to tumor stage showed that mRNA expression level of AKT1 gene elevated by 3.7 fold in stage 1A tumors. No significant differences were found in AKT1 mRNA

expression levels among the two histologic subtypes of NSCLC. Up to our knowledge, this is the first study to show the mRNA expression levels of AKT1 in NSCLC in Turkish population.

While there is only one study about AKT1 mRNA expression in NSCLC, several studies were already conducted to analyze mTOR mRNA expression levels in patients with NSCLC. With regard to mTOR expression, it was reported that there was an up-regulation in the expression level of mTOR in tumor tissue as compared to adjacent-tumor tissue [15]. Similarly, Wang et al. showed that mRNA expression levels of mTOR in the tumor tissue were outstandingly higher than in adjacent-tumor tissue [16]. Moreover, Liu et al. reported that mTOR mRNA expression was elevated in tumor tissue as compared to matched normal tissue [9]. These results are similar to our study and show the contribution of mTOR signaling pathway in the development of NSCLC. As far as we know, the current study is also the first to measure mTOR mRNA expression in the tissue samples of NSCLC patients in the Turkish population. We showed an upregulated mTOR mRNA expression levels by 2.5 fold in tumor tissue, when compared to match normal lung tissue.

On the other hand, a previous study has failed to find association between the mRNA expression level of mTOR gene and pathologic type [16]. Similarly, another study showed that the mRNA expression of the mTOR gene tended to increase in patients with advanced stage (stage III) NSCLC, however, this elevation did not reach statistical significance (9). Conversely, we found a relation between upregulated mRNA expression levels of mTOR in stage 1 tumors. We also showed that mRNA expression level of mTOR gene is elevated by 3.6 fold in ADCs.

Detecting of increased mRNA expression levels in stage 1A; a 3,7 fold for AKT1 and a 9,8 fold for mTOR gene, our study suggests that there might be other genes activating mTOR besides AKT1.

Li et al. showed that total CCND1 and its two splice variants (CCND1a and CCND1b) mRNA expression levels were elevated in tumor tissue as compared to non-malignant tissue at both mRNA and protein levels [17]. In the present study, the level of CCND1 mRNA expression was higher in the tumor tissue than in matched normal lung tissue, but the increase was not statistically significant. Li et al. also demonstrated a relationship between mRNA expression levels of total cyclin D1 and

tumor stage of the patients [17]. We found that mRNA expression level of CCND1 gene elevated by 2.6 fold in tumor tissue of stage 1A, when compared to match normal lung tissue. No significant differences were found in CCND1 mRNA expression levels among the two histologic types of NSCLC. According to our knowledge, this is the first study to examine the mRNA expression levels of CCND1 in NSCLC in Turkish population.

Although carcinogenetic effect of smoking habits on lung cancer development is shown via the AKT/mTOR pathway, we are not able to carry out a formal comparison due to the limited number of non-smokers in our study [3]. We believe that further studies with larger number of patients should be conducted to demonstrate such a relation.

Following mTOR-siRNA transfection of NSCLC cells, the suppression of cell proliferation, migration and induction of apoptosis were observed [18]. Hence, RNA interference (RNAi)-mediated transcriptional gene silencing might result in more promising patients' outcome instead of blocking the action of the protein.

The main limitations of our study are the relatively small number of cases and the uneven distribution of female patients as compared to males. But in our country lung cancer incidence is nearly 10 times higher in males and we think our study is truly reflecting Turkish population. Due to freshly resected samples included this study and short patient follow up period; it is not possible to determine the association of mRNA expression of mTOR and prognosis.

As a conclusion detection of aberrant mRNA expression profiles in freshly resected tumor tissue could be helpful to determine real molecular target. Thus, with the selection of patients according to their molecular signature is crucial for achieving the aim of personalized medicine. We can speculate that, inhibition of mTOR gene expression may be used to prevent tumor development because of the presence of higher mTOR mRNA expression at earlier stages of tumor tissues. Short interfering RNA (siRNA)-mediated degradation of mTOR mRNA before translation might take into consideration another therapeutic approach for treatment NSCLC patients. We think this study will be a guide to other researchers who will plan a study on Turkish population. But further studies with larger number of patients should be planned to achieve more definite conclusions.

### Declaration of conflicting interests

The author declared no conflicts of interest with respect to the authorship and/or publication of this article.

### Disclosure

Partial support for this study was provided by Gazi University Research Foundation (Project code no. 01/2011-21).

### References

1. Deffebach ME, Humphrey L. Lung Cancer Screening. *Surg Clin North Am* 2015; 95: 967-78.
2. Hu Q, Zhou Y, Ying K, Ruan W. IGFBP, a novel target of lung cancer? *Clin Chim Acta* 2017; 466: 172-7.
3. Memmott RM, Dennis PA. The role of the Akt/mTOR pathway in tobacco carcinogen-induced lung tumorigenesis. *Clin Cancer Res* 2010; 16: 4-10.
4. Luo X, Zang X, Yang L, Huang J, Liang F, Rodriguez-Canales J, et al. Comprehensive Computational Pathological Image Analysis Predicts Lung Cancer Prognosis. *J Thorac Oncol* 2017; 12: 501-9.
5. Vooder T, Metspalu A. Investigating gene expression profile of non-small cell lung cancer. *Cent Eur J Med* 2011; 6: 608-15.
6. Bartholomeusz C, Gonzalez-Angulo AM. Targeting the PI3K signaling pathway in cancer therapy. *Expert Opin Ther Targets* 2012; 16: 121-30.
7. Fumarola C, Bonelli MA, Petronini PG, Alfieri RR. Targeting PI3K/AKT/mTOR pathway in non small cell lung cancer. *Biochem Pharmacol* 2014; 90:197-207.
8. Caron E, Ghosh S, Matsuoka Y, Ashton-Beaucage D, Therrien M, Lemieux S, et al. A comprehensive map of the mTOR signaling network. *Mol Syst Biol* 2010; 6: 453.
9. Liu Z, Wang L, Zhang LN, Wang Y, Yue WT, Li Q. Expression and clinical significance of mTOR in surgically resected non-small cell lung cancer tissues: a case control study. *Asian Pac J Cancer Prev* 2012; 13: 6139-44.
10. Seeliger H, Guba M, Kleespies A, Jauch KW, Bruns CJ. Role of mTOR in solid tumor systems: a therapeutic target against primary tumor growth, metastases, and angiogenesis. *Cancer Metastasis Rev* 2007; 26: 611-21.
11. Law M, Forrester E, Chytil A, Corsino P, Green G, Davis B, et al. Rapamycin disrupts cyclin/cyclin-dependent kinase/p21/proliferating cell nuclear antigen complexes and cyclin D1 reverses rapamycin action by stabilizing these complexes. *Cancer Res* 2006; 66: 1070-80.
12. Pfaffl MW, Horgan GW, Dempfle L. Relative expression software tool (REST) for group-wise comparison and statistical analysis of relative expression results in real-time PCR. *Nucleic Acids Res* 2002; 30: e36.
13. Langer CJ, Besse B, Gualberto A, Brambilla E, Soria JC. The evolving role of histology in the management of advanced non-small-cell lung cancer, *J Clin Oncol* 2010; 28: 5311-20.
14. Liloglou T, Bediaga NG, Brown BR, Field JK, Davies MP. Epigenetic biomarkers in lung cancer. *Cancer Lett* 2014; 342: 200-12.
15. Yue W, Wang X, Wang Y. The Relationship between the PI3K/Akt/mTOR Signal Transduction Pathway and Non-small Cell Lung Cancer. *Zhongguo Fei Ai Za Zhi* 2009; 12: 312-5.
16. Wang L, Xu S, Yue W, Zhao X, Zhang L, Wang Y. Expression and clinical significance of mTOR and PTEN in non-small cell lung cancer. *Zhongguo Fei Ai Za Zhi* 2010; 13: 717-21.
17. Li R, An SJ, Chen ZH, Zhang GC, Zhu JQ, Nie Q, et al. Expression of cyclin D1 splice variants is differentially associated with outcome in non-small cell lung cancer patients. *Hum Pathol* 2008; 39: 1792-801.
18. Matsubara H, Sakakibara K, Kunimitsu T, Matsuoka H, Kato K, Oyachi N, et al. Non-small cell lung carcinoma therapy using mTOR-siRNA. *Int J Clin Exp Pathol* 2012; 5: 119-25.



To cite this article: Katrancıoğlu Ö, Şahin E, Karadayı Ş, Kaptanoğlu M. Diagnosis and treatment approaches of the lung hydatid cysts in childhood. *Curr Thorac Surg* 2017; 2(1): 11-14.

## Original Article

# Diagnosis and treatment approaches of the lung hydatid cysts in childhood

Özgür Katrancıoğlu<sup>a</sup>, Ekber Şahin, Şule Karadayı, Melih Kaptanoğlu

Department of Thoracic Surgery, School of Medicine, Cumhuriyet University, Sivas, Turkey

### ABSTRACT

**Background:** Cyst hydatid is an important health problem in childhood and adult age group. We aimed to present the management of childhood cyst hydatid cases treated with surgery.

**Materials and Methods:** The records of 33 patients that were operated on for lung cyst hydatid disease at our clinic between 1999 and 2016 were evaluated retrospectively in terms of demographic data, clinical findings, location of cysts, treatment methods and follow-up.

**Results:** Among 33 patients included in this clinical analysis study, 20 were male (60.6%) and the mean age was 11.5 (4-15 years). The most common complaint was cough that was observed in 16 patients (48.4%). 78.8% of the patients had only one cyst, whereas 21.2% of the patients had multiple cysts. Cystotomy was performed in 12 patients (36.4%), cystotomy + capitonage in 14 patients (42.4%), and decortication in addition to cystotomy + capitonage in 7 patients (21.2%). There were no postoperative complications and no recurrences were observed during the follow-up.

**Conclusions:** Surgical treatment is the primary treatment that can be performed successfully and safely in childhood lung cysts hydatids.

**Key Words:** Pulmonary hydatid cysts, pediatric patients, treatment approaches, surgery

---

Corresponding Author<sup>a</sup>: Özgür Katrancıoğlu, MD. Department of Thoracic Surgery, Cumhuriyet University School of Medicine, 58140 Sivas, Turkey.  
E-mail: ozgursongur@gmail.com

Received 11.11.2016 accepted 28.01.2017

## Introduction

Hydatid cyst is a parasitic infectious disease that has been known since the time of Hippocrates, caused by *Echinococcus granulosus* which is commonly found in nature. It is endemic in the Mediterranean countries including Turkey [1-4]. In adults, lung is the second most common localization of the cysts following liver. Whereas in child age group, lungs are at the first rank [2]. Although it is common in adults, children are also frequently affected by this disease [5].

In this article, we aimed to present our experience of the surgical treatment of lung cyst hydatid at childhood period.

## Materials and Methods

33 patients under 15 years of age who were operated with the diagnosis of pulmonary hydatid cysts between 1999 and 2016 were retrospectively analysed. Patients' data were obtained from the hospital records. Demographic findings such as age, sex, patients' history and the symptoms and findings determined during physical examination were evaluated. Hematologic and biochemical blood tests, chest X-ray, computed thorax tomography (Thorax CT) and abdominal ultrasonography were performed and the results were reviewed. Localization of cysts, surgical technique and prognosis were evaluated.

## Results

The study was approved by the clinical research ethics committee of Cumhuriyet University (2016-10 / 16). The medical files of 33 cases of hydatid cyst in the pediatric age group were reviewed. 20 of the cases were female (60.6%) and 13 were male (39.4%). The mean age was 11.5 years (within 4-15 years range).

Cough was the most common symptom in the majority of cases, whereas 5 cases were asymptomatic. In these 5 patients, the cyst was determined on chest x-ray taken for different reasons. Figure 1 shows the distribution of symptoms.

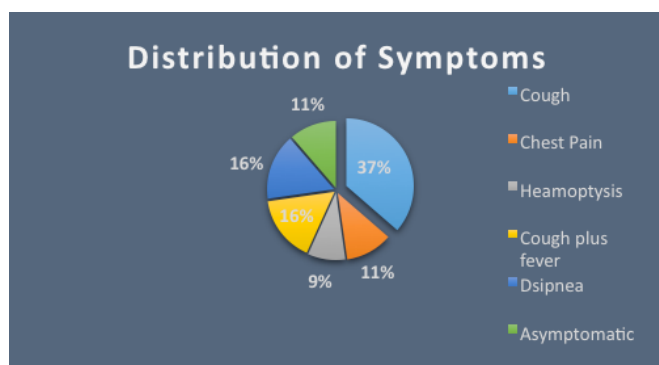


Figure 1. Symptoms of the cyst hydatid patients

All patients underwent PA chest X-ray and thorax CT before diagnosis. Except one patient all the patients presented with unilateral cysts. Two (6%) patients had concomitant liver cysts.

In 26 (78.8%) cases only one cyst was found, where 7 (21.2%) had multiple cysts. The cysts were of equal number in both lungs and lower lobes were more involved (Table 1). In the majority of patients (66.7%) there was a simple single lung cyst and observed as a well defined homogeneous mass in the radiological images (Figure 2). Cyst rupture was detected in 11 patients (33.3%) and no allergic or anaphylactic reaction was reported in any of these patient.

	Right lung	Left lung
Upper Lobe	2 (5.5%)	8 (22.2%)
Middle Lobe	5 (13.8%)	
Lower Lobe	11 (30.5%)	10 (27.7%)

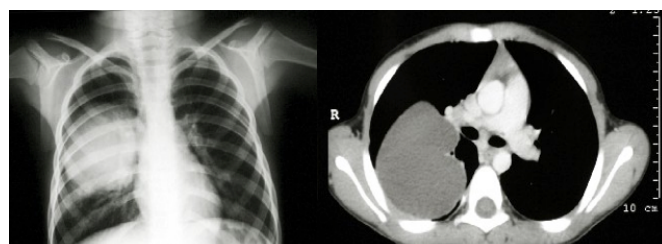


Figure 2. Chest x-ray (A) of a patient with intact large cyst and thorax CT scan (B)

All patients underwent a posterolateral thoracotomy. Cystotomy was performed in 12 patients (36.4%), cystotomy + capitonage in 14 patients (42.4%), and decortication in addition to cystotomy + capitonage in 7 patients (21.2%). Decortication had been performed in all cases with perforated hydatid cysts. A parenchymal resection such as lobectomy was not performed in any of the patients. The postoperative course was uneventful and no complications such as prolonged air leak, bronchopleural fistula, abscess or empyema were seen. During the followup no recurrences were detected.

## Discussion

Hydatid cyst is an important health problem all over the world and the incidence in our country is 20 / 100.000 [6-10]. Lung is the most frequent location of the hydatid cysts at childhood period [10-12], and its reported

that interestingly boys are effected more than girls. The explanation is based on the suggestion that boys start to contact with dogs earlier and more frequent than girls [7,9]. In our study, there was male predominance (60.6%) similar to the literature.

Intact lung cysts generally do not cause symptoms and tend to be asymptomatic in pediatric age group. Due to the delay in the diagnosis, the cyst were detected as larger sized cysts [7,13]. In our patient group, the cysts was 5 cm and bigger in diameter in 23 (69.7%) cases.

The patients applied to our clinic with one or more symptoms and cough was the leading one which was reported in 16 (48.4%) patients similar to the reports in the literature [2,10,14].

The most common diagnostic method for lung cyst hydatid disease is chest radiography [14]. The diagnosis of intact or asymptomatic pulmonary hydatid cysts is usually based on suspicion arising from an unexpected finding on routine chest x-ray [5]. Diagnostic radiological imaging methods are accepted to be more reliable than serological tests [8]. Thorax CT is an important imaging modality to demonstrate the density of intact cysts and to detect cysts that are not seen on posteroanterior chest X-ray [5,8].

In the literature it is reported that the pulmonary hydatid cysts are mostly single and multiple occurrence has been reported between 14% and 30%. It is most commonly seen in the lower lobes [7,8,15-17]. In consistent with the literature, 26 (78.8%) of our cases had single cysts and 21 (63.6%) cases had cysts were located at the lower lobes.

The main treatment for lung cyst is surgery [2,7]. The surgeon's goal is to remove the cyst with the membrane, to eradicate the parasite without forming a contaminant, and to close the remaining cavity [12]. The choice of surgical technique depends on the condition of the tissue surrounding the cyst during surgery. Commonly accepted procedures in surgery are parenchymal protective procedures [7]. While all alive parasitic material is removed, especially in children, the intact lung tissue should be preserved to a maximum extent. The most common surgical method is cystotomy and capitonage [2,18]. In our patients, the most common technique was cystotomy and / or cystotomy + capitonage performed in 32 (96.9%) cases. Especially in children, parenchymal resections should be avoided even if there

are complicated cysts as the affected parenchyma in children has a high recovery capacity [2,8]. In our series, no parenchymal resections were performed in any of the patients although the cysts were large or multiple.

It is reported that the most common postoperative complications after cyst surgery are prolonged air leak, pneumonia, recurrence, and empyema (16). In our series, our patients' postoperative follow-up were uneventful and no recurrent disease was observed.

As an alternative to surgery, albendazole therapy has recently been proposed. The efficacy of this treatment is influenced by the thickness of the cyst wall [19]. However, they generally have low response rates, severe drug reactions, markedly high perforations and recurrence rates. For this reason, albendazole therapy should be performed when there is disseminated disease, when the surgery is contraindicated, or in the presence of recurrence risk due to contamination [7]. We only administer albendazole treatment after surgery for the cases having a risk of contamination, as well.

As a conclusion, surgery was performed safely as the primary treatment of pulmonary cyst hydatid in pediatric patients where parenchymal preservation techniques should be preferred.

### Declaration of conflicting interests

The author declared no conflicts of interest with respect to the authorship and/or publication of this article.

### Funding

The author received no financial support for the research and/or authorship of this article.

### References

1. Çelik T, Akçora B, Tutanaç M, Yetim TD, Karazincir S, Akın MM, et al. Ruptured Pulmonary Hydatid Cyst: a Case Report. *Turkiye Parazitoloj Derg* 2012; 36: 45-7.
2. Cangir AK, Sahin E, Enon S, Kavukçu S, Akay H, Okten I, et al. Surgical treatment of pulmonary hydatid cysts in children. *J Pediatr Surg* 2001; 36: 917-20.
3. Sahin E, Enon S, Cangir AK, Kutlay H, Kavukçu S, Akay H, et al. Single-stage transthoracic approach for right lung and liver hydatid disease. *J Thorac Cardiovasc Surg* 2003;126: 769-73.
4. Cevik M, Boleken ME, Kurkcuoğlu IC, Eser I, Dörterler ME. Pulmonary hydatid disease is difficult recognized in children. *Pediatr Surg Int* 2014; 30: 737-41.

5. Çelik M, Senol C, Keles M, Halezeroglu S, Urek S, Hacıbrahimoglu G, et al. Surgical Treatment of Pulmonary Hydatid Disease in Children: Report of 122 Cases. *J Pediatr Surg* 35:1710-3.
6. Mahmodlou R, Sepehrvand N, Nasiri M. Saucerization: a modified uncapitonnage method of surgery for pulmonary hydatidosis. *World J Surg* 2013; 37: 2129-33.
7. Dincer SI, Demir A, Sayar A, Gunluoglu MZ, Kara HV, Gurses A. Surgical treatment of pulmonary hydatid disease: a comparison of children and adults. *Journal of Pediatric Surgery* 2006; 41: 1230-6.
8. Topcu S, Kurul IC, Tastepe I, Bozkurt D, Gulhan E, Cetin G. Surgical treatment of pulmonary hydatid cysts in children. *J Thorac Cardiovas Surg* 2000; 120: 1097-101.
9. Dakak M, Genc O, Gurkok S, Gözübüyük A, Balkanlı K. Surgical treatment for pulmonary hydatidosis (a review of 422 cases). *J R Coll Surg Edinb* 2002; 47: 689-92.
10. Aydogdu B, Sander S, Demirali O, Guvenc, Besik C, Kuzdan C, et al. Treatment of spontaneous rupture of lung hydatid cysts into a bronchus in children. *Journal of Pediatric Surgery* 2015; 50: 1481-3.
11. Berberoğlu B, Kaya Z, Aslan A.T, Çelik A, Kurul İ.C, Yücel C. Surgery and Interventional Treatments in a Child with Hydatid Cyst. *Gazi Med J* 2011; 22: 85-7.
12. Ozdemir A, Bozdemir S.E, Akbiyik D, Daar G, Korkut S, Korkmaz L, et al. Anaphylaxis due to ruptured pulmonary hydatid cyst in a 13-year-old boy. *Asia Pac Allergy* 2015;5: 128-31.
13. Rebhandl W, Turnbull J, Felberbauer FX, Tasci E, Puig S, Auer H, et al. Pulmonary echinococcosis (hydatidosis) in children: results of surgical treatment. *Pediatr Pulmonol* 1999; 27: 336-40.
14. Aydın ZGG, Yalcinkaya R, Teke TA, Bayhan GI, Oz FN, Timur OM, et al. Coexistence of Pulmonary Hydatid Cyst and Mycoplasma pneumoniae Pnömonia in a Child. *Turkiye Parazitol Derg* 2015; 39: 159-63.
15. Koca T, Dereci S, Gencer A, Duman L, Aktaş AR, Akcam M, et al. Cystic Echinococcosis in Childhood: Five-Years of Experience From a Single-Center. *Turkiye Parazitol Derg* 2016; 40: 26-31.
16. Usluer O, Ceylan KC, Kaya S, Sevinc S, Gursoy S. Surgical management of pulmonary hydatid cysts: is size an important prognostic indicator? *Tex Heart Inst J* 2010; 37: 429-34.
17. Ekingen G, Tuzlacı A, Güvenç H. Thoracoscopic surgery in the management of pediatric pulmonary hydatid cyst. *Turkish J Thorac Cardiovasc Surg* 2005; 13: 62-64.
18. Tuncozgun B, Elbeyli L. Pediatrik Akciğer Hidatik Kistlerinin Cerrahi Tedavisi. *Pediatrik Göğüs Cerrahisi*. Ed. Yüksel M, Kaptanoğlu M. *Pediatrik Göğüs Cerrahisi*. İstanbul Turgut Yayıncılık A.Ş. 2004: 319-34.
19. Dogru D, Kiper N, Ozcelik U, Yalcin E, Gocmen A. Medical treatment of pulmonary hydatid disease: for which child? *Parasitology International* 2005; 54: 135-8.

To cite this article: Gürsoy S, Yoldaş B, Üçvet A, Usluer O, Yazgan S, Aydoğdu Dinç Z. Solitary fibrous tumours, should they always considered to be benign gigantic masses? *Curr Thorac Surg* 2017; 2(1): 15-19.

## Original Article

# Solitary fibrous tumors, should they always considered to be benign gigantic masses?

Soner Gürsoy<sup>1</sup>, Banu Yoldaş<sup>1a</sup>, Ahmet Üçvet<sup>1</sup>, Ozan Usluer<sup>1</sup>, Serkan Yazgan<sup>1</sup>, Zekiye Aydoğdu Dinç<sup>2</sup>

<sup>1</sup> Department of Thoracic Surgery, Izmir Dr. Suat Seren Chest Diseases and Thoracic Surgery Training and Research Hospital, Izmir

<sup>2</sup> Department of Pathology, Izmir Dr. Suat Seren Chest Diseases and Thoracic Surgery Training and Research Hospital, Izmir, Turkey

### ABSTRACT

**Background:** Solitary fibrous tumors (SFT) are rare seen tumors assessed to be originated from pleura. Even though they are benign, after their complete resections malignant recurrences might be seen in follow up period. In this study, based on our case series undergone complete surgical resection due to SFT, we looked for an answer whether if it is convenient to accept these tumors as benign or not.

**Materials and Methods:** Patients undergone surgery between January 2000 and January 2011 were included in this study. Follow up data, patients and tumor histopathological characteristics were analysed.

**Results:** Our series consisted of 14 cases (eight male, six female) with a mean age of  $49.5 \pm 15.3$  (15-70 years). All patients' undergone thoracotomy, and complete resection was performed. The mean follow-up was  $50.3 \pm 30.6$  months (between 9 -101 months). Two recurrences were detected and both patients died due to recurrent disease.

**Conclusions:** Though they are considered to be benign lesions, SFT have a potential to come along with malignant recurrences. Recurrences were observed in giant tumors and this makes us think if it is possible to overlook a malignant focus in histopathological observation in such kind of big tumors. In this sense, patients should be informed in this regard and a complete and wide resection should be performed as much as possible with a long time follow up period as malignant diseases.

**Key Words:** Pleura, lung, intrathoracic pathology, wedge resection

Corresponding Author: Banu Yoldaş, MD, Izmir Dr. Suat Seren Chest Diseases and Thoracic Surgery Training and Research Hospital, Thoracic Surgery Department, 35100, Izmir /Turkey.

E-mail: banuaktin@yahoo.com

Received 08.02.2017 accepted 31.03.2017

## Introduction

Solitary fibrous tumors are mesenchymal tumors considered to be a form of mesothelioma and named as “benign pleural lipoma, localized pleural mesothelioma” in the past decades. They might origin from parietal or visceral pleura [1]. Since it has been first described in 1937, been the subject of several literature due to its rarity.

Although most of the patients are asymptomatic, non-specific symptoms such as chest pain, shortness of breath and cough might be seen [2-7]. Because sometimes pre-operative diagnosis have difficulties, complete resection is necessary for definitive diagnosis and treatment.

As we are going to discuss in this study, because of the potential for malignant recurrence following up the patients is also as important as complete resection. The aim of this study is to shed light on these points in the evaluation of our operated patients.

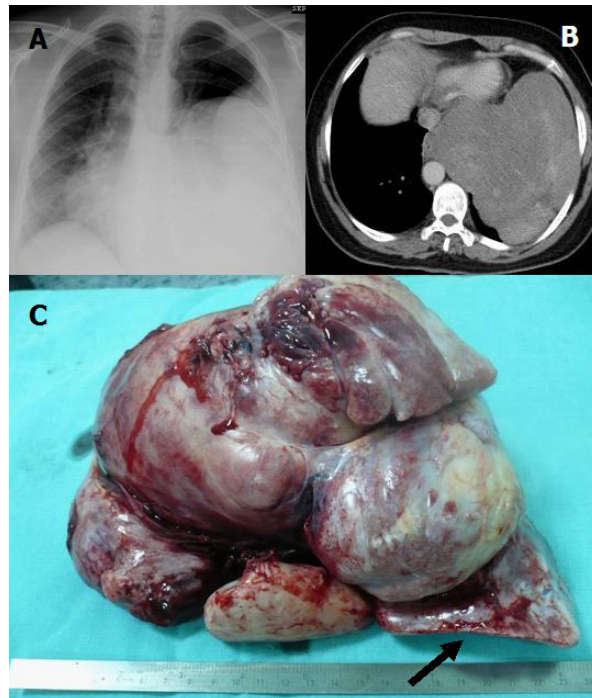
## Materials and Methods

Patients undergone surgery between January 2000 and January 2011 in our department consecutively and diagnosed as a solitary fibrous tumor histopathologically were included in this study. We declare that the study was performed in accordance with the ethical standards laid down in the Helsinki Declaration of 1975, as revised in 1983. Routine laboratory tests, respiratory function tests, chest X-ray and thorax computed tomography (CT) were done for all preoperative patients. The limitation of pulmonary function tests, in patients with a large lesion size, did not affect our surgical decision. Positron emission tomography was performed in only 2 patients demonstrating benign lesions with low FDG uptake. Patients with suspected invasion of surrounding tissues were evaluated with thoracic magnetic resonance imaging (MRI). Patients with no evidence of a significant invasion were operated after informed consent was taken. When any association with visceral pleura was detected, safe surgical margins were obtained with wedge resection. Similarly for the parietal pleura, care was taken to perform a wide resection to obtain safe surgical margins. These margins were all proved via frozen section analysis. Histopathological classification was done due to England criteria. Patients were analysed retrospectively according to age, sex, symptoms, radiologic features, preoperative diagnosis, type of operation, postoperative diagnosis and survival.

## Results

The mean age of the 14 patients included in the study was  $49.5 \pm 15.3$  years (range 15-70 years). Eight patients were male and six were female. While two of the patients were asymptomatic, other were suffering from

chest pain, shortness of breath, cough and sputum in the order of frequency. The location of the lesions were the same for right and left hemithorax. The median tumor size was  $11.7 \pm 6.6$  cm (range: 2.5-24 cm) when six of them were larger than 15 cm (Figure 1).

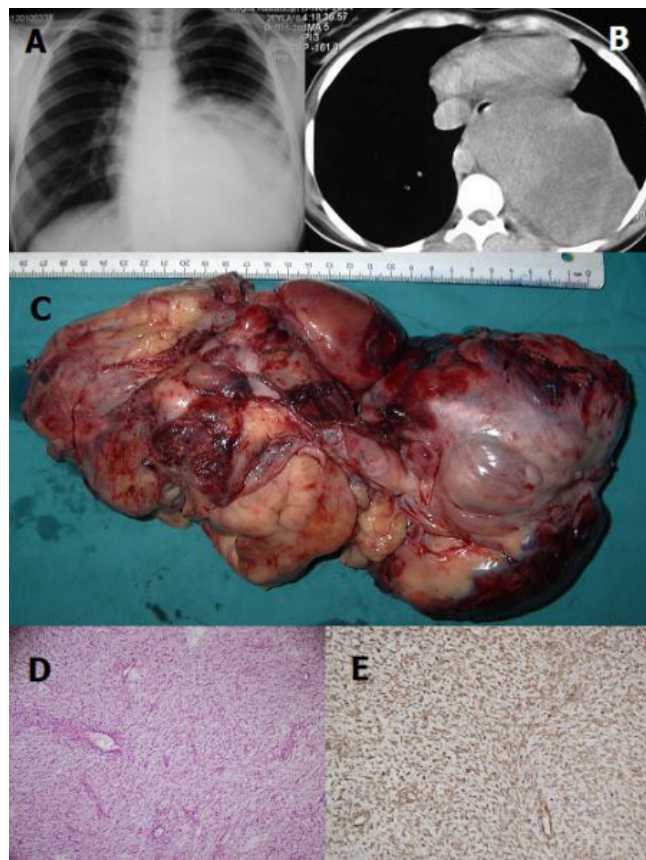


**Figure 1.** A, B. Radiological study of the giant mass. C. Macroscopic view demonstrating the lobulated but smooth contoured surface which was associated with visceral pleura at one point. (The arrow is showing this wedge resection side)

Preoperative diagnosis was obtained in a limited number of the patients, while some were diagnosed as “spindle cell mesenchymal tumor” and some were reported as “nondiagnostic material”. All patients undergone thoracotomy. Complete resection was intended, so tumors associated with parietal pleura were resected with surrounding parietal pleura, and for those associated with visceral pleura wedge resection was performed (in 12 patients) including tumor free parenchymal lung tissue. Tumors were originating from visceral pleura in eight cases, parietal pleura in two and from both pleura in four cases.

Median follow up time was  $50.3 \pm 30.6$  months (range 9-101 months) and was done with physical examination, chest X-ray and CT. One of the patients was reoperated in the 8th month of her follow up due to recurrent gigantic mass. The first operation specimen was reported as “benign” at histopathological analysis and immunohistochemical analysis revealed vimentin (+) while it was pancytoceratine (-) (Figure 2). At the second exploration because of the extensive invasion to peripheral tissue, resection was not possible and the mass was reported as “sarcoma”. Both of the patient’s patho-

logical materials were reviewed retrospectively again in our pathology department and another reference hospital. The patient died in the 9th month of her follow up.



**Figure 2.** A, B. Imaging of the compressive gigantic mass. C. The lobulated solid tumor weighed 2.5 kg, measured 20x11x6 cm. D. Monotonous spindle cells in the form of a myxoid stroma without cellular atypia, necrosis and mitosis (HEX200) E. Immunohistochemical vimentin (+) stain.

Another patient was reoperated due to recurrence in 3rd year. The same patient had recurrence suspected to have invasion to surrounding tissue in the 7th year of her follow up and refused any treatment. This recurrence contributed to her death 101 months after the initial operation. Both tumors were larger than 15 cm. in the two patients with recurrence. Other 12 patients were all disease free in their follow up. Patients' demographic data is in Table 1.

## Discussion

Solitary fibrous tumors take place in the literature due to their rarity and the difficulties in both diagnosis and treatment. According to large series majority of the patients are between 40-60 years [3,5]. The major series reported recently are shown in Table 2.

In terms of gender although in our series sex distribution seems to be equal, Guo et al. [3] reported the rate of female/male as 2.25. Median age was 44.6 in the same series where as it was 49.5 in our study group.

Preoperative respiratory function tests might be at the border or lower than expected especially in patients having gigantic solitary fibrous tumors. This condition might be due to the compression of the tumor to the lung, so it should be taken into consideration that the patient might have better postoperative FEV1 results [8].

Thorax CT and if necessary MRI, can be used for diagnosis except for chest X-ray and routine tests [2-4,9]. There is not a definitive radiological sign defined for dif-

**Table 1.** Clinical and pathological features of the 14 patients

Case	Age	Sex	Symptom	Tm.***	Size (cm)	Side of tm.	Tm. Origin aPP, bVP, cB	Follow up (month)	Recurrence (+/-)
1	56	M*	Cough		11	Left	PP	81	-
2	15	F**	Chest pain		20	Left	B	9	+
3	51	F	Chest pain		16	Left	VP	60.5	-
4	46	M	Chest pain SoB****		13	Left	B	93	-
5	59	F	SoB		15	Right	PP	101	+
6	63	M	SoB, sputum		15	Left	VP	26	-
7	46	M	Cough		8	Right	VP	71.5	-
8	68	M	SoB		4	Right	VP	73.5	-
9	42	F	SoB		24	Left	B	10	-
10	37	F	Asymptomatic		6	Right	B	53	-
11	30	M	Asymptomatic		4	Right	VP	14	-
12	70	M	Chest pain		18	Right	VP	40	-
13	48	F	Chest pain		2.5	Right	VP	40	-
14	62	M	Chest pain		7	Right	VP	32.3	-

\*M: male, \*\*F: female, \*\*\*Tm: tumor, \*\*\*\*SoB: Shortness of breath aMP: Mediastinal pleura, bVP: Visceral pleura, cBoth: Both pleura

**Table 2.** Data of the large series from literature

Literature	Number of cases	Sex (male/female)	Median age	Tumour size (cm)	Benign/malignant	Recurrence
Lahon et al.	157	72 / 85	58	9	90 (57%) / 67 (43%)	15 (9.5%)
Harrison-Phipps et al.	84	39 / 45	57	5	73 (87%) / 11 (13%)	8 (9.9%)
Chu et al.	40	17 / 23	48	-	33 (82.5%) / 7 (17.5%)	-
Guo et al.	39	27 / 12	44.6 + 14.5	7.71	35 (89.7%) / 4 (10.3%)	1 (2.6%)
Lu et al.	13	4 / 9	47	10.3	6	2

ferentiating benign and malignant tumors. Nonetheless heterogeneity, mass effect and pleural effusion are more frequent in malignant solitary fibrous tumors [10]. In addition it is reported that positron emission tomography have limited diagnostic value in solitary fibrous tumors [11,12].

It is generally difficult to have a diagnosis at the preoperative period in SFT, most of the patients have their definitive diagnosis at the postoperative period. Orki et al. [13] reported their three patients, two of whom did not have diagnostic findings although their preoperative biopsy. Similarly, Guo et al. [3] reported the limited assistance of preoperative biopsy for the diagnosis, emphasizing the risk of tumor seeding and avoiding unnecessary biopsies [14]. Compatible with the literature, our patients had their definitive histopathological diagnosis with surgical resection [3,6,7,13]. Chu et al. [4], emphasized that puncture biopsy is a valuable tool for diagnosing SFT, and added that the key is obtaining a sufficient amount of biopsy tissue for successful immunohistochemical staining.

Although in our study all patients postoperative pathological evaluation was reported to be benign, it seems that the rate of malignancy mentioned in the literature, is higher than expected. At the study of Lu et al. [2] seven of the cases from 13, were diagnosed to be malignant. Among them, one patient experienced a recurrence and one patient died of brain metastasis. According to data from this study and our study, the behavior of the tumor is more important than it is histopathological analysis such as benign or malignant. A solitary fibrous tumor which is considered to be benign, may show a malignant progress with malignant recurrences. At this point a question comes into mind: whether is it possible to overlook a malignant focus in the large sized tumors at the histopathological evaluation? A correla-

tion between malignancy and tumor size is investigated. However, in our series, six cases having tumors larger than 15 cm. were all reported as benign. In clinical follow up, in two of these cases recurrence and malignancy was detected, and both of them died without having the chance of any intervention. It should be kept in mind that with the tumor size getting bigger the risk of having a malignant focus inside is more possible and the risk of overlook is more conceivably. Although there are studies supporting our data at this point [3], there are also those who argue the opposite [5,7].

In the study of Guo et al. [3] 10.3% of the patients were detected to be malignant from 39. One patient had recurrence at the 6th month of his follow up, but refused further treatment as the case in our study who had recurrence at the 8th month. The rate of malignancy was similar in the series of Harrison-Phipps et al. [5] (13%), and were detected at the ones having malignant solitary fibrous tumors. Ultimately 75% of the patients with malignant SFTs and 25% patients with benign SFTs experienced recurrence. All of them had re-resection. Five year survival rates were statistically different (89% vs 45.5%,  $P = 0.0005$ ). Lahon et al. [7] reported a five year survival rate of 96% in the group with benign SFTs, whereas this rate decreases to 68% in malignant ones ( $P = 0.0003$ ).

In the management of solitary fibrous tumors it is considered to be very important to make a complete surgical resection. To prevent recurrences, getting safe surgical margins with performing a wedge resection for the tumors arising from visceral pleura and associated with lung parenchyma is fundamental [3,9]. It was necessary to perform wedge resection to 12 of the patients in our study. If the tumor grows into the parenchymal tissue lobectomy also might be required [3,4,9].



In conclusion, although solitary fibrous tumors are considered to be benign tumors, it is very important for the surgeons to perform a complete resection to prevent recurrence. Recurrences detected during follow up period seem like as a result of malignant potential. We are in the opinion that, taking into account of this possibility, the objective of the pathologist should be observing the whole material cautiously not to overlook a tumor foci in a side of a gigantic mass. Also based on this possibility, surgeons should follow up their patients for a long time.

### Declaration of conflicting interests

The author declared no conflicts of interest with respect to the authorship and/or publication of this article.

### Funding

The author received no financial support for the research and/or authorship of this article.

### References

1. Shields TW, Yeldandi AV. Localized fibrous tumors of the pleura. In: Shields TW, LoCicero III J, Ponn RB, Rusch VW, eds. *General Thoracic Surgery*. Philadelphia: Lippincot Williams & Wilkins, 2005:889-900.
2. Lu C, Ji Y, Shan F, Guo W, Ding J, Ge D. Solitary fibrous tumor of the pleura: an analysis of 13 cases. *World J Surg* 2008; 32: 1663-8.
3. Guo W, Xiao HL, Jiang YG, Wang RW, Zhao YP, Ma Z, et al. Retrospective analysis for thirty-nine patients with solitary fibrous tumor of pleura and review of the literature. *World J Surg Oncol* 2011; 9: 134-9.
4. Chu X, Zhang L, Xue Z, Ren Z, Sun Y, Wang M, et al. Solitary fibrous tumor of the pleura: An analysis of forty patients. *J Thorac Dis* 2012; 4: 146-154.
5. Harrison-Phipps KM, Nichols FC, Schleck CD, Deschamps C, Cassivi SD, Schipper PH, et al. Solitary fibrous tumors of the pleura: results of surgical treatment and long-term prognosis. *J Thorac Cardiovasc Surg* 2009; 138: 19-25.
6. Orki A, Eryigit H, Akin O, Patlakoglu S, Kosar A, Hacıbrahimoglu G, et al. Plevranın soliter fibröz tümörleri. *Fırat Tıp Dergisi* 2007; 12: 197-200.
7. Lahon B, Mercier O, Fadel E, Ghigna MR, Petkova B, Mussot S, et al. Solitary fibrous tumor of the pleura: outcomes of 157 complete resections in a single center. *Ann Thorac Surg* 2012; 94: 394-400.
8. Furukawa N, Hansky B, Niedermeyer J, Gummert J, Renner A. A silent gigantic solitary fibrous tumor of the pleura: case report. *Journal of Cardiothoracic Surgery* 2011; 6: 122-5.
9. Guo J, Chu X, Sun YE, Zhang L, Zhou N. Giant solitary fibrous tumor of the pleura: an analysis of five patients. *World J Surg* 2010; 34: 2553-7.
10. Walid Abu Arab. Solitary fibrous tumours of the pleura. *Eur J Cardiothorac Surg* 2012; 41: 587-97.
11. Cardinale L, Ardisson F, Garetto I, Marci V, Volpicelli G, Solitro F, et al. Imaging of benign solitary fibrous tumor of the pleura: a pictorial essay. *Rare Tumors* 2010; 2: e1.
12. Ginat DT, Bokhari A, Bhatt S, Dogra V. Imaging features of solitary fibrous tumors. *AJR* 2011; 196: 487-95.
13. Orki A, Keles M, Kosar A, Kiral H, Tezel C, Dudu C, et al. Plevranın soliter (lokalize) fibröz tümörü: üç olgu sunumu. *Turkish J Thorac Cardiovasc Surg* 2003; 11:125-8.
14. Scarsbrook AF, Evans AL, Slade M, Gleeson FV. Recurrent solitary fibrous tumour of the pleura due to tumour seeding following ultrasound-guided transthoracic biopsy. *Clin Radiol* 2005; 60: 130-2.

To cite this article: Video-assisted thoracoscopic removal of esophageal leiomyoma in a patient with aberrant right subclavian artery. Bilgi Z, Dericiođlu O, Ömercikođlu H, Çetinkaya Ç, Batirel HF. Curr Thorac Surg 2017; 2(1): 20-22.

## Case Report

# Video-assisted thoracoscopic removal of esophageal leiomyoma in a patient with aberrant right subclavian artery

Zeynep Bilgi<sup>1a</sup>, Okan Dericiođlu<sup>2</sup>, Hakan Ömercikođlu<sup>3</sup>, Çađatay Çetinkaya<sup>3</sup>, Hasan Fevzi Batirel<sup>3</sup>

<sup>1</sup> Kars Harakani State Hospital, Department of Thoracic Surgery, Kars

<sup>2</sup> Marmara University, Faculty of Medicine, Department of Cardiovascular Surgery, İstanbul

<sup>3</sup> Marmara University, Faculty of Medicine, Department of Thoracic Surgery, İstanbul, Turkey

### ABSTRACT

Esophageal leiomyoma one of the most common esophageal tumors and frequently cause dysphagia, requiring surgical removal for symptom control. Aberrant right subclavian artery may also cause similar symptoms but its incidence is lower. We report a case who had dual pathologies as possible causes of dysphagia. A straightforward bi-portal video-assisted thoracoscopic removal of an esophageal leiomyoma was performed in a patient with an aberrant right subclavian artery coursing posterosuperior to the leiomyoma.

**Key Words:** Esophagus, leiomyoma, VATS, aberrant right subclavian artery

---

Corresponding Author<sup>®</sup>: Zeynep Bilgi, MD, Marmara University, School of Medicine, Department of Thoracic Surgery, İstanbul, TURKEY.

E-mail: zeynep.bilgi@gmail.com

Received 15.05.2016 accepted 19.08.2016

## Introduction

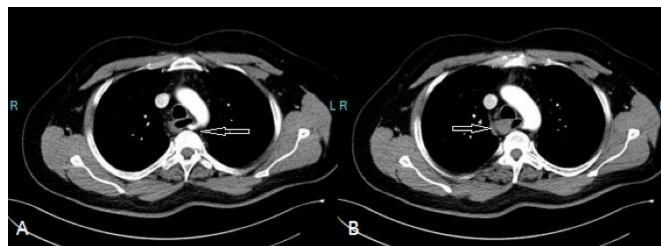
Esophageal leiomyoma is the most common benign esophageal tumor, representing 70% of all benign esophageal tumors. Most esophageal leiomyomas are usually slow growing and only discovered incidentally or when they cause symptoms due to their size. Most common symptoms are dysphagia, heartburn and regurgitation. For incidentally discovered leiomyomas, conservative treatment may be considered while if the size larger than 5 cm, progression or suspicion of malignancy warrant surgical treatment [1]. Video-assisted thoracoscopic (VATS) enucleation approach has been reported with very encouraging results, reducing the pain and discomfort due to thoracotomy. Our approach was done with the patient in lateral decubitus position, but excellent results with prone positioning were also published [2,3].

Aberrant right subclavian artery (ARSA) is one of the rare reasons for dysphagia. In 80% of the cases it runs posterior to the esophagus to connect to aorta distal to the left subclavian artery and may cause catastrophic complications if unrecognized before surgical interventions in close proximity [4]. The recurrent laryngeal nerve also has an abnormal course in cases of aberrant right subclavian artery, branching from vagus, entering directly to larynx.

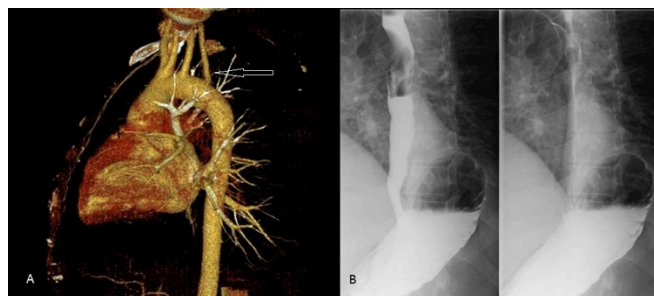
In this article, we report the coincidence of an esophageal leiomyoma and an ARSA in a patient who presented to our clinic with dysphagia.

## Case Report

The patient was a 39 year old gentleman who was referred to our clinic for work up of dysphagia for two months. Endoscopy revealed an extraluminal mass partially obstructing the passage, endoscopic ultrasound was highly characteristic of an esophageal leiomyoma but a tissue diagnosis couldn't be reached through biopsies. A computerized tomography of the chest with intravenous contrast showed an aberrant right subclavian artery running posterior to esophagus in close proximity to the lobular esophageal mass (Figure 1). In terms of deciding the dominant reason for dysphagia, a barium swallow was performed, which showed bulging extraluminal mass causing an incomplete obstruction of the passage (Figure 2).



**Figure 1.** Contrast computerized tomography slices showing A. ARSA (black arrow) and B. esophageal leiomyoma (black arrow).



**Figure 2.** A. 3-D reconstruction of vascular anatomy showing ARSA, B. Barium swallow showing bulging extraluminal mass, lateral and right oblique views.

The patient underwent a bi-portal (4th and 6th intercostal space, anterior axillary line) VATS enucleation of the leiomyoma in left lateral decubitus position. Dividing the azygous vein and a 3 cm myotomy was required to gain necessary exposure for safe removal of the tumor. The myotomy site was on the right lateral wall of the esophagus for careful avoidance of the ARSA. The myotomy was closed with three 2-0 absorbable sutures. The patient had an uneventful intra- and postoperative course and was discharged on 3rd postoperative day. He was maintained on a soft diet for 2 weeks and can consume a normal diet on 1st month of follow up, without any symptoms.

## Discussion

Clinical evaluation of dysphagia requires careful consideration and can involve multiple diagnostic studies to delineate a causative factor. In this case, we present a first in the literature, a patient with two probable factors for dysphagia, a large leiomyoma and a right aberrant subclavian artery. In terms of selecting an approach, a barium swallow study showing a real time passage of bolus and leiomyoma's impact helped us to determine the leiomyoma as the main causative factor. During the surgery, preoperative awareness of the ARSA was important for preventing an intraoperative unexpected complication [4].

In cases of mucosal rupture during stripping of the tumor, simple suturation is usually enough for leak control. In our case, we did not encounter any mucosal rupture, but placed sutures anyway, with the rationale of restoring the anatomy and the blood supply.

Endoscopic ultrasound is fairly specific for diagnosis of esophageal leiomyoma and is also confirmed by pathology results in larger case series. Biopsy is also proven to be safe in cases of submucosal tumors, but has little value for changing the clinical decision making if the resection is to be done for symptomatic purposes (dysphagia) [6,7].

VATS enucleation of esophageal leiomyoma has been reported in large case series and results have been more favorable than thoracotomy [5]. In our case, VATS approach did not cause any problems regarding the dissection and visual exposure even in this case with complicated anatomy. In regards to VATS approach, we preferred a lateral decubitus positioning as exposure of anatomy is more familiar in this position. Prone positioning is also used successfully by other authors [4].

#### **Declaration of conflicting interests**

The author declared no conflicts of interest with respect to the authorship and/or publication of this article.

#### **Funding**

The author received no financial support for the research and/or authorship of this article.

#### **References**

1. Lee LS, Singhal S, Brinster CJ, Marshall B, Kochman ML, Kaiser LR, et al. Current management of esophageal leiomyoma. *J Am Coll Surg* 2004; 198: 136-46.
2. Samphire J, Naftoux P, Luketich J. Minimally invasive techniques for resection of benign esophageal tumors. *Semin Thorac Cardiovasc Surg* 2003; 15: 35-43.
3. Claus CM, Cury Filho AM, Boscardim PC, Andriguetto PC, Loureiro MP, Bonin EA. Thoracoscopic enucleation of esophageal leiomyoma in prone position and single lumen endotracheal intubation. *Surg Endosc* 2013; 27: 3364-9.
4. Pantvaitya GH, Mistry RC, Ghanekar VR, Upasani VV, Pramesh CS. Injury of an aberrant subclavian artery: a rare complication of video assisted thoracoscopic esophagectomy. *Thorac Cardiovasc Surg* 2005; 11: 35-7.
5. Shin S, Choi YS, Shim YM, Kim HK, Kim K, Kim J. Enucleation of esophageal submucosal tumors: a single institution's experience. *Ann Thorac Surg* 2014; 97: 454-9.
6. Wang YX, Zhang J, Liu Y, Liu Y, Chu XY, Lu ZS, et al. Diagnosis and comprehensive treatment of esophageal leiomyoma: clinical analysis of 77 patients. *Int J Clin Exp Med* 2015; 8: 17214-20.
7. Tae HJ, Lee HL, Lee KN, Jun DW, Lee OY, Han DS, et al. Deep biopsy via endoscopic submucosal dissection in upper gastrointestinal subepithelial tumors: a prospective study. *Endoscopy* 2014; 46: 845-50.

To cite this article: Isolated giant chest wall metastasis of papillary thyroid carcinoma; case report. Karapınar K, Kocatürk Cİ, Kutluk AC, Ören N. Curr Thorac Surg 2017; 2(1): 23-26.

## Case Report

# Isolated giant chest wall metastasis of papillary thyroid carcinoma; case report

Kemal Karapınar<sup>1a</sup>, Celalettin İbrahim Kocatürk<sup>1</sup>, Ali Cevat Kutluk<sup>1</sup>, Nural Ören<sup>2</sup>

<sup>1</sup>Yedikule Teaching Hospital for Chest Diseases and Thoracic Surgery, Department of Thoracic Surgery, Istanbul

<sup>2</sup>Yedikule Teaching Hospital for Chest Diseases and Thoracic Surgery, Department of Pathology, Istanbul, Turkey.

### ABSTRACT

Pulmonary metastases of papillary thyroid carcinoma (PTC) is rare and generally present as a micronodular or a miliary pattern. Herein we present a single giant chest wall metastasis of PTC that caused mediastinal shift which was not reported in the literature. A 67 year old female patient admitted to the hospital due to shortness of breath. A right sided mass on the chest wall and thyroid nodules were detected. PTC was diagnosed and the patient underwent a total thyroidectomy. pT3N0 were evaluated postoperatively. PET-CT demonstrated the mass at right hemithorax (12 cm lesion, SUV max=7.2) plus needle biopsy showed a metastasis of PTC. A chest wall resection plus right upper lobectomy and lymph node dissection was performed as the first choice for PTC metastasis.

**Key Words:** papillary thyroid carcinoma, chest wall, metastasis, giant, dyspnea

---

Corresponding Author<sup>a</sup>: Kemal Karapınar, MD. Yedikule Göğüs Hastalıkları ve Göğüs Cerrahisi Eğitim ve Araştırma Hastanesi, 1. Cerrahi servisi, Kazlıçeşme Belgrad kapı yolu No:1, 34020, Zeytinburnu, İstanbul, Turkey  
E-mail: kemalkarapinar55@gmail.com

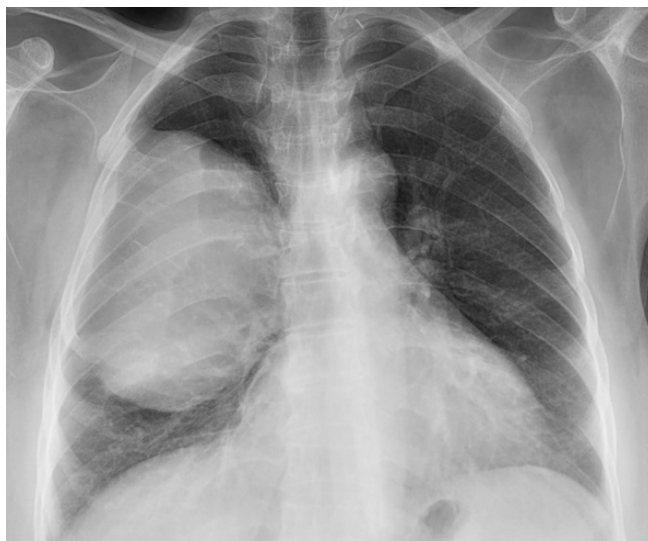Received 14.11.2016 accepted 03.01.2017

## Introduction

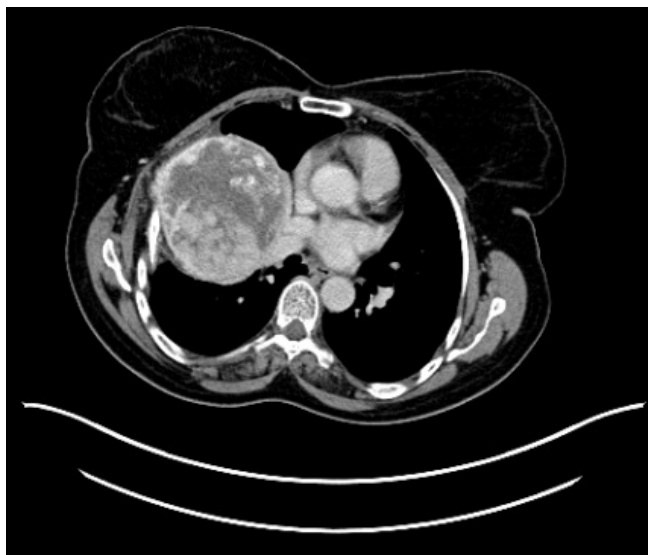
Cancer from almost every organ in the body can metastasize to the lung such as colon, pancreas and breast carcinoma. Metastatic lung nodules can be found alone or in groups [1]. Pulmonary metastases of papillary thyroid carcinoma (PTC) is rare and usually has a micronodular or miliary pattern [2]. In this article, we report a case which presented with a single giant chest wall metastasis that arose from PTC and causing a mediastinal shift.

## Case Report

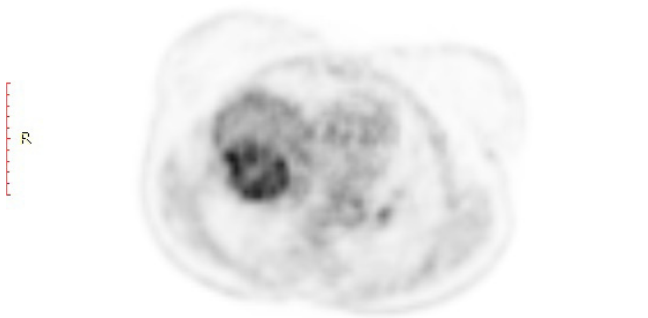
Sixteen months ago, a 67-year-old female patient, applied to another hospital due to shortness of breath. A mass at the right hemithorax was found as a result of investigations. Diagnostic transthoracic needle aspiration was performed without providing a diagnosis. Positron emission Tomography (PET-CT) was performed due to the suspicion of malignancy. A mass filling 60% of the right hemithorax (SUV max 5.4) and a nodule in the left thyroid lobe (SUV max 6.0) were found. Histopathologic diagnosis from the biopsy of the thyroid nodule revealed the presence of PTC and treatment options were discussed in a multidisciplinary council and thyroid surgery was planned. The final pathological results of patients who underwent total thyroidectomy confirmed PTC without a capsular invasion (pT3N0). No other additional treatment options for the thyroid lesion were presented at the same council. A thoracic surgical intervention for the chest wall mass was refused by the family. The patient was referred to our hospital. The patient's posteroanterior (PA) chest x-ray and chest computed tomography showed a thoracic mass with chest wall invasion (Figures 1, 2). The lesion - measured approximately 12 cm in diameter - caused a mediastinal shift, and a rare calcifications were detected. Needle biopsy from the mass confirmed the diagnosis of papillary thyroid carcinoma metastasis. Cranial MRI showed no brain metastasis. A new PET/CT showed a higher SUV max as 7.2 compared to the previous study without any distant organ metastasis (Figure 3).



**Figure 1.** Preoperative chest x-ray showing a giant mass at right hemithorax.

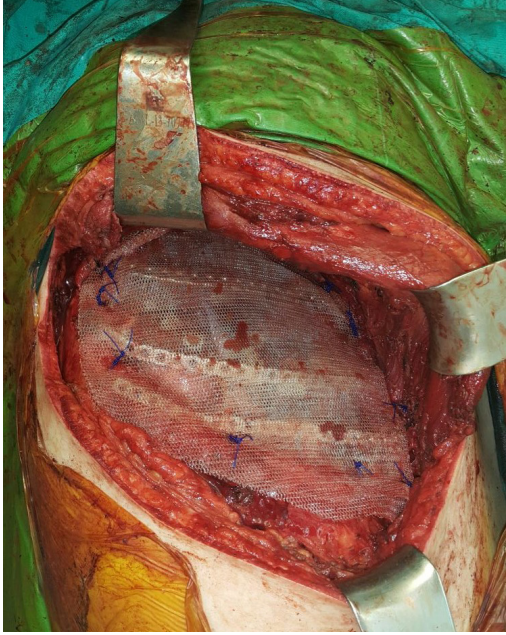

**Figure 2.** Chest computed tomography showing the mass invading the chest wall.



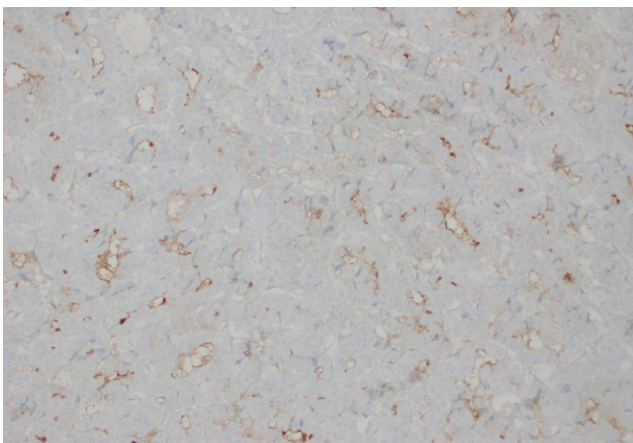
**Figure 3.** PET-CT showing the malign FGD uptake (SUV max 7.2).

The mass (12.5x10x6.5 cm) was totally excised with partial resection of the invaded right 2nd, 3rd, 4th, and 5th ribs. A lobectomy due to parenchymal destruction and lymph node dissection (4th, 7th, 9th, 10th, and 11th lymph nodes) was also performed. The large chest wall defect was closed using 3 titanium bars and a proline mesh (Figure 4). There were no complications from the procedure and the patient was discharged at day 5 uneventfully.

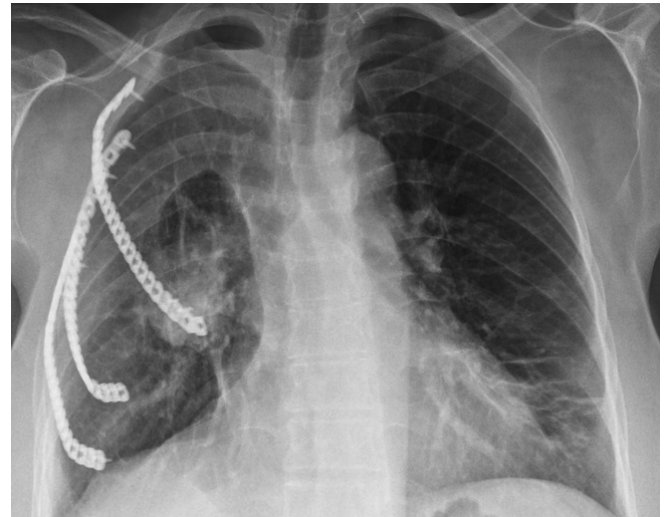

**Figure 4.** Titanium bars with proline mesh for the chest wall stability

The final histopathological examination confirmed the diagnosis of PTC metastasis. The surgical margins was clear and, lung parenchyma and lymph nodes did not show any evidence of tumor cells. The diagnosis was supported by immunostaining (Thyroglobulin (CM022C) and HB -1 was positive) (Figure 5). Radioactive iodine (I131) was provided as an additional treatment to the patient. At the 8th month control no recurrences was seen (Figure 6).



**Figure 5.** Pathological examination: immunostaining (Thyroglobulin (CM022C) positive, the HB -1 positive)



**Figure 6.** Postoperative chest X-ray at 8th month control.

## Discussion

Thyroid cancer constitutes 1% of all cancers [3]. The incidence of thyroid cancer is 5.5 to 6.6%, and is the fastest growing type of malignancy in both sexes. Ten year survival is 98% after surgery for PTC. However recurrence of thyroid cancer is most commonly seen with the this subtype [4]. Recurrence after surgery was reported as 24% [5] at a Tubiana study. Therefore, close follow-up of patients was recommended.

Bone metastases with the follicular type and PTC occur 7-20% and 1-7% of the cases respectively. Medical drugs (analgesics, bisphosphonates), radiotherapy, surgery and radioisotopes are used in a multidisciplinary approach for the treatment of thyroid metastasis. I131 is an effective treatment modality for treatment of thyroid cancer with bone metastasis however resistance is frequently observed. Surgical treatment is indicated when patients present with intractable pain, lesions are unresponsive to medical therapy, there is low radioactive involvement, or present with spinal instability [6]. While the first option in the treatment of metastases is usually I131 therapy, we suggested surgery as a more viable option because of complaints of dyspnea, the presence of a mediastinal shift, and compression of the mass in our case. However, we did use I131 in the post-operative treatment of our patient.

A literature search was carried out in 'PubMed' and 'ResearchGate' using the following keywords: papillary thyroid carcinoma, chest wall and metastasis. Four studies were found that resemble to our current case. Kaya and Çermik [7] reported a case with diagnosis of papillary carcinoma metastasis who underwent surgery

but died due to multiple new metastases. In the present case, a metastatic lesion was also detected first, but it was quite large and single so we anticipated that it would have a relatively good prognosis. In the second case in the literature, presented by Li et al. [8] a chest wall surgery was performed using endoscopic thyroid surgery with metastasis to the sternocleidomastoid muscle. Our patient had distant metastases independent of the remote operation. Nakada et al. [9] presented the third case. After PTCs, the sternal metastases became resistance to radioactive iodine therapy; therefore, percutaneous ethanol injection (PEI) therapy was successfully performed. In our case, many of the unknown effects of PEI on dyspnea and due to the emergency situation caused by the mediastinal shift, ‘surgery’ was considered as the first choice of treatment. Karamustafaoğlu et al. [10] presented the fourth case report having similarities to our case. In this series of 4 patients, 3 patients presented PTC and one diagnosed as medullary thyroid carcinoma. Three patients who underwent chest wall resection died due to distant metastasis between 5 to 36 months, but one PTC case was still alive at 5th year follow-up. We closely monitored our patient up to the 8th month because of recurrence rate.

As a conclusion and take home message papillary thyroid carcinoma should be closely monitored after surgery, even if the malignant potential of thyroid carcinoma is low. For the treatment of metastases radioactive iodine treatment, as the first choice, should be kept in mind however when a resistance is faced surgical treatment could be performed. In the cases with a mediastinal shift and dyspnea caused by a resectable tumor, surgery should be considered as the first choice.

### **Declaration of conflicting interests**

The author declared no conflicts of interest with respect to the authorship and/or publication of this article.

### **Funding**

The author received no financial support for the research and/or authorship of this article.

### **References**

1. Stern EJ, Swensen SJ, Kanne JP. High-resolution CT of the Chest, 3rd Ed: Wolters Kluwer, Philadelphia PA; 2010.
2. Kaseda K , Watanabe K , Sakamaki H, Kazama A. Solitary pulmonary metastasis from occult papillary thyroid carcinoma. *Thoracic Cancer* 2016; 7: 261-3.
3. Sherma SI. Thyroid carcinoma. *The Lancet* 2003; 361: 501-11.
4. Kim M, Ladenson PW: Thyroid. In: Goldman L, Schafer AI (eds). *Goldman-Cecil Medicine*, 25th Ed. Philadelphia PA: Elseiver; 2016:1513.
5. Tubiana M, Schlumberger M, Rougier P, Laplanche A, Benhamou E, Gardet P, et al. Long-term results and prognostic factors in patient with differentiated thyroid carcinoma. *Cancer* 1985; 55: 794-804.
6. Muresan MM, Olivier P, Leclère J, Sirveaux F, Brunaud L, Klein M, et al. Bone metastases from differentiated thyroid carcinoma. *Endocr Relat Cancer* 2008; 15: 37-49.
7. Kaya M, Cermik TF. Tc-99m MIBI scintigraphy in tall cell variant of papillary thyroid carcinoma with negative radioiodine scan. *Clin Nucl Med* 2008; 33: 615-8.
8. Li S, Zhang F, Zhang Y, Liang Y, Qi X, Yang X, Jiang J. Implantation at sternocleidomastoid and chest wall after endoscopic thyroid carcinoma surgery. *Surg Laparosc Endosc Percutan Tech* 2012; 22: 239-42.
9. Nakada K, Kasai K, Watanabe Y, Katoh C, Kanegae K, Tsukamoto E, et al. Treatment of radioiodine-negative bone metastasis from papillary thyroid carcinoma with percutaneous ethanol injection therapy. *Ann Nucl Med* 1996; 10: 441-4.
10. Karamustafaoğlu YA, Yoruk Y, Angın G, Tarladacalısır T, Mammedov R. Chest Wall Distant Metastases of Thyroid Carcinoma. *Trakya Univ Tip Fak Derg* 2009; 26: 338-341.



To cite this article: A giant mediastinal ectopic goiter causing dyspnea and dysphagia. Kutluk AC, Seyrek Y, Kocatürk CI, Bedirhan MA. Curr Thorac Surg 2017; 2(1): 27-29.

## Case Report

# A giant mediastinal ectopic goiter causing dyspnea and dysphagia

Ali Cevat Kutluk<sup>a</sup>, Yunus Seyrek, Celalettin İbrahim Kocatürk, Mehmet Ali Bedirhan

Yedikule Teaching Hospital for Chest Diseases and Thoracic Surgery, Department of Thoracic Surgery, Istanbul, Turkey

### ABSTRACT

Primary mediastinal ectopic goiter (PMG) is defined as the presence of thyroid tissue in the mediastinum without having a continuity between the cervical thyroid and the mediastinal goiter. A fifty-seven year-old man admitted to our clinic suffering from dyspnea, chest pain, shortness of breath, and dysphagia for almost two months. Thorax computed tomography revealed a mass of 12 cm in the posterior mediastinum, compressing the trachea and esophagus. The mass is resected completely via a right thoracotomy.

**Key Words:** Ectopic goiter, mediastinum, dyspnea

---

Corresponding Author<sup>a</sup>: Ali Cevat Kutluk, Yedikule Göğüs Hastalıkları ve Göğüs Cerrahisi Hastanesi, İstanbul, Turkey.

E-mail: dralikutluk@gmail.com

Received 27.07.2016 accepted 18.11.2016

This case was presented as "Ectopic thyroid tissue causing tracheal shift" (EP-226) in the thirty sixth TUSAD congress.

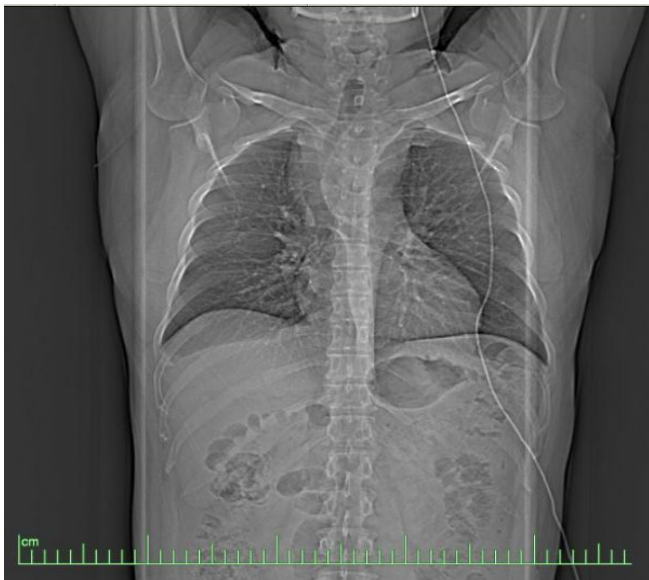
## Introduction

Primary mediastinal ectopic goiter (PMG) is briefly defined as the presence of thyroid tissue in the mediastinum; but there are actually four criteria to call a mediastinal thyroid tissue as PMG. There should be a total discontinuity between the cervical thyroid and the mediastinal goiter, presence of blood supply should be from mediastinal vessels, there should be absence of history or evidence of malignancy in both cervical and mediastinal goiter and finally the cervical thyroid gland can be present or absent with no history of thyroidectomy [1]. It constitutes 1% of all mediastinal masses. PMG usually presents itself by causing compression of adjacent structures leading to dysphagia, hoarseness, stridor and symptoms of vena cava superior syndrome [2,3]. Surgical resection is the gold standard for the treatment of PMG.

Our aim is to share this rare case and remind that PMG should not be forgotten in differential diagnoses in mediastinal masses.

## Case Report

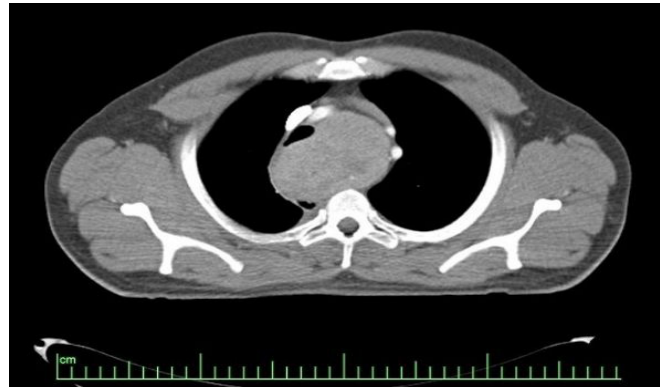
A 57-year-old male patient was referred to our clinic due to dry cough, chest pain, shortness of breath, dyspnea, and dysphagia for three months. Chest X-ray presented a mediastinal widening and a right tracheal deviation (Figure 1).



**Figure 1.** Chest X-ray demonstrating the widening of the mediastinum and deviation of the trachea.

A tracheal shift was evident by palpation during the physical examination. Thorax computerized tomography (CT) revealed a 12x10 cm heterogeneous mass which was located in posterior trachea, adjacent to anterior

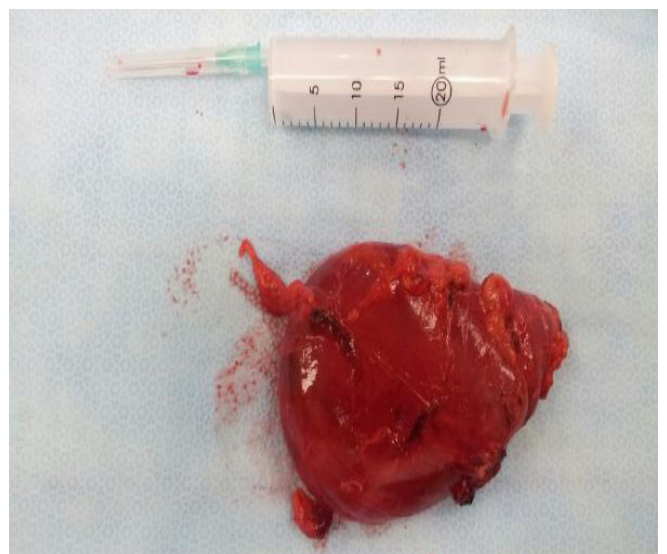vertebral column and compressing the esophagus. (Figure 2). Thyroid ultrasonography was normal.



**Figure 2.** Thorax CT demonstrating the mass in the mediastinum compressing and deviating the trachea and esophagus.

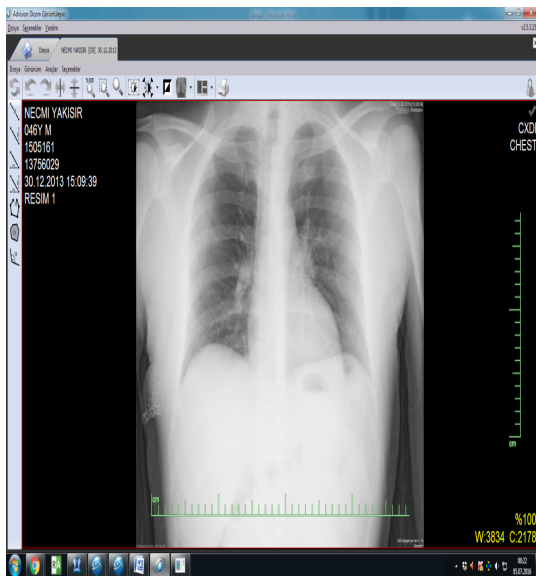
He did not have a thyroid operation previously. Routine laboratory tests including thyroid function tests, beta-human chorionic gonadotropin (B-hcg, 0 mIU/ml), alpha-fetoprotein ( $\alpha$ FP, 2.2ng/ mL) and lactate dehydrogenase (LDH, 2,2 U/L) were all in normal ranges. Fiberoptic bronchoscopy revealed a severe external compression trachea.

A right lateral thoracotomy is preferred to accomplish a reliable exposure for a posterior mass resection. The mass had no invasions to the adjacent organs and structures and it is resected completely (Figure 3). Histopathologic examination reported macrofollicular nodular colloid hyperplasia. Figure 4 shows the postoperative chest x-ray.



**Figure 3.** Pathologic specimen

Postoperative course was uneventful and he is under follow-up and disease free for 3 years.



**Figure 4.** Chest X-ray after surgery

## Discussion

Ectopic localization of thyroid tissue is a congenital anomaly which constitutes 1% of all mediastinal masses. Ectopic thyroid tissue may occur in any point along the pathway of migration of primordial thyroid gland from foramen caecum to its final destination, anterior trachea between fourth and eighth week of gestation [2,4]. The anterior mediastinum makes up 75-94% of the localization, while in 10-15% of the cases, they occur in the posterior mediastinum.

PMG usually seen in 4th or 5th decades and there is a female preponderance [5]. Although patients are usually asymptomatic and incidentally identified, they may present with symptoms of compression of adjacent organs. Thoracic CT is very sensitive to delineate the nature of the mediastinal masses and their relation to adjacent thoracic structures. Iodine-131 scanning which is used to detect the thyroid tissue in the mediastinal masses, is performed both to investigate the thyroid nature of the mass and to prove that the mass had no relation to cervical thyroid gland.

Thoracic MRI can also be used in addition to thorax CT to plan the surgical approach [6].  $\beta$ HCG,  $\alpha$ FP and LDH levels are essential in the differential diagnosis to distinguish nonseminomatous germ cell tumors from other mediastinal masses. The mass showed a heterogeneous density on CT. Thyroid function tests and  $\beta$ HCG and  $\alpha$ FP levels were all normal.

Surgical approach depends on the location of the mass. Median sternotomy, thoracotomy, cervical inci-

sion, and thoracoscopy are surgical approaches of PMG resection. In this case we preferred a right lateral thoracotomy due to the localization. The patient was completely symptom free after the resection. After a long term tracheal compression, a postoperative tracheomalacia is a rare but expected complication which was not seen in this case.

In conclusion, this case emphasizes that PMG is a part of differential diagnoses for mediastinal masses despite to its rareness. Thoracotomy is the most common approach to resect mediastinal masses which are greater than 4 centimeter.

## Declaration of conflicting interests

The author declared no conflicts of interest with respect to the authorship and/or publication of this article.

## Funding

The author received no financial support for the research and/or authorship of this article.

## References

1. Foroulis CN, Rammos KS, Sileli MN, Papakonstantinou C. Thyroid 2009; 19: 213-8.
2. Sakorafas GH, Vlachos A, Tolumis G, Kassaras GA, Anagnostopoulos GK, Gorgogiannis D. Ectopic intrathoracic thyroid: case report. Mt Sinai J Med 2004; 71: 131-3.
3. Mussak EN, Kacker A. Surgical and medical management of midline ectopic thyroid. Otolaryngol Head Neck Surg 2007; 136: 870-2.
4. Noussios G, Anagnostis P, Goulis DG, Lappas D, Natsis K. Ectopic thyroid tissue: anatomical, clinical, and surgical implications of a rare entity. Eur J Endocrinol 2011; 165: 375-82.
5. Sand J, Pehkonen E, Mattila J, Seppanene S, Salmi J. Pulsating mass at the sternum. A primary carcinoma of ectopic mediastinal thyroid. J Thorac Cardiovasc Surg 1996; 112: 833-5.
6. El Oueriachi F, El Hammoum MM, Arsalane A, Slaoui O, Dioouri H, Kabiri EH. Primary mediastinal goiters. Springerplus 2014; 3: 503.
7. Toso A, Colombani F, Averono G, Aluffi P, Pia F. Lingual thyroid causing dysphagia and dyspnoea. Case reports and review of the literature. Acta Otorhinolaryngol Ital 2009; 29: 213-7.

Review Article

## Endobronchial coils – therapeutic innovations for severe emphysema

Martin Hetzel<sup>a</sup>

Clinic of Pneumology, Internal Medicine Intensive Care, Respiratory Medicine and General Internal Medicine, Stuttgart, Germany

### ABSTRACT

Emphysema is a frequent phenotypic manifestation of chronic obstructive pulmonary diseases which does not respond to pharmacotherapy. Interventional methods can provide relief for severely ill and highly symptomatic emphysema patients. A quite well studied endoscopic method is the minimally invasive, non-surgical procedure with coils. Coils are small, shape-memory Nitinol implants designed to gather and compress lung tissue, re-tension the diseased airway network and increase the elastic recoil in the emphysematous lung. To date, the positive benefit-risk ratio of coils is documented by several well-designed randomized clinical trials.

**Keywords:** obstructive pulmonary disease, emphysema, volume reduction, endobronchial coils

---

Corresponding Author<sup>®</sup>: Martin Hetzel, MD. Clinic of Pneumology, Internal Medicine Intensive Care, Respiratory Medicine and General Internal Medicine, Krankenhaus vom Roten Kreuz Bad Cannstatt GmbH, Badstraße 35-37, 70372 Stuttgart, Germany.  
E-mail: Martin.Hetzel@Sana.de

Received 05.09.2016 accepted 16.11.2016

## Introduction

Chronic obstructive pulmonary disease (COPD) is an increasing cause of mortality worldwide. Its prevalence, morbidity and mortality vary across countries. Often, the prevalence of COPD is directly related to the prevalence of tobacco smoking, although in many countries, outdoor, occupational exposures and indoor air pollution are major COPD risk factors [1].

## Emphysema

COPD is characterized by persistent airflow limitation that is usually progressive and associated with an enhanced chronic inflammatory response in the airways and the lung to noxious particles or gases [1]. Two clinically relevant phenotypes exist: chronic obstructive bronchitis/bronchiolitis and emphysema. The chronic inflammation causes structural changes, destruction of parenchyma and narrowing of the small airways [1]. Alveolar attachments are destroyed and abnormal enlargement of air spaces distal to the terminal bronchioles occur, which are typical for emphysema. As a result, the gas exchange surface is reduced and lung elastic recoil decreases. Due to the decreased elastic properties of the lung tissue, small airways collapse during expiration which can cause irreversible hyperinflation [1].

Hyperinflation is described by residual volume, emphysema is diagnosed in radiology. Computed tomography (CT) is a sensitive technique for the detection of emphysema [2]. Functional tests alone are insufficient to quantify the extent of parenchymal loss. However, measurement of diffusion capacity can provide information on the functional impact of emphysema and is often helpful for patients with breathlessness that may seem out of proportion with the degree of airflow limitation [1].

Emphysema is a frequent phenotypic manifestation of COPD which does not respond to pharmacotherapy. Apart from that, many patients suffering from emphysema show at least a certain degree of inflammation, which should be treated with adequate medication [1]. Patients with emphysema commonly suffer from dyspnea [3], which can affect all aspects of everyday life.

## Surgical and interventional therapy

Interventional methods can provide relief for severely ill and highly symptomatic emphysema patients. To date, several therapy options exist. The first method to reduce lung volume in patients with severe emphysema was lung volume reduction surgery (LVRS) [4]. Referring to the NETT trial, LVRS yields a survival advantage for patients with both predominantly upper-

lobe emphysema and low base-line exercise capacity. Apart from that, variable impact on mortality using this technique was reported [5]. The demand has led to the development of therapeutic approaches applying endoscopy, i. e. endoscopic lung volume reduction (ELVR).

## Endobronchial coils – new therapeutic options for severe emphysema

A quite well studied endoscopic method is the minimally invasive, non-surgical procedure with coils [6-13]. Coils are small, shape-memory Nitinol implants designed to gather and compress lung tissue, re-tension the diseased airway network and increase the elastic recoil in the emphysematous lung. The re-tensioning effects of the coils may also tether small airways open, helping to prevent airway collapse during exhalation. Coils are applied bilaterally in two interventions. Currently, two first-in-man studies [6,7], three feasibility trials [8-10] and one published randomized controlled (RCT) pivotal [12] study confirm the benefit of the technology for patients with severe emphysema.

## First-in-man and feasibility trials with coils

The first first-in-man trial was published by Felix Herth and colleagues in 2010 [6]. 11 patients with severe emphysema underwent 21 procedures. Per procedure  $4.9 \pm 0.6$  coils were placed. During the total follow-up time of 7 – 11 months 33 adverse events were reported, none of them severe. No pneumothorax occurred. The authors concluded that endoscopic lung volume reduction with coils was safe and feasible.

A second first-in-man trial by Dirk-Jan Slebos and colleagues was published in 2012 [7]. 16 patients with severe heterogeneous emphysema were included. Four patients were treated in one lung, 12 were treated bilaterally. 6 months after treatment, significant effects were observed: SGRQ total score improved by 14.9 points, FEV1 by 14.9% and 6-minute walking distance (6MWD) by 84.4 m. All results were significant ( $P < 0.005$ ). Observed adverse events within the first 30 days after intervention were 1 pneumothorax, 2 cases of pneumonia, 6 COPD exacerbations, 4 cases of chest pain and 21 cases of mild hemoptysis ( $< 5\text{mL}$ ). Authors concluded that treatment with coils was a promising technique for treatment of patients with severe heterogeneous emphysema resulting in significant improvements in pulmonary function, exercise capacity and quality of life, with an acceptable safety profile.

The RESET trial [7] by Pallav Shah and colleagues was the first randomized controlled trial with coils in

advanced stage of emphysema, published in 2013. 23 patients with severe emphysema were treated with coils and compared to a control group of 23 patients treated with conservative therapy. After 3 months, significant improvements were observed in the treatment group: FEV1 increased by 14.19%, compared to 3.57% in the control group (P = 0.03). The 6MWD was 51.15 m longer in the treatment group, compared to a decline by 12.39 m in the control group (P < 0.001). RV improved significantly as well. Complications were rare cases of exacerbations, pulmonary infection and pneumothoraces. No significant differences between the treatment group and the control group were observed concerning serious adverse events.

Karin Klooster and colleagues published a feasibility trial in patients with homogeneous emphysema in 2014 [10]. The study included 10 patients, who were treated bilaterally. The primary endpoint of the study was the improvement in 6MWT. At 6 months, 6MWD had improved from 289 to 350 m. FVC, RV and SGRQ total score had significantly improved as well. The study showed, that the benefit of coil treatment is not limited to patients with heterogeneous emphysema, and in contrast to other ELVR-methods patients with homogeneous emphysema can benefit as well.

First long-term data were published by Gaetan Deslee and colleagues in 2014 [9]. 60 patients with severe bilateral heterogeneous emphysema were treated in 11 centers and followed for up to one year. The primary endpoint of the feasibility study was the improvement from SGRQ at 6 months. At 6 and 12 months the mean improvements in SGRQ were 12.1 and 11.1 points, mean improvements in 6MWD were 29.7 and 51.4 m. FEV1 improved by mean 0.11 and 0.11 L and RV declined by mean 0.65 and 0.71 L, respectively. All results were significant (P < 0.01). Post hoc analysis showed significant responses for SGRQ, 6MWT and RV in patients with both heterogeneous and homogeneous emphysema.

To date, the longest follow-up term was observed over a period of 3 years, in 22 Dutch patients. The study confirms the long-term effect of the coils. Clinically relevant improvements were shown to remain, with 40% of the patients reaching the 6MWD minimal important difference, and 59% reaching the SGRQ minimal important difference, respectively [11].

**Pivotal trials with coils**

The REVOLENS trial [12] by Gaetan Deslee was published in January 2016. 100 patients were enrolled in

10 sites throughout France. The randomized controlled study was funded by the French Ministry of Health. Patients suffered from severe emphysema and represented a broad range of patients in clinical practice. The primary endpoint was improvement of at least 54 m in the 6MWT at 6 months, which is nearly twice the minimal clinically important difference for this test [14]. It was reached by 18 patients (36%) in the coil group and by 9 (18%) patients in the usual care group. After 6 months FEV1 had improved by 9% in the treatment group compared to a decline by 3% in the control group with similar results after 12 months; 8% improvement in the treatment group, 3 % decline in the control group. After 6 months SGRQ had improved by a mean of 11.1 points in the treatment group compared to a mean decline by 2.3 points in the usual care group. After 12 months the improvement in SGRQ in the coil group was mean 9.1 points, compared to a mean decline by 1.5 points in the control group. The most frequent serious adverse event was pneumonia. The magnitude and severity of adverse events were consistent with previous coil studies.

The RENEW trial [13] is the first randomized controlled pivotal trial including patients with homogenous emphysema as well and conducted to support FDA approval. 315 patients took part in the study. The primary endpoint is the mean improvement of 6MWT after 12 months. Secondary endpoints are e. g. changes of FEV1 and SGRQ. As announced recently, all primary and secondary endpoints could be reached. The between-group differences of 6MWD, SGRQ and FEV1 after 12 months were 10.2 m, 8.9 points and 8.8%. The observed adverse events corresponded to the expected safety profile. Pneumothoraces, inflammation of the lower respiratory tract, respiratory insufficiency, hemoptysis, exacerbations and dyspnea were observed more frequently in the treatment group. The data is expected to be published soon. For an overview of randomized controlled trials with coils see Table 1.

**Table 1.** Overview of results in RCTs with coils compared to the control group

Trial	N	Follow-up (months)	6MWT (m)	SGRQ (points)	FEV1 (%)	RV (L)
RESET (8)	46	3	+63.55*	-8.36*	+10.62*	-0.31
REVOLENS (12)	100	12	+21	-10.6*	+11*	-0.36*
RENEW (13)	315	12	+10.2*	-8.9*	+8.8*	n.a.

\* result statistically significant  
6 MWT, 6-minute walk test; SGRQ, Saint George's Respiratory Questionnaire; FEV1, forced expiratory volume in 1 s; RV, residual volume

### Ongoing trials

A European register study of patients with severe homogeneous and heterogeneous emphysema is currently ongoing and has been recruiting since 2013. 1,250 patients and more than 50 participating centers evaluate patient experiences and collect additional data on the safety and effectiveness of a therapy with coils. It is the largest study for interventional therapy methods in emphysema. The primary objective is a change in SGRQ. Secondary objectives are changes in 6MWD, RV, FEV1 and safety.

### Coils – data correspond to clinical practice

All primary endpoints in feasibility and pivotal trials were reached in a statistically significant way. The majority of endpoints were clinically relevant for patients. For minimal clinically important differences of the parameters used in the REVOLENS trial [12], see Table 2. Additionally, the existing data show several advantages of the coils. The method is independent of collateral ventilation [7], which is seen in the majority of patients in clinical practice [15]. Additionally it has been proven to be effective in patients with homogeneous as well as

heterogeneous emphysema [9,10]. In clinical practice nearly one third of patients show a heterogeneous pattern [16]. This is in contrast to other ELVR-methods.

**Table 2.** Minimal clinically important differences used in REVOLENS trial [12]

Test	MCID
6 MWT	25 – 30 m
SGRQ	4 points
FEV1	0.1 L
RV	6.1 – 8.6%

*6 MWT, 6-minute walk test; SGRQ, Saint George's Respiratory Questionnaire; FEV1, forced expiratory volume in 1 s; RV, residual volume*

For a therapy with coils, several prerequisites have to be met. The Nitinol spirals are an option for severely ill and symptomatic emphysema patients meeting the criteria of GOLD III with severe hyperinflation and a stable course of disease (patients who are not a high exacerbator phenotype, and have not recently been hospitalized for a respiratory event within 3 months). Important contraindications are pulmonary hypertension, clinically relevant bronchiectasis, giant bullae in chest CT or treatment with anticoagulants. Inclusion and exclusion criteria used in the REVOLENS trial are listed in Table 3.

**Table 3.** Medical inclusion and exclusion criteria in REVOLENS trial [12]

Inclusion Criteria	Exclusion Criteria
Bilateral emphysema on chest CT scan	Post bronchodilator FEV1 < 15% predicted
Post bronchodilator FEV1 < 50% predicted	Post-bronchodilator change in FEV1 > 20%
Total lung capacity > 100% predicted	Severe recurrent respiratory infections requiring more than 2 hospitalization stays within the past twelve months
Residual volume > 220% predicted	COPD exacerbation requiring hospital stay within 3 months
Dyspnea score between 2 and 4 based on the mMRC scale	Pulmonary Hypertension (Pulmonary systolic pressure > 50 mmHg on cardiac echo)
Stopped cigarette smoking for more than 8 weeks	Patient unable to perform a 6-minute walk test in room air (no restriction on distance)
Pulmonary rehabilitation within the previous twelve months	Giant bulla of more than 1/3 of the lung field on chest CT
	Strictly homogeneous emphysema on chest CT (investigator interpreted)
	Clinically significant bronchiectasis
	Past history of lobectomy, lung volume reduction surgery, lung transplantation
	Any extrapulmonary diseases compromising survival or evaluation within the protocol (severe cardiac disease, severe renal insufficiency, cancer...)
	Lung carcinoma or pulmonary nodule on CT scan requiring chest CT scan follow-up
	Contraindication to general anesthesia
	Oral anticoagulant treatment with vitamin K antagonists
	Allergy to Nitinol

*CT, computed tomography; FEV1, forced expiratory volume in 1 s; mMRC scale, modified Medical Research Council dyspnea scale*

As a conclusion, in the last years, several new therapeutic options were developed in the area of endoscopic lung volume reduction. The main differences are related to the therapeutic effect, area of application, number and severity of adverse events and quality of scientific data. To date, in contrast to other methods, the positive benefit-risk ratio of coils is documented by several well-designed randomized clinical trials [8,12,13]. Moreover, in the recently updated strategy paper of the GOLD (Global Initiative for Obstructive Lung Disease) expert group on management of COPD patients, endobronchial implantation of valves as well as coils are mentioned as bronchoscopic interventions for selected patients with advanced emphysema. Both techniques can reduce end-expiratory lung volumes and improve the patient's exercise capacity, lung function and quality of life (evidence level B) [1]. Frank Sciurba concluded in his editorial in JAMA with regard to the published pivotal study REV-OLENS: "Should the emerging data from larger pivotal trials support the meaningful clinical, albeit palliative, responses observed in preliminary trials, physicians caring for patients with COPD should not delay in providing evidence-based interventions that offer realistic hope to patients with few other choices to relieve their symptoms and improve their quality of life" [17].

### Declaration of conflicting interests

The authors declared no conflicts of interest with respect to the authorship and/or publication of this article.

### Funding

The author receives honoraria for consultancy PneumRx GmbH, a BTG international group

### References

1. Global Strategy for the Diagnosis, Management and Prevention of Chronic Obstructive Pulmonary Disease. <http://goldcopd.org/gold-2017-global-strategy-diagnosis-management-prevention-copd/> (last accessed: 05.04.2017)
2. Sanders C, Nath PH, Bailey WC. Detection of emphysema with computed tomography. Correlation with pulmonary function tests and chest radiography. *Invest Radiol* 1988; 23: 262-6.

3. Rabe KF. Improving Dyspnea in Chronic Obstructive Pulmonary Disease. *Proc Am Thorac Soc* 2006; 3: 270-5.
4. Cooper JD, Trulock EP, Triantafillou AN, Patterson GA, Pohl MS, Deloney PA, et al. Bilateral pneumectomy (volume reduction) for chronic obstructive pulmonary disease. *J Thorac Cardiovasc Surg* 1995; 109: 106-16.
5. Stirling GR, Babidge WJ, Peacock MJ, Smith JA, Matar KS, Snell GI, et al. Lung Volume Reduction Surgery in Emphysema: A Systematic Review. *Ann Thorac Surg* 2001; 72: 641-8.
6. Herth FJ, Eberhard R, Gompelman D, Slebos DJ, Ernst A. Bronchoscopic lung volume reduction with a dedicated coil: a clinical pilot study. *Thorax* 2010; 4: 225-31.
7. Slebos DJ, Klooster K, Ernst A, Herth FJ, Kerstjens HA. Bronchoscopic Lung Volume Reduction Coil Treatment of Patients With Severe Heterogeneous Emphysema. *Chest* 2012; 142: 574-82.
8. Shah PL, Zoumot Z, Singh S, Bicknell SR, Ross ET, Quiring J, et al. Endobronchial coils for the treatment of severe emphysema with hyperinflation (RESET): a randomised controlled trial. *Lancet Respir Med* 2013; 1: 233-40.
9. Deslee G, Klooster K, Hetzel M, Stanzel F, Kessler R, Marquette CH, et al. Lung volume reduction coil treatment for patients with severe emphysema: a European multicentre trial. *Thorax* 2014; 69: 980-6.
10. Klooster K, ten Hacken NHT, Franz I, Kerstjens HA, van Rikxoort EM, Slebos DJ. Lung Volume Reduction Coil Treatment in Chronic Obstructive Pulmonary Disease Patients with Homogeneous Emphysema: A Prospective Feasibility Trial. *Respiration* 2014; 88: 116-25.
11. Hartman JE, Klooster K, Gortzak K, ten Hacken NH, Slebos DJ. Long-term follow-up after bronchoscopic lung volume reduction treatment with coils in patients with severe emphysema. *Respirology* 2015; 20: 319-26.



12. Deslee G, Mal H, Dutau H, Bourdin A, Vergnon JM, Pison C, et al. Lung Volume Reduction Coil Treatment vs Usual Care in Patients With Severe Emphysema - The REVOLENS Randomized Clinical Trial. *JAMA* 2016; 315: 175-84.
13. Press Release BTG Dec 2015; <https://www.btgplc.com/media/press-releases/positive-data-from-renew-study-of-pneumrx-coils/>, Download 17.02.2016
14. Holland AE, SpruitMA, Troosters T, Puhan MA, Pepin V, Saey D, et al. An official European Respiratory Society/American Thoracic Society technical standard: field walking tests in chronic respiratory disease. *Eur Respir J* 2014; 44: 1428-46.
15. Herth FJ, Noppen M, Valipour A, Leroy S, Vergnon JM, Ficker JH, et al. Efficacy predictors of lung volume reduction with Zephyr valves in a European cohort. *Eur Respir J* 2012; 39: 1334-42.
16. Cederlund K, Tylen U, Jorfeldt L, Aspelin P. Classification of Emphysema in Candidates for Lung Volume Reduction Surgery. *Chest* 2002; 122: 590-6.
17. Sciruba FC. Bronchoscopic Lung Volume Reduction in COPD. *JAMA* 2016; 315:139-41.

Review Article

## Endoscopic lung volume reduction in chronic obstructive airway disease using one-way valves.

Konstantina Kontogianni<sup>a</sup>, Ralf Eberhardt

Department of Pulmonology and Critical Care Medicine, Heidelberg University, Heidelberg, Germany

### ABSTRACT

Chronic obstructive airway disease (COPD) is a progressive, irreversible and debilitating disease causing lung hyperinflation. Apart from smoking cessation and conventional medical treatment, lung volume reduction surgery (LVRS) has been used for several years but it involves a major thoracic surgery with high incidence of postoperative complications. In the past decade, different approaches of minimally invasive endoscopic lung volume reduction (ELVR) have been developed which differ in indication, mechanism of action, reversibility and are divided into two groups: blocking and non-blocking devices.

The endobronchial valves belong to the group of blocking devices available and have the largest series of treated patients. These one way valves are used to occlude the most emphysematous and hence destroyed lobe of the lung. Two different types of valves are available on the market: endobronchial valves (EBV, Zephyr valves) and intrabronchial valves (IBV, Spiration valves). They differ in shape but have a similar mechanism of action.

In order to improve the outcome of the ELVR using valves, dedicated screening involving pulmonary function and exercise capacity testing as well as qualitative and quantitative CT analysis and perfusion scan are necessary. Numerous studies in the past years have shown the efficacy and complications following valve therapy. It has been demonstrated that patients with complete fissures show a more pronounced benefit and a significant target lobe volume reduction. Furthermore, unilateral implantation aiming at obtaining complete lobar occlusion has been more effective than the bilateral incomplete treatment. Regarding possible complications, apart from pneumothorax, COPD exacerbations, hemoptysis and valve migrations have been reported.

Summarizing, in comparison to LVRS, ELVR using valves is a less invasive alternative with the opportunity to improve shortness of breath, exercise capacity, and quality of life in the patients, who have reached the end of their conventional treatment options.

**Key Words:** emphysema, endoscopic lung volume reduction, valve therapy

---

Corresponding Author<sup>a</sup>: Konstantina Kontogianni, MD. Thoraxklinik at the Heidelberg University Hospital, Röntgenstrasse 1, 69126, Heidelberg, Germany

Email: Konstantina.Kontogianni@med.uni-heidelberg.de

Received 05.09.2016 accepted 16.11.2016

## Introduction

Chronic obstructive airway disease (COPD) is a major cause of mortality and morbidity worldwide, currently constituting the fourth leading cause of death and it is estimated that it will occupy the 3rd place by 2020 [1]. Emphysema is present in approximately 1.8% of the population. It is a progressive, irreversible and debilitating disease, characterized by destruction of lung tissue as a result of inflammation caused by exposure to noxious inhaled agents for extended time. The most common cause of emphysema is cigarette smoking, but genetic, occupational, and environmental causes also account for up to 10% of cases [2]. Despite extensive public health initiatives aimed at discouraging cigarette smoking, smoking-related lung diseases remain a significant cause of disability and death worldwide.

The alveolar destruction caused by these agents leads to impairment in gas exchange and elastic recoil of the lung causing thus air trapping with an increase in residual volume and hyperinflation which subsequently worsen the patients' dyspnea perception. Because of the hyperinflation the respiratory muscles are forced to function at a mechanical disadvantage leading to decreased compliance of the chest wall and increase in work of breathing. As a consequence, patients experience chronic shortness of breath and limited exercise capacity and have thus a gradually declining quality of life. Smoking cessation and conventional medical treatment with inhaled bronchodilators (anticholinergics, beta-adrenergic agonists), anti-inflammatory medications (corticosteroids) and oral phosphodiesterase inhibitors constitute the mainstay of pharmacological treatment of COPD but are generally of limited benefit [3]. Long term oxygen therapy is recommended in patients with chronic respiratory failure and ventilatory support is indicated in patients with significant hypercapnia and related clinical symptoms. Finally, pulmonary rehabilitation and regular vaccination also play a very important role in the complex treatment strategy of COPD.

### *Surgical treatment for severe emphysema*

Lung volume reduction surgery (LVRS) has been used for several years in order to reduce the size and the hyperinflation of the lung. This procedure was first described by Brantigan back in the fifties [4]. Damaged areas of lung are resected either via median sternotomy or via a less invasive video-assisted thoracoscopy in order to reduce the lung hyperinflation and in this way

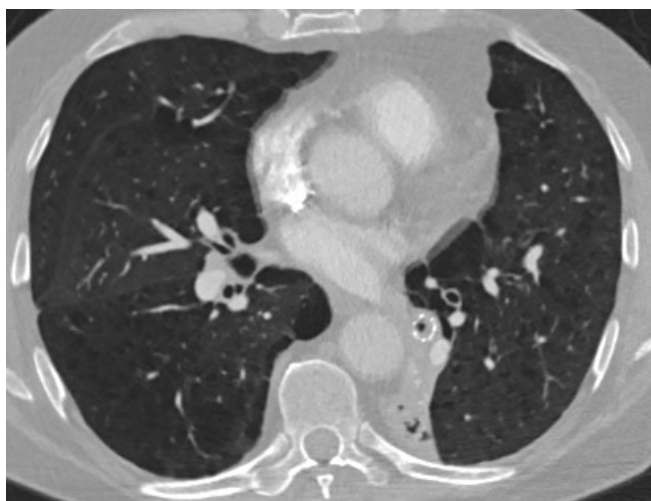
increase the breathing capacity. The benefits of LVRS were reported and confirmed in the National Emphysema Treatment Trial (NETT), which was a randomized controlled trial performed at 17 centers across the United States, comparing LVRS with optimal medical treatment [5]. 1218 patients were randomized and the selected subgroup of patients who were randomized to LVRS showed significant improvements in lung function, exercise capacity and quality of life. LVRS involves though a major thoracic surgery in a generally elderly population with limited breathing capacities that very frequently have clinically significant comorbidities. The NETT trial revealed a high incidence of postoperative complications; high incidence of serious cardiopulmonary complications, prolonged air leak and a three-month mortality rate of 5-10% were reported. Thus, despite its potential benefits fewer than 300 cases of LVRS are performed annually in the US and there are similarly small numbers in Europe [6].

Another surgical treatment for severe emphysema is lung transplantation. Accounting for 40% of all adult lung transplantations performed worldwide, end-stage COPD is the most common indication for lung transplantation [7]. Although single lung transplantation was in the past the predominant surgical therapy [8], the proportion of patients undergoing bilateral transplantation for COPD has increased significantly in the past decade. A total of 3,640 adult lung transplantations were reported in 2011 to the International Society for Heart and Lung Transplantation Registry [7]. Lung transplantation remains a major operative treatment available though to a limited number of patients, due to limited organ availability and access to specialized tertiary care centers.

In the past decade, different approaches for endoscopic lung volume reduction (ELVR) have been developed with the aim of reducing lung hyperinflation yet at the same time avoiding the morbidity, mortality and costs connected with LVRS as well as widening the indications to patients with severe comorbidities. These techniques differ in indication, mechanism of action, reversibility, as well as complications and are divided into two groups: blocking and non-blocking devices. All have been approved in Europe, but not by the US Food and Drug Administration to date. The aim of this review is to analyse the most widely studied devices for the ELVR, the endobronchial and intrabronchial valves.

### ***Endoscopic lung volume reduction using valves***

The endobronchial valves belong to the group of blocking devices available and have the largest series of treated patients. The characteristic feature of the endobronchial valves is the ability to block the entrance of air during inspiration, while permitting the emission of air and secretions during expiration. These one way valves are used to occlude the most emphysematous and hence destroyed lobe of the lung. With every expiration the amount of air in the treated lobe is reduced and this leads to volume reduction of the treated lobe reducing the overall lung volume and ideally inducing a complete lobar atelectasis, Figure 1.



**Figure 1.** Atelectasis after valve implantation (courtesy of Prof. Heußel)

Two different types of valves are available on the market: endobronchial valves (EBV, Zephyr valves) and intrabronchial valves (IBV, Spiration valves). They differ in shape but have a similar mechanism of action; both devices are self-expanding and retained into a catheter that can be introduced through the working channel of a flexible bronchoscope. The choice between one of the two types is influenced more by the bronchial anatomy rather than by different outcomes after valve placement. Although no comparative trial has been published, the effect of both types of valves seems to be similar.

### ***Patient selection criteria for valve therapy***

#### ***Pulmonary function and exercise capacity testing***

In order to improve the outcome of the ELVR using valves, dedicated screening, and selection of potential candidates is necessary. Not every patient with advanced COPD and severe emphysema is in principle

suitable for a valve implantation. Expert opinion suggests that patients with COPD GOLD D (III-IV) may be considered. The patient selection criteria for most studies concerning the endobronchial valves have initially been adopted from the criteria previously used in the NETT trial [5]. Therefore, patients with an FEV1 of <45% predicted and both an RV of >150% predicted and a total lung capacity of >100% were initially enrolled. All criteria mentioned here are based on expert opinion.

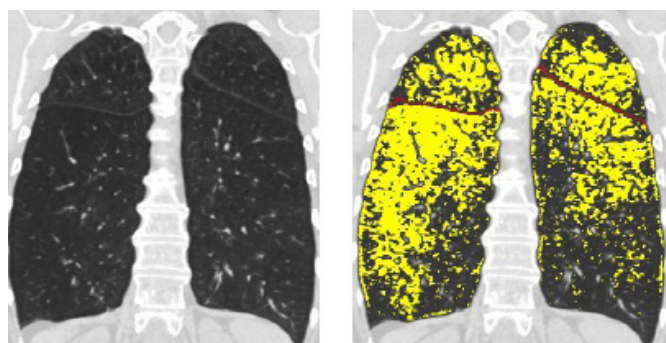
Patients with an FEV1 of <40% predicted and an RV of >200% tend to benefit more from valves, although this reflects the clinical experience rather than published data. A DLCO of < 20% predicted is not a strict contraindication for bronchial valve placement. The lower the DLCO the greater the emphysematous destruction of the lungs, however a significant number of patients are unable to perform a DLCO assessment correctly because they are not able to breath-hold for 10 seconds. Patients should have stopped smoking at least 4 months prior to any intervention and have received optimal conventional medical treatment with inhaled bronchodilators and anti-inflammatory medications. Recurrent exacerbations/pneumonias with hospitalisations may exclude patients from ELVR. A distance in 6-minute walking test (6-MWT) of >140 m represents a parameter for better endurance and for the functional reserve of the patient. Patients should optimally have taken part in a pulmonary rehabilitation program. There is however till now no evidence if pulmonary rehabilitation should be performed prior to or after ELVR to achieve the best outcome. Both the 6-MWT and the requirement of pulmonary rehabilitation are surgical inclusion criteria to minimize the peri- and postoperative morbidity, and their relevance in the less invasive ELVR is still unclear.

#### ***Qualitative, Quantitative CT analysis and perfusion scan***

The characterisation and quantification of emphysema is necessary for treatment planning and for monitoring of results. All patients require, in addition to the pulmonary function testing, a high resolution computer tomography (HRCT) prior to the intervention. Normally used in a low-dose protocol with a slice thickness of  $\leq 1$  mm, the HRCT enables the detection and quantification of the destruction of the peripheral lung tissue. Emphysema is divided into heterogeneous and homogeneous.

Depending on the emphysema predominance in patients with heterogeneous distribution, valve placement is possible in the upper lobes as well as in the lower lobes. In VENT and Euro-VENT the outcome was similar for both, without an increased risk for either of the group [9-10]. Homogeneous distribution of emphysema has not been extensively studied so far. A small case series showed that even patients with a homogeneous distribution could benefit [11]. Currently, patients with severe homogeneous emphysema are being recruited into a European Multicentre trial (IMPACT NCT02025205) to evaluate the effect of EBV placement in this patient subgroup.

Automated software programs help to visualize the severity and distribution of emphysema using the raw data and a threshold of -910 to -950 Hounsfield units (HU) and the emphysema can in this way be quantified automatically [12], Figure 2. Furthermore, new programs can determine additional parameters such as the heterogeneity index, the peripheral pulmonary vessel volume, low attenuation clusters (LACs) and also perform a three-dimensional analysis of the fissures, which have been shown to also play a role in predicting outcomes [13].



**Figure 2.** CT quantitative emphysema analysis, YACTA (courtesy of Prof. Heußel)

In lung parenchyma which has been destroyed by the emphysema, the perfusion is reduced. A perfusion scan can therefore be useful to confirm the target zone for ELVR and to verify the heterogeneity.

### ***Collateral ventilation and fissure analysis***

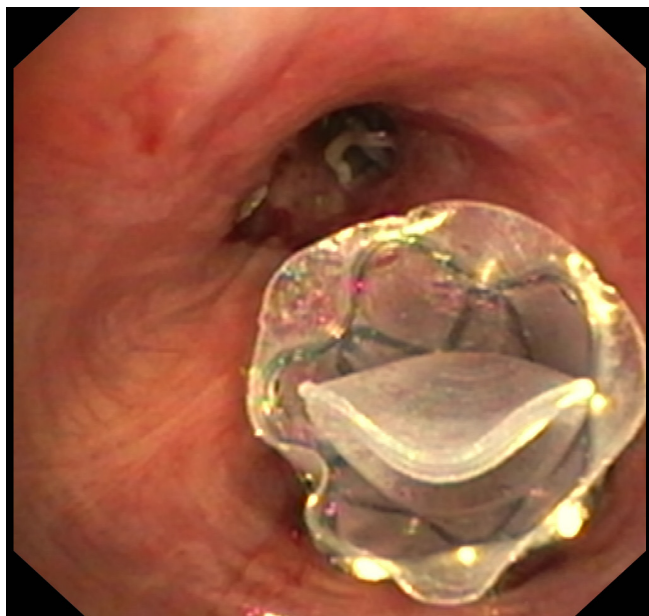
Collateral ventilation is an important predictor for the success of endobronchial valve placement. It has been defined as “the ventilation of alveolar structures through passages that bypass the normal airways” [14]. A post hoc subgroup analysis the VENT study demonstrated that patients with a complete interlobar fissure in the HRCT experienced very good outcomes following valve implantation [9]. A complete fissure is currently

defined as being >90% complete between the target and adjacent lobes in at least one axis on the CT. A complete fissure seems to be a surrogate indicator for low interlobar collateral ventilation (CV). Detection of large parenchymal connections is associated with a significant air exchange independent of the central airways. Therefore, for patients with an incomplete fissure it is very unlikely for atelectasis of the treated lobe to occur as air can still enter the lobe via “the back door” even if central lobar occlusion is achieved. These patients will most probably not benefit from valve treatment. This finding was confirmed by the results of the Euro-VENT [10].

Besides CT based fissure analysis, CV can be quantified by an invasive catheter-based measurement using the Chartis® Pulmonary Assessment System (Pulmonx Inc., Redwood, Calif., USA). It uses an endobronchial catheter with a compliant balloon at the distal tip to block the airway that is to be treated with endobronchial valves. Air flows from the target lobe through the Chartis catheter and the amount of air flow as well as pressure generated beyond the tip can be visualized via the Chartis console and thus CV can be quantified [15]. Patients with no significant interlobar ventilation are the patients who will benefit from valve implantation and are classified as “CV negative”; patients with a high interlobar flow are classified as “CV positive” and these patients are not candidates for ELVR with valve implantation. In a prospective multicenter trial published in 2013 the accuracy of CV assessment using the Chartis® System was evaluated [16]. Eighty patients were evaluated and the results demonstrated that Chartis measurement can predict with 75% accuracy which patients will benefit significantly from ELVR with valves.

### ***Zephyr valve***

The Zephyr® Valves (EBV, Pulmonx, Inc., Palo Alto, California, USA) have been studied most extensively. They are made of a nitinol mesh covered by silicon, with a double silicon membrane inside that opens during expiration and closes during inspiration, Figure 3. The valve is currently available in 3 different sizes. Measurement of the airway diameter in order to determine the appropriate size is required and it is performed with the introduction catheter. The catheter is advanced via the working channel of a flexible bronchoscope and is used to assess the size of the airway as well as deliver the appropriate size of valve. The first pilot study with this valve was published by Toma et al. in 2003 [17].



**Figure 3.** Zephyr valve

In the first and largest up to date randomized controlled trial, the Endobronchial Valve for Emphysema Palliation Trial (VENT), in patients with severe heterogeneous emphysema, endoscopic lung volume reduction with EBV was compared to best medical therapy [9]. In this trial 321 patients were randomized; 220 patients with advanced emphysema were treated by a complete occlusion of the targeted lobe (upper or lower lobe) by EBV and were compared to 101 patients who received only standard medical therapy. Primary endpoints of this study were safety and efficacy and the co-primary endpoints were percent change in FEV1 and 6-MWT. The difference between the 2 groups at 6-month follow-up was FEV1 increase in the EBV group by 6.8% ( $P = 0.002$ ) and an improvement in 6-MWT by 5.8% (increase by 9.3 m). The most common adverse events within 90 days were COPD exacerbations (7.9%), pneumothorax (4.2%) and hemoptysis (5.6%). Although the mean between-group difference was significant, the results were not clinically relevant.

Some patients were “better responders” though, meaning that they had clinically significant changes in their clinical outcome measures. The subgroup analysis of patients with complete fissures though, showed a more pronounced increase in FEV1 and 6-MWT (FEV1 by 16.2% and 6-MWT by 7.7% at 6 months) and a significant target lobe volume reduction, whereas the patients with incomplete fissures showed only minimal difference to the control group. Fissure completeness as assessed on HRCT scan was analysed individually as a marker of collateral ventilation and was shown to be an

independent predictor of response to treatment. Hence a complete occlusion of the treated lobe with absence of collateral ventilation proved to be prognostic factors for significant improvement in FEV1 and 6-MWT. In the recently published European cohort of the VENT study, patients in whom target lobe volume reduction  $>50\%$  (TLVR) was achieved had much greater improvements in clinical outcomes compared to a TLVR  $<20\%$ . Therefore, real volume reduction seems to be also an important point for a better outcome. Complication rates such as COPD exacerbations were the same in all groups [18].

Regarding the longer term effects of Zephyr valves implantation, a study by Venuta et al. [19] assessed the long term effects and also the clinical outcomes over 5 years. 40 patients were treated with Zephyr valves prior to Chartis being available. FEV1 improved from  $0.88 \pm 0.31$  to  $1.1 \pm 0.21$  after 3 months and this change was sustained on follow-up after 3 and 5 years. RV decreased by a mean of 500 ml and both 6-MWT and mMRC score improved significantly. Most of the improvements were seen in the first year, but they were sustained over a prolonged period although the follow up was constrained to only 9 out of the 40 patients for the full 5 years. No severe complications due to the valves were observed. There were deaths reported during the long follow-up patients, but none of the deaths were associated with valve placement. In view of the advanced disease the mean and median survival was  $36 \pm 4.3$  months and  $30 \pm 4.6$  months respectively. Survival was noted at 1, 3 and 5 years to be 81.6%, 47.4% and 22.4% respectively.

After the recognition of possible predictive factors more randomized controlled studies were carried out in which only patients with low collateral ventilation, were treated by complete occlusion of one lobe. In the so-called Believer HiFi study [20], 25 patients with complete fissures, were treated by valve placement and compared with 25 patients of the control group. This study did not take into account the results of the Chartis® measurement that was performed before valve implantation though. Three months after the valve therapy FEV1 in the treatment group increased by a median of 8.77% (IQR 2.27-35.85) versus 2.88% (0-8.51) in the control group (Mann-Whitney  $P = 0.0326$ ). Significant results have also been seen in the 6-MWT.

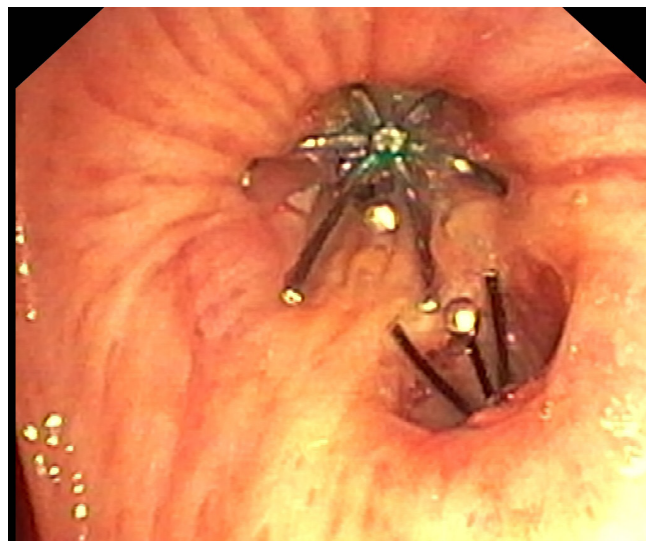
Another study from last year compared the clinical outcomes in upper versus lower lobe EBV treatment in severe emphysema [21]. Of the 331 patients treated, 60 had low interlobar collateral ventilation and successful

lobar exclusion (45 patients with upper lobe treatment and 15 patients with lower lobe treatment). A higher destruction score (70.3 vs. 60.7%;  $P = 0.0010$ ) and a higher heterogeneity index (24 vs. 13%;  $P = 0.0005$ ) for the upper lobe cohort were the only differences in the baseline characteristics between the two groups. At 180 days, both groups had improved clinically. There were no significant differences in mean changes or responder rates of FEV1 (+23.8 vs. +22.9%), the SGRQ score (-6.50 vs. -7.53 points), 6-MWT (+24.1 vs. +44.0 m), target lobe volume reduction (-1,199 vs. -1,042 ml), or in the adverse event rate between both cohorts. This study showed that patients with lower and upper lobe predominant emphysema benefit equally from EBV therapy when interlobar collateral ventilation is low and lobar exclusion is achieved.

Finally, in the recently published STELVIO study [22], a total of 68 patients were randomized to a treatment arm and a control arm. In all 34 patients who received valve treatment, significant collateral ventilation had been excluded previously by Chartis® measurement. Six months after valve implantation, a significant difference in FEV1 (161 ml vs. 21 ml), forced vital capacity (VC) (416 ml vs. 69 ml) and the 6-MWT (60 m vs. -14 m) have been seen between the two groups in favor of the treatment arm. Furthermore, significant differences in the SGRQ score, as well as the lobar volume reduction have been reported. This study has thus further confirmed the latest conducted randomized clinical trials and has shown that valve therapy after appropriate patient selection is an effective treatment option for patients with advanced emphysema.

### *Spiration valve*

The intrabronchial valve (IBV, Spiration®, Olympus, Tokyo, Japan) consists of a polymer covered framework made out of nitinol (a nickel and titanium alloy) in the shape of an umbrella, Figure 4. The valve is secured to the bronchial wall by 5 hook-like anchors and can be removed by grasping and pulling on its proximal central rod with forceps. 4 different sizes (5, 6, 7 and 9 mm) are currently available. Three multicenter studies in the past decade enrolled patients with upper lobe predominant emphysema. At the beginning valves were placed unilaterally in the upper lobes and were initially well tolerated by patients without any serious complications. The most frequent adverse events recorded were pneumonia, COPD exacerbation, dyspnea, hemoptysis, chest pain and pneumothorax [23-25].



**Figure 4.** Spiration valve

It is interesting to note that in the pilot study by Stermann et al. 12.1% of the patients sustained a pneumothorax [25]. Following the observation of a higher incidence of pneumothorax occurring with complete lobar occlusion (especially of the left upper lobe), the investigators modified their strategy during the study and continued with bilateral treatment keeping open the lingula and avoiding complete lobar occlusion. The aim of this treatment strategy was not the actual lung volume reduction but rather a redirection of air to less destroyed and better perfused lung tissue, improving thus the ventilation/perfusion match. The results of this trial showed no modification of functional parameters (FEV1, total lung volume and exercise tests were unchanged) but a significant improvement of quality of life (SGRQ = -8.2 points at 6 months). All three abovementioned studies showed a significant improvement in quality of life questionnaire, but they could not demonstrate a statistically significant improvement of lung function parameters and 6-MWT.

In a multicenter, blinded, sham-controlled study by Ninane et al. [26], 73 patients were included. All patients had upper lobe predominant severe emphysema, 37 of them were randomized to bronchoscopy with implantation of IBV valves and 36 had a sham bronchoscopy. The treatment consisted of bilateral upper lobe valve implantation with incomplete occlusion of the target lobe. Overall the procedure and devices were well tolerated and there were no differences in adverse events between both groups. The most frequent complications were pneumonia (3.6-4.2%), pneumothorax (4.2-4.5%), hemoptysis (5.4-6.1%) and exacerbation of COPD (7.9%). At 3 months follow-up, there was no significant difference in lung function, health-related

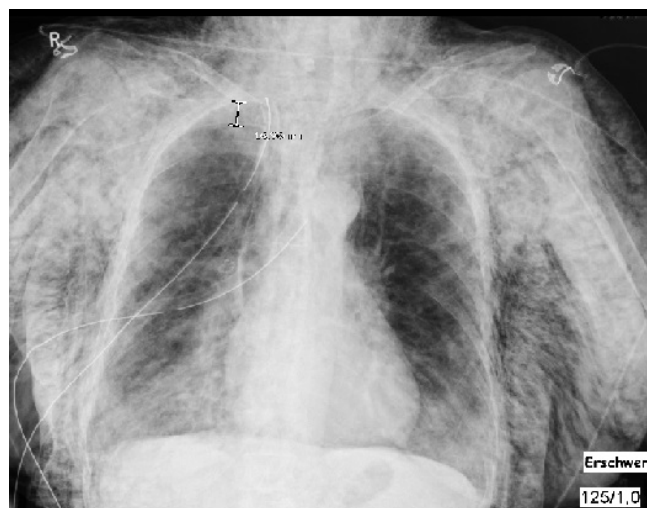
quality of life (assessed by SGRQ) or breathlessness. Treatment with IBV without complete occlusion was safe but ineffective and no functional improvement was observed. The improvement in SGRQ in both groups was attributed to a significant placebo effect. Another randomized, sham procedure controlled, double-blind multicenter trial from Wood et al. [27], 277 subjects were enrolled at 36 centers. The primary effectiveness measure was a significant improvement in disease-related quality of life (St. George's Respiratory Questionnaire) and changes in lobar lung volumes. The primary safety measure was a comparison of serious adverse events. There were 6/121 (5.0%) responders in the treatment group at 6 months, significantly  $>1/134$  (0.7%) in the control group [Bayesian credible intervals (BCI), 0.05%, 9.21%]. Lobar volume changes were significantly different with an average decrease in the treated lobes of -224mL compared with -17mL for the control group (BCI, -272, -143). The proportion of responders in St. George's Respiratory Questionnaire was not greater in the treatment group. There were significantly more subjects with a serious adverse event in the treatment group ( $n = 20$  or 14.1%) compared with the control group ( $n = 5$  or 3.7%) (BCI, 4.0, 17.1), but most were neither procedure nor device related.

Eberhardt et al. demonstrated that a unilateral procedure with the aim of a complete lobar occlusion is more effective than bilateral incomplete treatment [28]. Twenty two patients were enrolled and randomised in this study, 11 patients received unilateral IBV valve implantation and 11 patients bilateral upper-lobe implantation. The aim of the unilateral valve placement was a total occlusion of one lobe, the bilateral treatment aimed at an incomplete closure. The 30 and 90 day follow-up showed a significant difference in lung function (FEV1 = +21.4 vs. -0.03%) and 6-MWT, as well as in mMRC and SGRQ scores in the unilateral treated group. One patient suffered a pneumothorax in the unilateral group, and two patients in the bilateral group needed treatment for a respiratory event. These results demonstrated that the unilateral procedure aimed at obtaining complete lobar occlusion is more effective than the bilateral incomplete treatment and that, given the superior outcome, the increased risk of pneumothorax may be acceptable.

### **Complications of valve therapy**

Although endoscopic valve therapy is a minimally invasive procedure, it is associated with a complication risk. Within the first 3 months after valve implantation in the VENT study COPD exacerbations, hemoptysis, pneu-

mothoraxes, and also valve migrations were reported [9]. In particular, pneumothorax has been of high importance, since in the recent years a significant increase in its incidence has been observed, Figure 5. While in the VENT study a pneumothorax rate of only 4.2% was recorded, in the follow-up studies the pneumothorax rates were between 8-25% [20,29]. The cause of this increasing incidence is the optimized patient selection: a complete fissure seems not only to be a predictor of a successful valve therapy, but also a predictor of pneumothorax occurrence. A very rapid volume displacement by an atelectasis of the treated lobe can lead to a tear in the expanding untreated collateral lobe and thus to a postinterventional pneumothorax. Thus with complete fissures being a predictor of successful treatment as well as of pneumothorax it is likely that patients who suffer from pneumothorax after valve implantation will also benefit from valve treatment. A retrospective study showed that patients with a pneumothorax after valve therapy experienced a lobar volume reduction of 65% [30]. In another study it could be demonstrated that clinical success will occur only in patients who in the course after the successful pneumothorax management also develop an atelectasis [31]. Nevertheless, pneumothorax is a serious complication that usually requires intrapleural drainage and in about half the cases requires also the removal of at least one valve. An algorithm should be developed in order to manage these pneumothoraces that occur after valve placement. Chest tube insertion is the first step but if this fails to re-expand the lung, valve removal or video thoracoscopy to seal the leak may be the next step. Because the pneumothorax occurs in 76% of cases within the first three days after valve implantation, a stationary monitoring 48-72 hours is advised [32].



**Figure 5.** Pneumothorax after valve implantation (courtesy of Prof. Heußel)



A 48-hour postinterventional bed-rest seems to minimize the risk of pneumothorax [29]. In this recent study von Herzog et al, 72 consecutive COPD patients with severe homogeneous or heterogeneous emphysema and negative collateral ventilation status assessed by the Chartis console, were treated with EBV. 32 patients were treated with standard medical care (SMC) without restriction to bed rest and 40 patients followed a modified medical care (MMC) that included 48 hours strict bed-rest and, if needed, 16 mg codeine up for cough to three times a day (TID). The frequencies of pneumothorax were compared between the two groups. In the 48-hour bed-rest group a significant lower rate of pneumothorax was observed ( $P = 0.02$ ) and no significantly increased incidence of thromboembolic events, infections or complications. However, the number of patients of this study is too small, so further studies to verify protective factors of pneumothorax are required.

As a conclusion emphysema is a debilitating lung disease and a global health burden. Endoscopic valve implantation is a new treatment option for patients with advanced COPD and severe emphysema. Nevertheless, medical therapy, pulmonary rehabilitation, as well as smoking cessation remain the basis of therapy. In comparison to LVRS, the endoscopic procedures are less invasive alternatives with the opportunity to improve shortness of breath, exercise capacity, and quality of life in the patients, who have reached the end of their conventional treatment options.

The careful patient selection which should include assessment of collateral ventilation, emphysema heterogeneity and distribution, the amount of hyperinflation and comorbidities are all factors that need to be carefully considered before treatment. Patients who are potential candidates, according to experts in the field, should have in the lung function testing ideally  $FEV_1 < 40\%$  and  $RV > 200\%$ . Even though patients with  $FEV_1$  of under 20% were excluded from older trials since they were considered a high risk group, it has been shown in clinical practice that these patients also benefit from these interventional techniques.

There is increasing evidence that endobronchial valves are particularly effective in patients with het-

erogeneous emphysema, where total lobar exclusion is achieved and current data point even to a survival advantage for those patients with lobar atelectasis. The best clinical and functional results seem to be correlated with the development of atelectasis. Without atelectasis the improvement is generally modest or absent.

The development of atelectasis or rapid volume reduction is associated with a risk of pneumothorax as a consequence of the nontreated ipsilateral lobe expanding quickly and the visceral pleura tearing. The pneumothorax usually occurs within 24-72 hours after the procedure and may require an intercostal chest tube. New research evidence seems to suggest that patients who develop a pneumothorax after EBV placement showed greater improvement in  $FEV_1$  and target lobe volume reduction. Therefore, this risk may be acceptable for the patient and the bronchoscopist in view of the potential clinical benefit. Finally, the main advantage of both valves is their removability and safety. Currently however there is no comparative study available addressing the question of superiority of one valve versus the other.

### Declaration of conflicting interests

The authors declared no conflicts of interest with respect to the authorship and/or publication of this article.

### Funding

The author received no financial support for the research and/or authorship of this article.

### References

1. Global Strategy for the Diagnosis, Management and Prevention of COPD. Global Initiative for Chronic Obstructive Lung Disease (GOLD) 2015. Available from: <http://www.goldcopd.org/>
2. Halbert RJ, Natoli JL, Gano A, Badamgarav E, Buist AS, Mannino DM. Global burden of COPD: systematic review and meta-analysis. *Eur Respir J* 2006; 28: 523-32.
3. Ambrosino N, Simonds A. The clinical management in extremely severe COPD. *Respir Med* 2007; 101: 1613-24.
4. Brantigan OC, Mueller E. Surgical treatment of pulmonary emphysema. *Am Surg* 1957; 23: 789-804.

5. Fishman A, Martinez F, Naunheim K, Piantadosi S, Wise R, Ries A, et al. A randomized trial comparing lung-volume-reduction surgery with medical therapy for severe emphysema. *N Engl J Med* 2003; 348: 2059-73.
6. Chang AC, Chan KM, Martinez FJ. Lessons from the national emphysema treatment trial. *Semin Thorac Cardiovasc Surg* 2007; 19: 172-180.
7. Yusen RD, Christie JD, Edwards LB, Kucheryavaya AY, Benden C, Dipchand AI, et al. The Registry of the International Society for Heart and Lung Transplantation: thirtieth adult lung and heart-lung transplant report-2013; focus theme: age. *J Heart Lung Transplant* 2013; 32: 965-78.
8. Trulock EP, Christie JD, Edwards LB, Boucek MM, Aurora P, Taylor DO, et al. Registry of the International Society for Heart and Lung Transplantation: twenty-fourth official adult lung and heart-lung transplantation report – 2007. *J Heart Lung Transplant* 2007; 26: 782-95.
9. Sciurba FC, Ernst A, Herth FJ, Strange C, Criner GJ, Marquette CH, et al. A randomized study of endobronchial valves for advanced emphysema. *N Engl J Med* 2010; 363: 1233-44.
10. Herth FJ, Noppen M, Valipour A, Leroy S, Vergnon JM, Ficker JH, et al. Efficacy predictors of lung volume reduction with Zephyr valves in a European cohort. *Eur Respir J* 2012; 39: 1334-42.
11. Eberhardt R, Heussel CP, Kreuter M, Weinheimer O, Herth FJ. Bronchoscopic lung volume reduction in patients with severe homogeneous lung emphysema: a pilot study. *Dtsch Med Wochenschr* 2009; 134: 506-10.
12. Heussel CP, Herth FJ, Kappes J, Hantusch R, Hartlieb S, Weinheimer O, et al. Fully automatic quantitative assessment of emphysema in computed tomography: comparison with pulmonary function testing and normal values. *Eur Radiol* 2009; 19: 2391-402.
13. Schuhmann M, Raffy P, Yin Y, Gompelmann D, Oguz I, Eberhardt R, et al. Computed tomography predictors of response to endobronchial valve lung reduction treatment. Comparison with chartis. *Am J Respir Crit Care Med* 2015; 191: 767-74.
14. Cetti EJ, Moore AJ, Geddes DM. Collateral ventilation. *Thorax* 2006; 61: 371-3.
15. Gompelmann D, Eberhardt R, Michaud G, Ernst A, Herth FJ. Predicting atelectasis by assessment of collateral ventilation prior to endobronchial lung volume reduction: a feasibility study. *Respiration* 2010; 80: 419-25.
16. Herth FJ, Eberhardt R, Gompelmann D, Ficker JH, Wagner M, Ek L, et al. Radiological and clinical outcomes of using Chartis to plan endobronchial valve treatment. *Eur Respir J* 2013; 41: 302-8.
17. Toma TP, Hopkinson NS, Hillier J, Hansell DM, Morgan C, Goldstraw PG, et al. Bronchoscopic volume reduction with valve implants in patients with severe emphysema. *Lancet* 2003 15; 361: 931-3.
18. Valipour A, Herth FJ, Burghuber OC, Criner G, Vergnon JM, Goldin J, et al. Target lobe volume reduction and COPD outcome measures after endobronchial valve therapy. *Eur Respir J* 2014; 43: 387-96.
19. Venuta F, Anile M, Diso D, Carillo C, De Giacomo T, D'Andrilli A, et al. Long-term follow-up after bronchoscopic lung volume reduction in patients with emphysema. *Eur Respir J* 2012; 39: 1084-9.
20. Davey C, Zoumot Z, Jordan S, McNulty WH, Carr DH, Hind MD, et al. Bronchoscopic lung volume reduction with endobronchial valves for patients with heterogeneous emphysema and intact interlobar fissures (the BeLieVeR-HiFi study): a randomized controlled trial. *Lancet* 2015; 386: 1066-73.
21. Eberhardt R, Herth FJ, Radhakrishnan S, Gompelmann D. Comparing Clinical Outcomes in Upper versus Lower Lobe Endobronchial Valve Treatment in Severe Emphysema. *Respiration*. 2015; 90: 314-20.
22. Klooster K, ten Hacken NH, Hartman JE, Kerstjens HA, van Rikxoort EM, Slebos DJ. Endobronchial Valves for Emphysema without Interlobar Collateral Ventilation. *N Engl J Med* 2015; 373: 2325-35.
23. Wood DE, McKenna RJ, Jr., Yusen RD, Sterman DH, Ost DE, Springmeyer SC, et al. A multicenter trial of an intrabronchial valve for treatment of severe emphysema. *J Thorac Cardiovasc Surg* 2007; 133: 65-73.

24. Coxson HO, Nasute Fauerbach PV, Storness-Bliss C, Muller NL, Cogswell S, Dillard DH, et al. Computed tomography assessment of lung volume changes after bronchial valve treatment. *Eur Respir J* 2008; 32: 1443-50.
25. Sterman DH, Mehta AC, Wood DE, Mathur PN, McKenna RJ, Jr., Ost DE, et al. A multicenter pilot study of a bronchial valve for the treatment of severe emphysema. *Respiration* 2010; 79: 222-33.
26. Ninane V, Geltner C, Bezzi M, Foccoli P, Gottlieb J, Welte T, et al. Multicentre European study for the treatment of advanced emphysema with bronchial valves. *Eur Respir J* 2012; 39: 1319-25.
27. Wood DE, Nader DA, Springmeyer SC, Elstad MR, Coxson HO, Chan A, et al. The IBV Valve trial: a multicenter, randomized, double-blind trial of endobronchial therapy for severe emphysema. *J Bronchology Interv Pulmonol.* 2014; 21: 288-97.
28. Eberhardt R, Gompelmann D, Schuhmann M, Heussel CP, Herth FJ. Complete unilateral vs partial bilateral endoscopic lung volume reduction in patients with bilateral lung emphysema. *Chest* 2012; 142: 900-8.
29. Herzog D, Poellinger A, Doellinger F, Schuermann D, Temmesfeld-Wollbrueck B, Froeling V, et al. Modifying Post-Operative Medical Care after EBV Implant May Reduce Pneumothorax Incidence. *PLoS One* 2015; 10: e0128097.
30. Gompelmann D, Herth FJF, Slebos DJ, Valipour A, Ernst A, Criner GJ, et al. Pneumothorax following Endobronchial Valve Therapy and Its Impact on Clinical Outcomes in Severe Emphysema. *Respiration* 2014; 87:485-91.
31. Gompelmann D, Herth FJF, Ehlken N, et al. Development of endoscopic valve therapy in patients with severe emphysema. *ERS* 2015. PA 795.
32. Gompelmann D, Herth FJF, Heussel CP, et al. Pneumothorax following valve treatment. *ERS* 2014. Abstract 3702.

# CURRENT THORACIC SURGERY

## Instructions for Authors

### Aim and Scope

The Current Thoracic Surgery is a current periodical, peer-reviewed and open access e- journal. It is the official e-journal of the Turkish Society of Thoracic Surgery and published three times annually.

The Current Thoracic Surgery publishes articles in branches of general thoracic surgery, thoracic surgery anesthesia and thoracic disease (lung disease, esophagus disease).

The Current Thoracic Surgery is dedicated to publishing clinical research, clinical analysis, laboratory and experimental studies, editorials, invited current reviews, case reports, interesting images and "How to Do It" papers.

Being a peer-reviewed e-journal, the manuscripts sent will be evaluated by consultants and should be appropriate for the current version of common rules indicated for biomedical manuscripts as defined by the International Committee of Medical Journal Editors (ICMJE).

The journal accepts English language manuscripts. Articles will not be accepted for evaluation if they have been published or if they are considered for publication elsewhere and if they are not prepared according to the publication rules of the journal.

### Peer Review Process

All manuscripts submitted for publication are strictly reviewed by at least three reviewers. Due to the Current Thoracic Surgery journal's double-blinded review principles, the names of the authors and reviewers are not known to the other.

### Open Access Policy

The Journal has adopted the "open access policy" by considering the principle increasing the global exchange of the knowledge that generates useful results for humanity. The Current Thoracic Surgery is an "open access" e-journal the content of which is available to all users freely. Users can read the articles in full text, download, issue, print out and link to articles citing the journal without taking permission from the publisher or the author(s).

### Archiving

This journal uses LOCKSS system to allow participating libraries create distributed permanent archives for conservation and restoration. If you would like more information about LOCKSS system.

### Conflict of Interest Statement

Authors should declare as a statement at the end of the article that, there is no conflict of interest and also, if there is any, the status for their financial support should be clear in the cover letter and article.

### Exclusive Publication Statement

Authors must certify that none of the material in the manuscript has been published previously in either print or electronic form, and that none of the submitted material is currently under consideration for publication elsewhere. This

includes symposia, transactions, books, articles published by invitation, posting in electronic format and preliminary publications of any kind except an abstract of 400 words or fewer.

### Ethics

Authors are responsible for all (ethical, scientific, legal, etc.) content of their published material.

Approval by the local institutional human research committee according to Helsinki Declaration is obligatory for experimental, clinical and drug researches. Informed consents from participants should be obtained and these two points should clearly be declared in the "Materials and Methods" section.

All papers reporting animal experiments should include a statement in "Materials and Methods" section giving assurance that all animals have received humane care in compliance with the Guide for the Care and Use of Laboratory Animals and indicating for the approval by the institutional ethical review board. If necessary, a copy of the form could be required by the editor. It is obligatory for the articles to be convenient in terms of research and publication ethics, the authors are responsible for their articles.

### Informed Consent

Editors should protect the confidentiality of individual information (e.g. that obtained through the doctor-patient relationship). It is therefore almost always necessary to obtain written informed consent from patients described in case reports and for photographs of patients. It may be possible to publish without explicit consent if the report is important to public health (or is in some other way important); consent would be unusually burdensome to obtain; and a reasonable individual would be unlikely to object to publication (all three conditions must be met).

### Open Access Policy

The journal has adopted the "open access policy" by considering the principle increasing the global exchange of the knowledge that generates useful results for humanity. Current Thoracic Surgery is an "open access" e-journal the content of which is available to all users freely. Users can read the articles in full text, download, issue, print out and link to articles citing the journal without taking permission from the publisher or the author(s).

### Publication Frequency

The Current Thoracic Surgery is published three times annually.

### Copyright Transfer

Authors of articles submitted to the Current Thoracic Surgery must transfer copyright to the journal during submission process. This transfer becomes binding upon acceptance of the article for publication. No part of the published material may be reproduced elsewhere without written permission from the Current Thoracic Surgery.

## Statistical Knowledge

The statistical method used should be reported in a way that a reader whoever could reach the original data could understand the results. The terms used, abbreviations, symbols, the pc program used and the statistical method should all be defined. When reporting the results, especially when giving means and percentages, two digits should be given after the comma (112.20 or 112.21 instead of 112.2). P, t, Z values are exceptional and three digits should be given after the comma ( $P = 0.001$ , instead of  $P < 0.05$ ).

Briefly, except whole numbers, two digits after the comma should be given, but for statistical values like P, t, z, F, Chi-square, three digits after the comma should be given. When presenting P values, the exact P value together with the test statistics should be given, except for the case when this value is smaller than one percent or one per thousand (this time  $P < 0.01$  or  $P < 0.001$ , respectively should be given).

## Publication Ethics and Malpractice Statement

The Current Thoracic Surgery is electronic peer reviewed international journal committed to upholding the possible highest standards of publication ethics. In order to provide our readers with a journal of highest quality we state the following principles of Publication Ethics and Malpractice Statement. All articles not in accordance with these standards, will be removed from the publication if malpractice is discovered at any time even after the publication.

The Current Thoracic Surgery is checking all papers in a double-blind peer review process. We also check for plagiarism and research fabrication (making up research data); falsification (manipulation of existing research data, tables, or images) and improper use of humans or animals in research. In accordance with the code of conduct we will report any cases of suspected plagiarism or duplicate publishing. The Current Thoracic Surgery reserves the right to use plagiarism detecting software to screen submitted papers at all times.

**Authors;** must ensure that they have written original works.

In addition they must ensure that the manuscript has not been issued elsewhere.

Any work or words of other authors, contributors, or sources should be appropriately credited and referenced.

Authors are also responsible for language editing before submitting the article.

Authors submitting their works to the journal for publication as original articles confirm that the submitted works represent their authors' contributions and have not been copied or plagiarized in whole or in part from other works without clearly citing. Any work or words of other authors, contributors, or sources (including online sites) should be appropriately credited and referenced.

All authors should disclose financial or other conflict of interest that might influence the results or interpretation of their manuscript (financial support for the project should be disclosed).

When an author discovers a significant error or inaccuracy

in his/her own published work, it is the author's obligation to promptly notify the journal editor and cooperate with the editor to retract or correct the paper. An author agrees to the license agreement before submitting the article.

All articles must be submitted using online submission procedure. Submitting a paper simultaneously to more than one publication at a time is a breach of publications ethics.

Before publication of an accepted manuscript, each author will be required to certify that he or she has participated sufficiently in the work to take responsibility for a meaningful share of the content of the manuscript, and that this participation included:

1. Conception or design of the experiment(s), or collection and analysis or interpretation of data;
2. Drafting the manuscript or revising its intellectual content; and
3. Approval of the final version of the manuscript to be published.

**Editors;** must ensure a fair double-blind peer-review of the submitted articles for publication. They will strive to prevent any potential conflict of interests between the author and editorial and review personnel. Editors will also ensure that all the information related to submitted manuscripts is kept as confidential before publishing. Editor-in-Chief will coordinate the work of the editors.

**Reviewers;** evaluate manuscripts based on content without regard to ethnic origin, gender, sexual orientation, citizenship, religious belief or political philosophy of the authors. They must ensure that all the information related to submitted manuscripts is kept as confidential and must report to the Editor-in-Chief if they are aware of copyright infringement and plagiarism on the author's side. They must evaluate the submitted works objectively as well as present clearly their opinions on the works in a clear way in the review form. A reviewer who feels unqualified to review the research reported in a manuscript or knows that its prompt review will be impossible should notify the Editor-in-Chief and excuse himself from the review process.

## Plagiarism Statement

Whether intentional or not, plagiarism is a serious violation. We define plagiarism as a case in which a paper reproduces another work with at least 25% similarity and without citation. In accordance with the code of conduct we will report any cases of suspected plagiarism or duplicate publishing. Current Thoracic Surgery reserves the right to use plagiarism detecting software to screen submitted papers at all times.

## Article Download Statistics

The Current Thoracic Surgery provides article download statistics.

All manuscripts must be submitted through the online system for TUBİTAK ULAKBİM DergiPark at <http://dergipark.ulakbim.gov.tr/currthoracsurg/> (this URL will be available until the end of 2017 as declared by ULAKBİM) or <http://dergipark.gov.tr/currthoracsurg>. You will be guided for uploading of the files.

## Submission Process

Papers are accepted for publication on the understanding that they have not been published and are not going to be considered for publication elsewhere. Authors should certify that neither the manuscript nor its main contents have already been published or submitted for publication in another journal. The copyright release form, which can be found at web site must be signed by the corresponding author on behalf of all authors and must accompany all papers submitted. Please see the form for additional copyright details. After a manuscript has been submitted, it is not possible for authors to be added or removed or for the order of authors to be changed. If authors do so, their submission will be canceled.

Manuscripts may be rejected without peer review by the editor-in-chief if they do not comply with the instructions to authors or if they are beyond the scope of the journal. Any manuscript that does not conform to the Uniform Requirements for Manuscripts Submitted to Biomedical Journals, as reported at <http://www.icmje.org/icmje-recommendations.pdf>, will also be rejected. After a manuscript has been accepted for publication, i.e. after referee-recommended revisions are complete, the author will not be permitted to make changes that constitute departures from the manuscript that was accepted by the editor. Before publication, the galley proofs are always sent to the authors for corrections. Mistakes or omissions that occur due to some negligence on our part during final printing will be rectified in an errata section in a later issue. This does not include those errors left uncorrected by the author in the galley proof.

The use of someone else's ideas or words in their original form or slightly changed without a proper citation is considered plagiarism and will not be tolerated. Even if a citation is given, if quotation marks are not placed around words taken directly from another author's work, the author is still guilty of plagiarism. Reuse of the author's own previously published words, with or without a citation, is regarded as self-plagiarism. All manuscripts received are submitted to iThenticate®, a plagiarism checking system, which compares the content of the manuscript with a vast database of web pages and academic publications. Manuscripts judged to be plagiarized or self-plagiarized, based on the iThenticate® report or any other source of information, will not be considered for publication.

### Preparation of Manuscript

#### Style and Format

Manuscripts should be double-spaced with 3-cm margins on all sides of the page, in Times New Roman font. Every page of the manuscript, including the title page, references, tables, etc., should be numbered. All copies of the manuscript should also have line numbers starting with 1 on each consecutive page. Manuscripts should be written in English. Contributors who are not native English speakers are strongly advised to ensure that a colleague fluent in the English language or a professional language editor has reviewed their manuscript. Concise English without jargon should be used. Repetitive use of long sentences and passive voice should be avoided. It is strongly recommended that the text be run through computer spelling and grammar programs. Either British or American spelling is acceptable but must be consistent throughout.

### Symbols, Units and Abbreviations

In general, the journal follows the conventions of Scientific Style and Format, The CSE Manual for Authors, Editors, and Publishers, Council of Science Editors, Reston, VA, USA (7th ed.). If symbols such as  $\times$ ,  $\mu$ ,  $\eta$ , or  $\nu$  are used, they should be added using the Symbols menu of Word. Degree symbols ( $^{\circ}$ ) must be used from the Symbol menu, not superscripted letter o or number 0. Multiplication symbols must be used ( $\times$ ), not the letter x. Spaces must be inserted between numbers and units (e.g., 3 kg) and between numbers and mathematical symbols (+, -,  $\times$ , =, <, >), but not between numbers and percent symbols (e.g., 45%). Please use SI units. All abbreviations and acronyms should be defined at first mention. Latin terms such as *et al.*, *in vitro*, or *in situ* should not be italicized.

### Manuscript Content

Research articles should be divided into the following sections. Principal sections should be Introduction, Materials and Methods, Results, Discussion, Acknowledgements and References sections. Please see below for information about other types of manuscripts.

### Title and Contact Information

The first page should contain the full title in sentence case, the full names (last names fully capitalized) and affiliations (in English) of all authors (University, Faculty, Department, City, Country), and the contact address and e-mail for the clearly identified corresponding author.

### Abstract

An informative abstract of not more than 200 words must accompany each manuscript. The abstract must be structured to include the study's background and aim, materials and methods, results, and conclusions and keywords under 5 separate headings. Abstracts of review articles should be a brief overview of the main points from the review.

### Keywords

Please provide at least 3 key words or phrases to enable retrieval and indexing. Acronyms should be avoided.

Always try to use terms from the Medical Subjects Headings (MeSH) list from PubMed <https://www.ncbi.nlm.nih.gov/pubmed>.

### Introduction

This should argue the case for your study, outlining only essential background, and should not include the findings or the conclusions. It should not be a review of the subject area, but should finish with a clear statement of the question being addressed.

### Materials and Methods

Explain clearly but concisely your clinical, technical, or experimental procedures. Previously published papers related to the methods should be cited with appropriate references. Brand names and company locations should be supplied for all mentioned equipment, instruments, chemicals, etc.

## Results

Findings must be described without comment. The same data or information given in a Table must not be repeated in a Figure and vice versa. It is not acceptable to repeat extensively the numbers from Tables in the text or to give lengthy explanations of Tables or Figures.

## Discussion

Statements from the Introduction and Results sections should not be repeated here. The final paragraph should highlight the main conclusions of the study. Names of funding organizations should be written in full.

## References

In the text, references should be identified using numbers in square brackets in which they appear consecutively. The titles of journals should be abbreviated according to the style used in Index Medicus. A general guide limit the number of references to 25 for original articles, to 6 for case reports and to 85 for reviews. For articles with 1 to 6 authors, list all authors. For articles more than 6 authors, list the first 6 authors followed by "et al.". Do not use individual sets of parentheses for citation numbers that appear together, e.g., [2,3,5-9], not [2],[3],[5]-[9]. For other styles of publication or Internet articles, see [http://www.nlm.nih.gov/bsd/uniform\\_requirements.html](http://www.nlm.nih.gov/bsd/uniform_requirements.html) References should be formatted as follows (please note the punctuation and capitalization)

Journal titles should be abbreviated according to ISI Web of Science abbreviations. Authors are solely responsible for the accuracy and completeness of references.

## Articles in Journals

Özpolat B, Gürpınar ÖA, Ayva EŞ, Gazyağcı S, Miyaz M. The effect of Basic Fibroblast Growth Factor and adipose tissue derived mesenchymal stem cells on wound healing, epithelization and angiogenesis in a tracheal resection and end to end anastomosis rat model. *Turk Gogus Kalp Dama* 2013; 21: 1010-9.

For other styles of publication or Internet articles, see [http://www.nlm.nih.gov/bsd/uniform\\_requirements.html](http://www.nlm.nih.gov/bsd/uniform_requirements.html)

## Tables and Figures

All illustrations (photographs, drawings, graphs, etc.), not including tables, must be labeled "Figure." Figures must be submitted both in the manuscript and as separate files.

All tables and figures must have a caption and/or legend and be numbered (e.g., Table 1, Figure 2), unless there is only one table or figure, in which case it should be labeled "Table" or "Figure" with no numbering. Captions must be written in sentence case (e.g., Macroscopic appearance of the samples.). The font used in the figures should be Times New Roman. If symbols such as  $\times$ ,  $\mu$ ,  $\eta$ , or  $v$  are used, they should be added using the Symbols menu of Word.

All tables and figures must be numbered consecutively as they are referred to in the text. Please refer to tables and figures with capitalization and unabbreviated (e.g., "As shown in Figure 2...", and not "Fig. 2" or "figure 2"). The tables and figures themselves should be given at the end of the text only, after the references, not in the running text.

The resolution of images should not be less than 118 pixels/cm when width is set to 16 cm. Images must be scanned at 1200 dpi resolution and submitted in jpeg or tiff format. Graphs and diagrams must be drawn with a line weight between 0.5 and 1 point.

Graphs and diagrams with a line weight of less than 0.5 point or more than 1 point are not accepted. Scanned or photocopied graphs and diagrams are not accepted.

Charts must be prepared in 2 dimensions unless required by the data used. Charts unnecessarily prepared in 3 dimensions are not accepted.

Figures that are charts, diagrams, or drawings must be submitted in a modifiable format, i.e. our graphics personnel should be able to modify them. Therefore, if the program with which the figure is drawn has a "save as" option, it must be saved as \*.ai or \*.pdf. If the "save as" option does not include these extensions, the figure must be copied and pasted into a blank Microsoft Word document as an editable object. It must not be pasted as an image file (tiff, jpeg, or eps) unless it is a photograph.

Tables and figures, including caption, title, column heads, and footnotes, must not exceed 16x20 cm and should be no smaller than 8 cm in width. For all tables, please use Word's "Create Table" feature, with no tabbed text or tables created with spaces and drawn lines. Please do not duplicate information that is already presented in the figures.

Tables must be clearly typed, each on a separate sheet, and double-spaced. Tables may be continued on another sheet if necessary, but the dimensions stated above still apply.

## Privacy Statement

Names and e-mails will not be shared for any purpose.

## Publisher

The "Current Thoracic Surgery" is the official e-journal of Turkish Society of Thoracic Surgery

Turkish Society of Thoracic Surgery (TSTS)

For more information, please contact

Berkant Özpolat, MD.

Professor of Thoracic Surgery

Editor-in-Chief of Current Thoracic Surgery

Email: [berkantozpolat@yahoo.com](mailto:berkantozpolat@yahoo.com)

[cts@tgcd.org.tr](mailto:cts@tgcd.org.tr)

© Current Thoracic Surgery. All rights reserved.