



Veterinary Journal of Kastamonu University



eISSN: 2822-4922

YEAR: 2023

VOLUME: 2

ISSUE: 1

Veterinary Journal of Kastamonu University

Published twice a year

E-ISSN 2822-4922

Editorial Board

Editor-in Chief

Dr. Musa TATAR

Co Editors in Chief

Dr. Tarık ŞAFAK

Dr. Gülşah GÜNGÖREN

Dr. Selda DURAN YELKEN

Dr. Orhan ÇORUM

Typesetting Editor

Dr. Selda DURAN YELKEN

Language Editors

Dr. Mustafa HİTİT

Dr. Veysel DOĞAN

Statistics Editor

Dr. Kenan Çağrı TÜMER

Layout Editor

Süleyman YÜKSEL

Journal Secretary

Dr. Mübeccel ATELGE

Correspondence

Kastamonu Üniversitesi, Veteriner Fakültesi, Kuzykent
Kampüsü, 37150-Kastamonu/TÜRKİYE

Tel: +90 366 280 5112,

E mail: vetjournal@kastamonu.edu.tr

URL:

<https://veteriner.kastamonu.edu.tr/index.php/tr/dergi>

<https://dergipark.org.tr/tr/pub/vetjku>

Publication Type: Common periodicals and peer-reviewed

© Veterinary Journal of Kastamonu University

All rights reserved. All or part of this Journal, or some or all of the scientific studies in the Journal, cannot be reproduced or published electronically, mechanically, by photocopy, or by any recording system without the written permission of the Dean of the Faculty of Veterinary Medicine of Kastamonu University.

Advisory Board

Dr. Abdullah KAYA, Wisconsin State University, United States of America

Dr. Ali RİŞVANLI, Kyrgyzstan-Turkey Manas University, Kyrgyzstan

Dr. Alparslan COŞKUN, Sivas Cumhuriyet University, Türkiye

Dr. Arabela Viana, Universidade Federal de Viçosa, Brezilya

Dr. Arlindo Moura, Universidade Federal do Ceará, Brezilya

Dr. Barış Atlay USLU, Sivas Cumhuriyet University, Türkiye

Dr. Beste DEMİRCİ, Kastamonu University, Türkiye

Dr. Ejaz AHMAD, Bahauddin Zakariya University, Pakistan

Dr. Elçin GÜNAYDIN, Kastamonu University, Türkiye

Dr. Elif DOĞAN, Kastamonu University, Türkiye

Dr. Emrah Hicazi AKSU, Kastamonu University, Türkiye

Dr. Erdogan MEMİLİ, Prairie View A&M Uni., United States of America

Dr. Fırat DOĞAN, Hatay Mustafa Kemal University, Türkiye

Dr. Funda TERZİ, Kastamonu University, Türkiye

Dr. Hakan ÖNER, Burdur Mehmet Akif Ersoy University, Türkiye

Dr. H. Abdirashit NAZİRBEKOVİCH, Osh State University, Kyrgyzstan

Dr. Hasan ALKAN, Selçuk University, Türkiye

Dr. Hüseyin Serkan EROL, Kastamonu University, Türkiye

Dr. Kenan Çağrı TÜMER, Kastamonu University, Türkiye

Dr. Mehmet CAN, Balıkesir University, Türkiye

Dr. Mehmet Cemal ADIGÜZEL, Atatürk University, Türkiye

Dr. Mehmet KÖSE, Dicle University, Türkiye

Dr. Mehmet Saltuk ARIKAN, Fırat University, Türkiye

Dr. Mitra Mazinani, Washington State University, United States

Dr. Murat POLAT, Kastamonu University, Türkiye

Dr. Musa TATAR, Kastamonu University, Türkiye

Dr. Mustafa HİTİT, Prairie View A&M University, United States

Dr. Mübeccel ATELGE, Kastamonu University, Türkiye

Dr. Mücahit KAHRAMAN, Harran University, Türkiye

Dr. Naseer A. Kutchy, St. George's University, Grenada

Dr. Onur CEYLAN, Selçuk University, Türkiye

Dr. Orhan ÇORUM, Hatay Mustafa Kemal University, Türkiye

Dr. Osman Sabri KESBİÇ, Kastamonu University, Türkiye

Dr. Özgür KAYNAR, Kastamonu University, Türkiye

Dr. Özlem DURNA AYDIN, Dicle University, Türkiye

Dr. Ruslan SALIKOV, Kyrgyzstan-Turkey Manas University, Kyrgyzstan

Dr. Sanan RAZA, University of Veterinary & Animal Sciences, Pakistan

Dr. Shamimul Hasan, Mississippi State University, USA

Dr. Sinan KANDIR, Çukurova University, Türkiye

Dr. Tarık ŞAFAK, Kastamonu University, Türkiye

Dr. Uğur ÖZENTÜRK, Atatürk University, Türkiye

Dr. Umair AHSAN, Burdur Mehmet Akif Ersoy University, Türkiye

Dr. Zafer BULUT, Dokuz Eylül University, Türkiye

Dr. Zahid NASEER, Pir Mehr Ali Shah Arid Agriculture University, Pakistan

Veterinary Journal of Kastamonu University

Volume 2 • Issue 1 • 2023

Published 30.06.2023

CONTENTS

Research Article

The effects of modifications at milk and incubation conditions on the production of cow's kumiss

Murat GÜLMEZ, Kübranur YILDIZ BAYHAN, Sefa ÜNER 1

Can thermal imaging technique be an effective method to assess pulp health in dogs?: a pilot study

Candemir ÖZCAN, Kürşad YİĞİTARSLAN 21

Case Report

Operative approach to a case of perineal laceration in an Arabian mare

Öznur YILMAZ, Tarık ŞAFAK, Mehmet Akif KILINÇ, Burak Fatih YÜKSEL, Kerem ERCAN, Ali RİŞVANLI 33

Trichodectes pinguis (Phthiraptera: Ischnocera: Trichodectidae) and *Haemaphysalis erinacei* (Acari: Ixodida: Ixodidae) infestation on brown bears in Erzurum province

Rıdvan KİRMAN, Muzaffer AKYÜZ, Veysel DOĞAN 39

Evaluation of common liver masses and clinical and operative findings in a dog

Ali Said DURMUŞ, Eren POLAT 44

Review

Aluminum and toxicity

Sedat GÖKMEN, Burcu GÜL 52

The effects of modifications at milk and incubation conditions on the production of cow's kumiss

Murat GÜLMEZ^{a,*}, Kübranur YILDIZ BAYHAN^b, Sefa ÜNER^c

Siirt University, Faculty of Veterinary Medicine, Department of Food Hygiene and Technology, Siirt, Türkiye.

^aORCID: <http://orcid.org/0000-0003-3888-6815>; ^bORCID: <http://orcid.org/0000-0002-9740-9843> ^cORCID: <http://orcid.org/0000-0003-0416-7476>

*Corresponding author: mgulmez@hotmail.com

Received 05.12.2022 - Accepted 31.03.2023 - Published 30.06.2023

Abstract: This study was carried out with the aim of improving the knowledge on the applicability of cow's milk to prepare a mare's kumiss like drink. Commercial mare's kumiss was purchased and analysed in parallel to the cow's milk kumiss and used as inoculant for making cow's milk kumiss. Cow's milk was used for making Control samples. Nevertheless, Control samples of cow's milk kumiss were more viscous and prosaic for a kumiss drink. The commercial mare's kumiss was not also liked by the panel members. The most admired sample determined to be modified cow's milk kumiss. Modification made as addition of 50% water to full-fat cow's milk, then fortification of this milk with 3.8% (w/v) lactose and 0.9% (w/v) whey protein appeared to be more valuable for a pleasant-tasting kumis-like dairy product development. As inoculation culture, mare's kumis or kumiss like sample developed in the study were found to be used at a rate of 5%. Also, a consortium of dominant bacterial and yeast culture selected from mare's kumiss appeared to be applicable for making a kumiss like cow's milk drink. Static incubation of milk at 28 °C for 24 h, and 4.4 pH and 0.7% lactic acid levels after incubation; also, a pH of 3.5 to 4, a maximum of 1.5% lactic acid at the 14th day of cold storage appeared to be good values for such a drink. Nevertheless, more detailed studies are needed to develop cow's milk kumiss or kumiss-like drinks.

Keywords: Cow's milk, kumiss, kumiss culture, modified milk, process.

Süt ve inkübasyon koşullarında yapılan değişikliklerin inek kımızı üretimine etkileri

Özet: Bu çalışma, inek sütünün kırmızı benzeri kısrak içeceği yapımında kullanılabilirliği konusundaki bilgileri artırmak amacıyla yapılmıştır. Ticari kısrak kımızları satın alınarak inek sütü kımızları ile paralel olarak analiz edilmiş ve inek sütü kımızlarının yapımında kültür olarak kullanılmıştır. Kontrol örnekleri yapmak için inek sütü kullanıldı. Bununla birlikte, inek sütü kırmızı kontrol numuneleri, bir kırmızı içeceği için daha viskoz ve yavandı. Ticari kısrak kımızı da panel üyeleri tarafından beğenilmedi. En çok beğenilen örneğin modifiye inek sütü kırmızı olduğu belirlendi. Tam yağlı inek sütüne %50 su ilavesi şeklinde yapılan modifikasyonun ardından bu sütün %3,8 (w/v) laktoz ve %0,9 (w/v) peynir altı suyu proteini ile zenginleştirilmesinin hoş içimli bir kırmızı için daha uygun olduğu görüldü. Mayalama kültürü olarak kısrak kımızı veya çalışmada geliştirilen kırmızı benzeri örneğinin %5 oranında kullanılabileceği tespit edildi. Ayrıca, kısrak kımızlarından seçilen baskın bakteri ve maya kültüründen oluşan bir konsorsiyumun kırmızı benzeri inek sütü içeceği yapmak için uygun olduğu da ortaya çıktı. Sütün 28 °C'de 24 saat statik inkübasyonu ve inkübasyondan sonra pH 4,4 ve %0,7 laktik asit seviyeleri; ayrıca, soğuk muhafazanın 14. gününde pH 3,5 ila 4, maksimum %1,5 laktik asit böyle bir içecek için iyi değerler olarak tespit edildi. Ancak inek

sütü kımız veya kımız benzeri içeceklerin geliştirilmesi için daha detaylı çalışmalara ihtiyaç vardır.

Anahtar kelimeler: İnek sütü, kımız, kımız kültürü, modifiye süt, proses.

Introduction

Food safety and accordingly public health may be at risk due to microbiological and chemical contaminants (Sevilmiş, 2016). Tourists are particularly affected by this situation (Erdem & Gündođdu, 2018a). The majority of diarrheal diseases are related to food hygiene (Ucar et al., 2016). It is known that probiotics and fermented milk products such as kefir and kumiss support intestinal health and general health (Behera et al., 2017). Drinkable dairy products are produced all over the world and these products such as kumiss are consumed in different ways in every society. These products have created tastes in the course of history and have become special for producer society (Marsh et al., 2014).

It has been reported that mare's milk contains properties similar to human milk in terms of nutritional value and health benefits, and no side effects have been observed, although it has been consumed for thousands of years (Musaev et al., 2021). Kumis is an acidic and slightly alcohol-containing dairy product that has been traditionally produced by Central Asian communities using mare's milk since ancient times (Tegin & Gönülalan, 2014a). Kumis has started to become widespread outside of these communities as well (de Melo Pereira et al., 2022). As the positive effects of functional dairy products such as kumiss and kefir on health are revealed, their prevalence is accelerating (Shaimardanova, 2012; Afzaal et al., 2021). Another feature of kumis is that it offers the opportunity to meet the water needs in rural areas where access to potable water is difficult. Kumis is a product that also meets the vitamin C needs of people such as herdsmen who do not have the opportunity to consume vegetables and fruits in the Asian steppes for a long time (Dugan, 2009; McGuire, 2017). Today, kumiss is used as a product that supports health tourism (Erdem & Gundogdu, 2018b). There are researchers who describe kumiss as a unique beverage (Yangilar et al., 2016). It has been reported that kumiss has significant health gains as a result of studies performed on experimental animals (Eliş Yildiz et al., 2015; Gülmez & Atakişi, 2020). Studies on both the nutritional and therapeutic properties of kumis have been compiled and presented in great detail (Dhewa et al., 2015).

Horse milk has its own characteristics (Hinz et al., 2012). Since the traditional form of kumis is made from mare's milk, it has high lactose and low protein content (Nurtazin et al., 2015). However, where kumiss has the potential to become widespread, sufficient mare's milk cannot be supplied in commercial kumiss production, milk of the other farm animals, especially

cow's milk, which is more economically produced in every month of the year, is recommended for kumiss production (Küçükçetin et al., 2003). It is not easy to obtain the characteristics of traditional kumiss by using cow's milk. For this reason, when milk other than mare's milk is used, it has been suggested that the milk should be modified as to mare's milk. There are differences among researchers in terms of material, method and starter cultures used for cow's milk kumiss production (Malacarne et al., 2002; Liu et al., 2019; Li et al., 2020; Rakhmanova et al., 2021).

Kumiss culture consists of a consortium of bacteria and yeasts. The dominant culture consists of *lactobacilli*, *lactococci*, *leuconostocs* and yeasts (*Saccharomyces* sp., *Candidia* sp. and *Torula* sp.) (Sun et al., 2010). Along with these microorganisms, *Streptococcus* (*Sc.*) and *Enterococcus* (*Ec.*) *faecium* were also isolated in mare's milk (Ying et al., 2004). It has been reported that while *Enterobacter* and *Rhodotorula* constitute the dominant flora in mare's milk, *Lactobacillus* and *Dekkera* are the dominant flora during the formation of kumiss, and the flora and the metabolites that give its character to kumiss, differ (Xia et al., 2021). *Lactobacillus*, *Lactococcus*, *Acetobacter*, *Streptococcus*, *Serratia* and *Leuconostoc* bacteria; and the fungi *Kazachstania*, *Kluyveromyces*, *Trichosporonaceae*, *Pichia*, and *Candida* were predominantly isolated in traditionally produced mare's milk kumiss (Wang et al., 2008). It has previously been reported that 112 volatile substances detected in the same study were mainly produced by 4 groups of bacteria (*Lactobacillus*, *Acetobacter*, *Lactococcus* and *Pseudomonas*) and 2 groups of fungi (*Kazachstania* and *Candida*). Yao et al. (2017) have identified *Lc. otakiensis*, *Sc. macedonicus*, and *Ruminococcus torques*. The use of raw mare's milk in production causes the diversity of the flora. So, the use of pasteurized milk in commercial production has been suggested (Rakhmanova et al., 2021). Researches continue to achieve the technological development that will contribute to the spread of commercial kumiss production (Kozhahmetova & Kasenova, 2013; Maksyutov et al., 2013). The traditional form of kumis must be produced from horse milk. However, due to the inadequacy of horse milk, it shows that other most abundantly produced milks can be used in the production of kumiss or a kumiss like drink. As can be understood from the summary information given above, it cannot be claimed that such a commercial product is produced and consumed worldwide after the studies on the production of kumiss from cow's milk (Kırdar & Tegin, 2022). After that, more studies will be done probably to develop a cow's milk kumis or a kumiss like drink that is appropriate to produced and consumed at more countries. In this study, it was aimed to find out the effect of modification of UHT cow's milk, incubation conditions (static and/or shakingly) and

inoculant on the acidity, pH and flavour development after incubations and at a 14 d of cold storage time period.

Materials and Methods

Preparation of milk samples: UHT cow's milk purchased from a local market was transferred aseptically in autoclaved (121 °C for 15 min) erlenmayer flasks before use. Unmodified UHT milk was used for making Control samples. Modified samples were diluted by adding autoclaved (121 °C for 15 min) drinking water to the UHT milk at a 1: 1 rate (v/v). Then, the prepared milk samples were modified by adding each of sugars (sorbitol, sucrose, glucose, maltodextrin, inulin and lactose) at a rate of 3.8% (v/w) and/or whey protein (WP, Maybi, Smart code: 058.320.50) at a rate of 0.9% (v/w).

Inoculation: A commercial mare's kumiss (sold as bag of 12 of 200 mL in glass bottle) bought from manufacturer was used as inoculant by adding at a rate of 5% to the prepared milk samples before incubations.

Incubation: Static incubation or one from 5 different shaking procedures (continuous, 30 min shaking at every 3 h, 6 h static + 30 min shaking in every 3 h, 12 h static + 30 min shaking at every 3 h, 12 h static + 12 h continuous) were applied during incubation. All the samples were incubated at 28 °C for 24 h. Then, the samples were kept at 4 °C for 14 d for further analysis.

Instrumental analysis of milk: Analysis of milk and modified milk samples used in the experiments were made by using a milk auto-analyzer (Lactoscan LS, Nova Zagora, Bulgaria).

Acidity: Titratable acidity (lactic acid, %) of milk and kumiss samples were measured by using 0,1N NaOH and phenolphthalein indicator (Sadler & Murphy, 1984).

pH: The pH milk and kumiss samples were measured by using a digital pH meter (Milwaukee, AZ8686).

Coliforms and coagulase positive staphylococci: The reference methods were applied as mentioned by Pouch & Ito (2001) for the analysis of milk and kumiss samples. Briefly, 10 g of each sample was used for making ten-fold serial dilutions in diluted in 90 ml of sterile physiological saline (PS). For coliforms, Violet Red Bile Lactose Agar (VRBLA, Oxoid CM0107) was used. Petri dishes were incubated for 24 hours at 30 °C, the growing pink-red colonies with a pink precipitation ring around were counted. For coagulase positive staphylococci, Baird Parker Agar (BPA, Oxoid, CM1127) plates with Egg Yolk Tellurite Emulsion (Oxoid, SR0054) were used and the plates were incubated at 37 °C for 48 hours.

Black shiny coagulase positive colonies with a diameter of 1.5 – 2.5 mm with a transparent zone around were counted.

Selection and characterization of strains of predominant microflora in kumiss:

Possible starter culture members were selected from Modified Cow's Milk Kumiss (MCMK). The MCMK was obtained at the end of static incubation after adding 50% water, 3.8% lactose and 0.9% WP to cow's milk. Serial dilutions of the sample up to 10^{-7} were prepared. A 100 μ L from each of the last three serial dilution tubes were streaked on 10 parallel petri dishes (Pouch & Ito, 2001). de-Man Rogosa Sharpe Agar (MRS, Merck, Germany) was used for the isolation of lactobacilli and M17 Agar was used for the isolation of lactococci. Petri dishes were incubated at 37 °C for 3 d. (Malacarne et al., 2002; Küçükçetin et al., 2003; Rakhmanova et al., 2021). For the isolation of yeasts, the petri dishes of Potato Dextrose Agar (PDA) pH adjusted to 3.5 with 10% lactic acid were inoculated and incubated for 4 d at 24 °C (Hinz et al., 2012). Colonies were randomly picked from the plates, and each colony was purified on its own agar plate (MRS, M17 or PDA). A total of 300 colonies, 100 colonies from each, were selected on MRS, M17 and PDA agar. Gram positive, catalase negative, citrate negative bacteria that can utilise lactose, fructose, sucrose, glucose, maltodextrin and inulin were selected from these colonies. Among the yeasts, those that were catalase positive, citrate negative and able to use lactose, fructose, sucrose, glucose, maltodextrin and inulin were selected. Carbohydrate fermentation tests were made according to Bansal et al. (2013) and Reiner (2012) using Phenol Red Carbohydrate Broth. Ten colonies belonging to each petri dish were selected. So, each group of 10 isolates were made. Then, each group strains were multiplied by incubating them together in their own broth (MRS, M17 or PDA) for 24 hours at 30 °C. One mL from each of these broth cultures was inoculated to 100 mL of milk by making different combinations of MRS, M17 and PDA colonies. The most liked sample was used as inoculum for the next kumiss production. The process was repeated three consecutive times. Colony selection and isolation procedures reported above were repeated from the most favored sample. Finally, selected 15 isolates, 5 from each of the MRS, M17 and PDA colonies, were propagated and used as kumiss milk inoculant as stated above. Identifications of the 15 colonies were made using a mass spectrometer “Matrix-Assisted Laser Desorption/ Ionization - Time of Flight (MALDI-TOF)” system (Liu et al., 2019).

General liking scores: General liking scores at kumiss samples were performed by six panel members as mentioned by Yao et al. (2017).

Statistical analysis: The mean values of the samples and the standard deviation values between the samples were calculated by using the Microsoft Excel program. Data were

analyzed using the general linear model procedure in SAS soft-ware (Sun et al., 2010). Differences between the samples were determined using the least significant difference (LSD) test. A probability level of $P < 0.05$ was considered statistically significant.

Results

The results of the analyzes performed on the cow's milk and modified cow's milk samples before inoculations are given in the Table. There was no information in the user manual of the device that such an analysis could be made. But, we trained to test them by using milk analyzer. Sugars and WP added to UHT milk made it difficult for the milk analyzer to read. So, only pH and acidity values were considered in this study. It was observed that the pH value decreased by 0.3 units when water and sugar added to the milk, and increased by 0.3 units when WP together with water and sugar added (Table).

Table. Analysis of milk and modified milk samples used in the experiments.

Additives	Density	Conductivity (ms/cm)	Freezing point	Water, %	Nonfat dry mater, %	Fat, %	Protein, %	Lactose, %	Minerals, %	pH	Lactic acid, %
Water: milk 1:1 (v / v)											
Lactose 3.8%, (w / v)											
Whey protein (WP), 0.9% (w/v)											
UHT cow's milk (as Controls)	26	5.6	0.5	82	7.6	3.2	2.8	4.2	0.6	5.7	0.31
Milk + water	15	3.9	0.3	49	4.4	1.7	1.6	2.4	0.4	5.4	0.23
Milk + water + lactose	21	3.7	0.4	31	5.9	1.9	2.2	3.2	0.5	5.2	0.23
Milk + water + WP	15	3.6	0.3	49	4.5	1.8	1.6	2.4	0.4	6.0	0.24
Milk + water + lactose+ WP	20	3.1	0.3	33	5.8	1.5	2.1	3.2	0.5	6.1	0.23

The study was conducted at 7 consecutive steps. No coliforms or coagulase positive staphylococci were detected in the samples. The acidity values were given all the steps of the study while pH was only given at the 4, 6 and 7th steps (Figure 4b, 6b and 7b), and general liking scores at the 6 and 7th steps (Figure 6c and 7c).

On the 7th d of cold storage, the acidity (L.a.%, mean \pm SD) was 0.52 ± 0.07 in the samples that did not add water to the milk (Figure 1), while it was 0.95 ± 0.08 in the samples that water and sugar added (Figure 2), and 1.45 ± 0.1 in the samples that water, sugar and WP added (Figure 3). These average values of each group are not given separately. There was no effect of shaking in terms of acidity development between the groups in the first 3 steps of the study (Figure 1-3) ($P > 0.05$). There was no significant difference between the samples made by addition of different sugars and whey protein. Although not obvious, it was observed that the

addition of glucose had a greater effect on the development of acidity (Figure 1-3). It was observed that the addition of water, sugar and WP to the samples supported the fermentation. The taste panel members found the kumiss samples that made by using non-diluted milk samples to be very thick, difficult to drink and tasteless even after the 7 d of cold storage (data not shown).

On the 7th d of cold storage, the mean pH value was 5.68 ± 0.13 in the sample that did not add water to the milk. Also, 4.79 ± 0.04 in the samples that added water and sugar, and 4.68 ± 0.03 in the samples that added water, sugar and WP. There was no effect of shaking in terms of pH development between the groups ($P > 0.05$). No significant pH change was observed between the samples that different sugars addition. The addition of water, sugar and WP together to the samples supported pH reduction ($P < 0.05$).

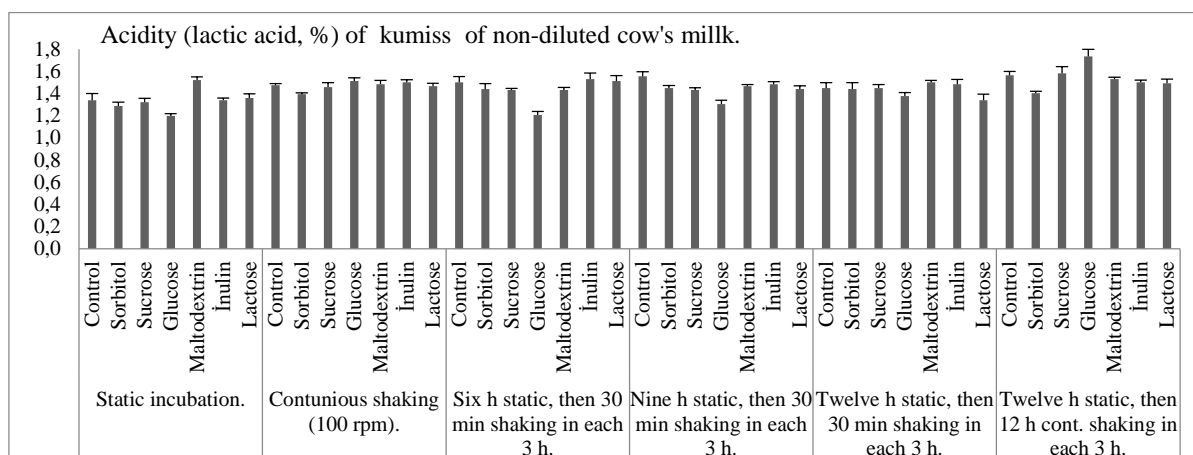


Figure 1. Acidity (lactic acid, %) of kumiss samples that made from non-diluted but sugar added milk samples and incubated in 6 different ways, then maintained at 4 °C for 7 d.

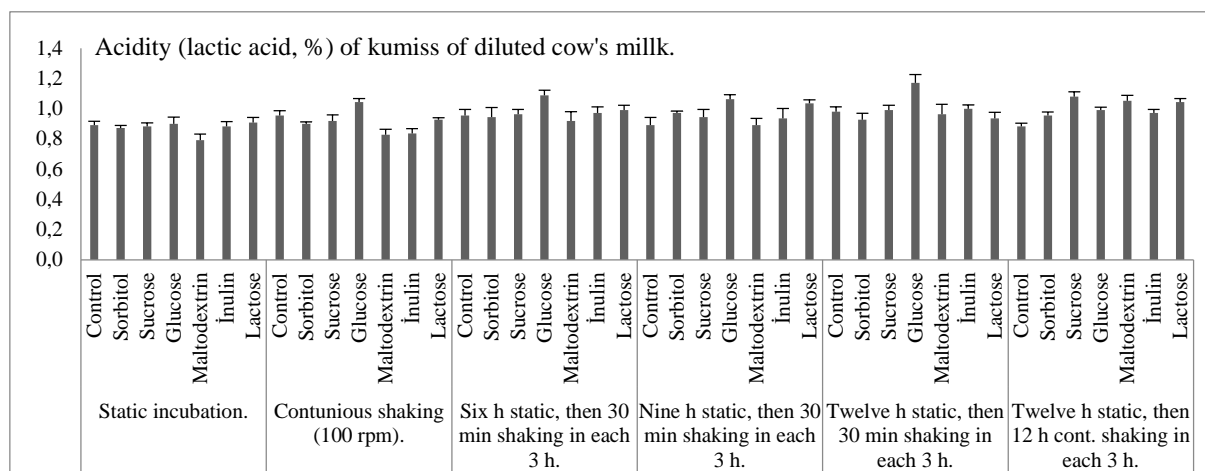


Figure 2. Effect of modification of cow's milk (50 mL) by adding water (50 mL) and each of 6 sugars (3.8 g) on the acid development after incubation.

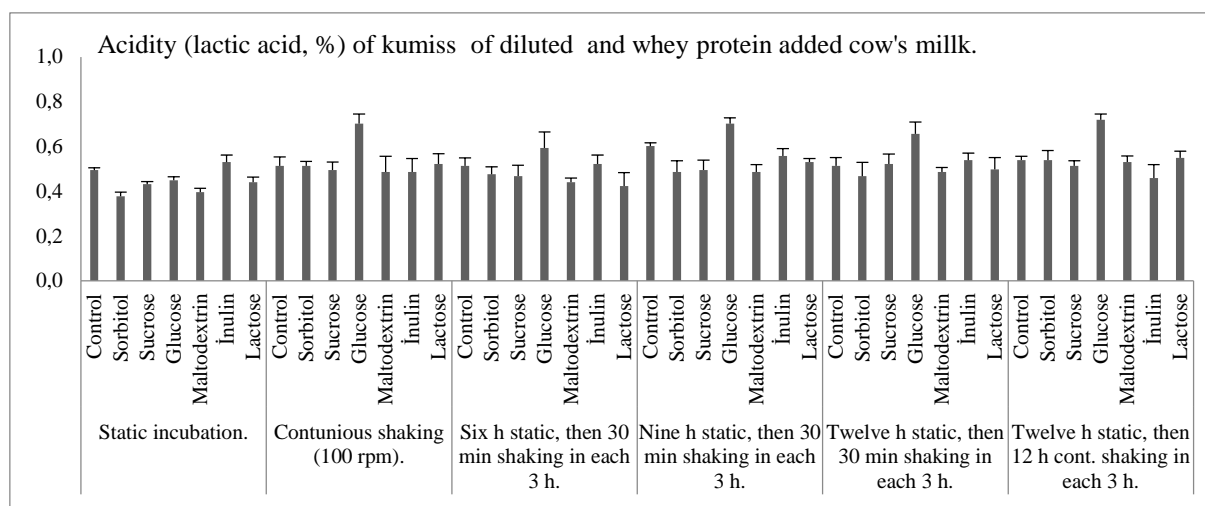


Figure 3. Effect of modification of cow's milk (50 mL) by adding water (50 mL), each of 6 sugars (3.8 g) and whey proteins (0.9 g) on acid development of the samples after incubation.

In the 4th stage of the process development, 16 different samples inoculated with 2 different inoculants and incubated with static or shaking process were compared with the Control samples. Acidity, pH and sensory analyzes were performed at the 1st h, 7th d and 14th d of cold storage (Figure 4a, b). Acidity values in cold storage were higher in samples inoculated with fresh cow's kumiss (Figure 4a). In addition, it was observed that the addition of lactose and WP had a positive effect on acidity in both Control and modified samples. Acidity development continued during the 14 d of cold storage. However, the increase in acidity in the modified samples was less than in the Control samples. There was no effect of shaking in terms of acidity development between the groups. Sugar type or shaking regime were not effective on the acid development. The effect of lactose and WP on the acidity of 7th and 14th d was clearly demonstrated ($P < 0.05$). It was observed that the addition of water, sugar and WP to the samples supported the fermentation. The mare's kumiss culture adapted to cow's milk was used as inoculant in repeated incubations, making it more effective in acidity development. Control samples were quite viscous and tasteless even after shake incubations.

In the 1st h, 7th d and 14th d of cold storage, pH in both Control and MCMK samples were found to be lower in samples fermented with new inoculum than kumis inoculum (Figure 4b). It was observed that adding lactose and WP to the samples had a positive effect on pH ($P < 0.05$). The pH became more stable with the addition of lactose and WP in all samples in 14th d of cold storage. The pH decrease in the experimental samples was less than in the Control samples. There was no effect of shaking in terms of pH decrease between groups. It was observed that the addition of water, lactose and WP to the samples supported the pH decrease ($P < 0.05$).

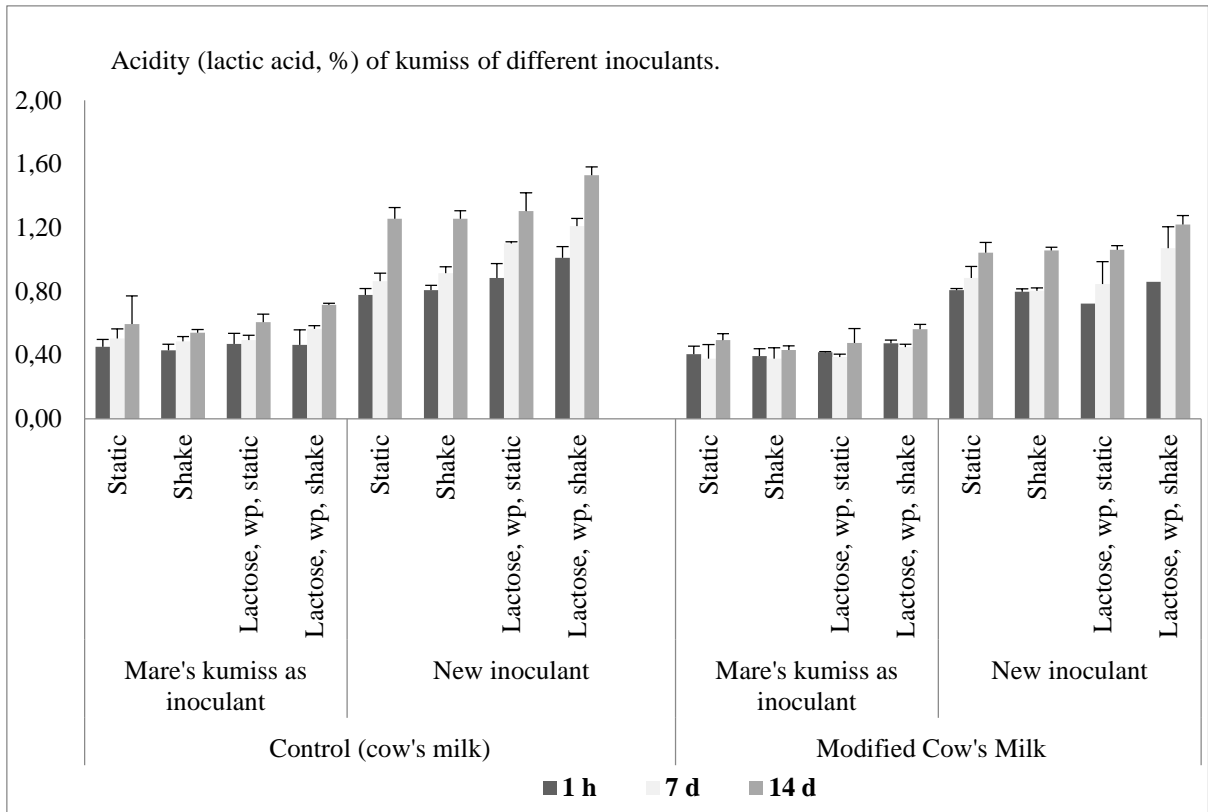


Figure 4a. Effects of addition of water, lactose and whey proteins (WP) to cow's milk inoculated with mare's kumiss or newly developed inoculum: Acidity (lactic acid, %) after static and shake incubation.

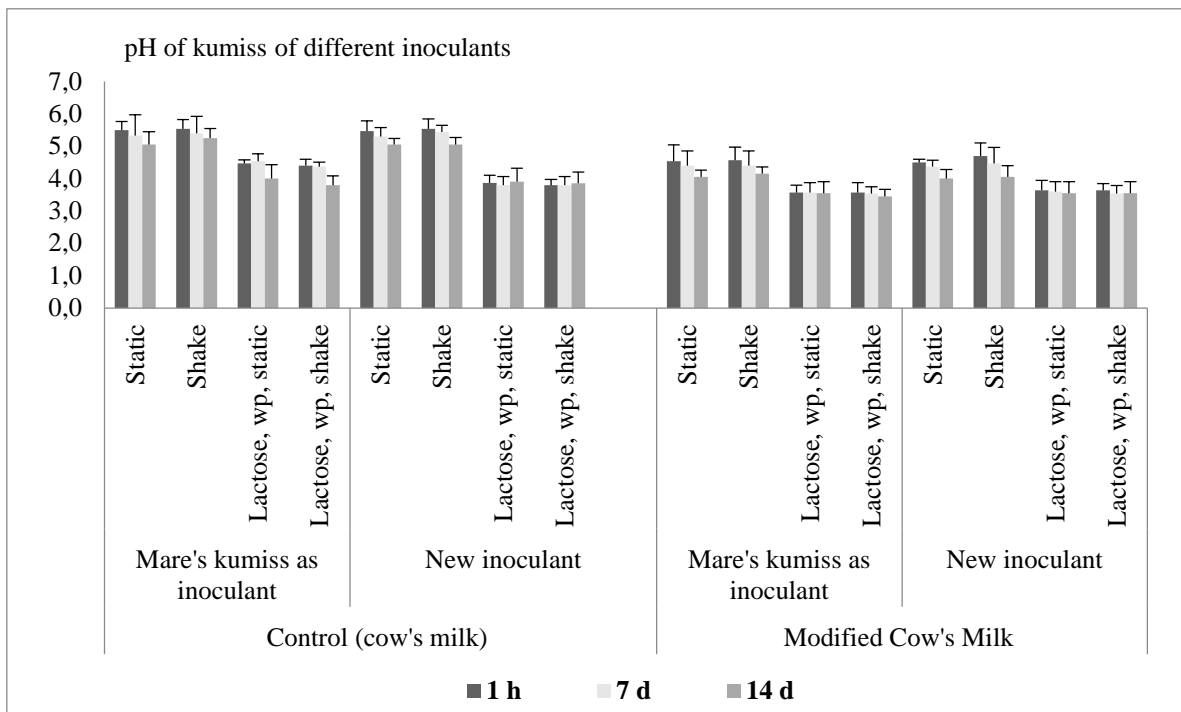


Figure 4b. Effects of addition of water, lactose and whey proteins (WP) to cow's milk inoculated with mare's kumiss or newly developed inoculum: pH after static and shake incubation.

As can be seen in Figure 5, the acidity values of the samples made with modified cow's milk increased gradually in the 14th d cold storage. The highest acidity value (1.34 ± 0.13) was observed in samples of cow's milk fermented with new inoculant and kept in cold storage for 14 d. Acidity were found in modified cow's milk fermented with fresh yeast as 1.1 ± 0.8 in cow's milk fermented with mare's kumiss as 0.61 ± 0.07 and in modified milk fermented with mare's kumiss as 0.49 ± 0.05 . Observation of $1.1 \pm 0.12\%$ acidity on the 14th d of cold storage in the samples of modified cow's milk inoculated with new inoculum indicated that the product will have a longer shelf life. As a result of taste panel, it was seen that the samples made with cow's milk were thick and tasteless. When dilution was made by equal amount of water to the kumiss, the samples were become more tasteless (data not shown).

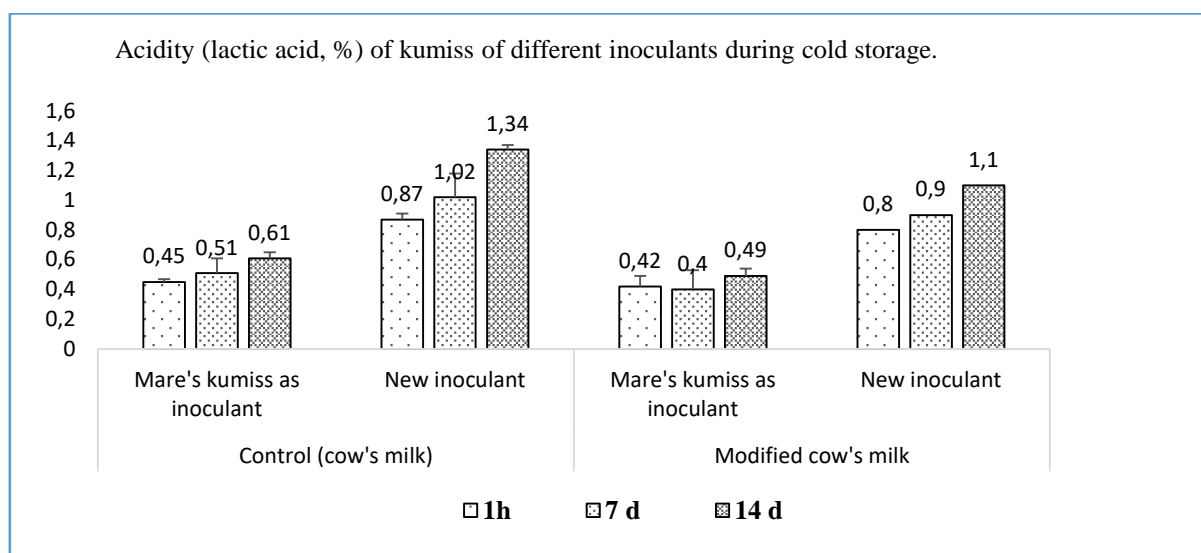


Figure 5. Effect of different inoculants on acid development in 4 different kumiss samples at 1st h, and 7th and 14th d of cold storage, 4 °C.

In the 6th step of the process development, the most admired sample (the MCMK sample) in the previous step (Step 5) was used as inoculant at a rate of 5%. Static incubation was applied to the samples and analyzes were made at the 1st h and 7th and 14th d of the cold storage (Figure 6a, b, c).

It was observed that adding lactose, WP or both lactose and WP to the water added milk appeared to be important for the development of acidity during cold storage, which was not obvious at the end of the incubation. The best acidity development was observed on the 14th d of cold storage in the samples added water, lactose and WP (1.1 ± 0.1) (Figure 6a).

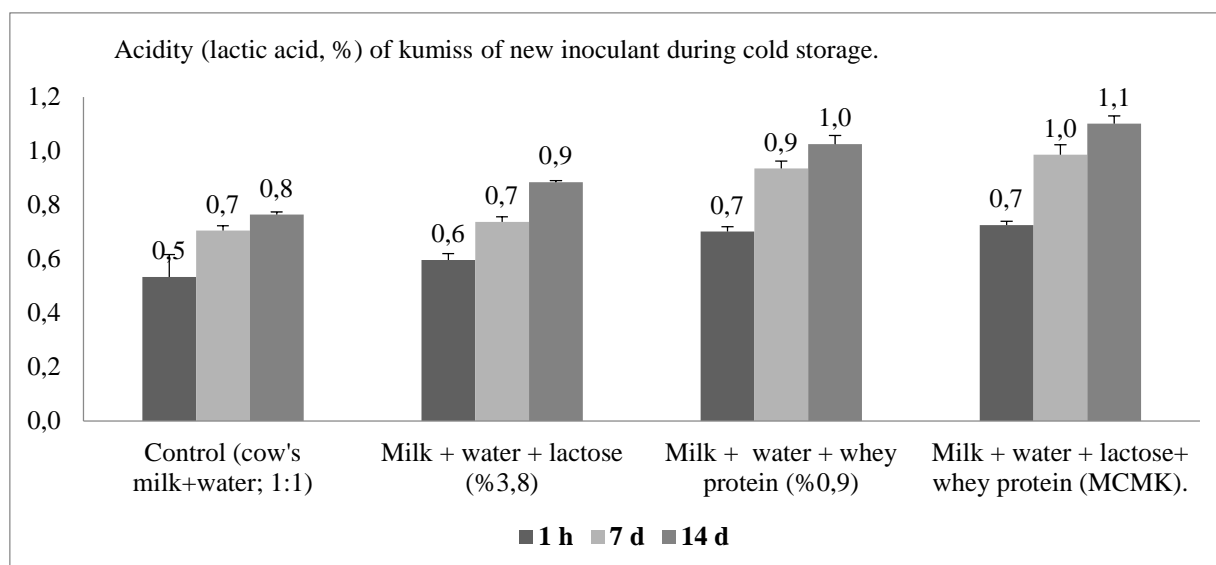


Figure 6a. The acidity (lactic acid, %) changes of kumiss samples during cold storage, 4 °C.

No difference was observed in terms of pH change in the kumiss samples produced after adding lactose and/or WP to the milk to which water was added. However, on the 7th d of cold storage, the highest pH decrease was observed in the samples added together with lactose and WP. This change did not persist and no significant difference was observed between the groups in the 7th and 14th cold storage d (Figure 6b).

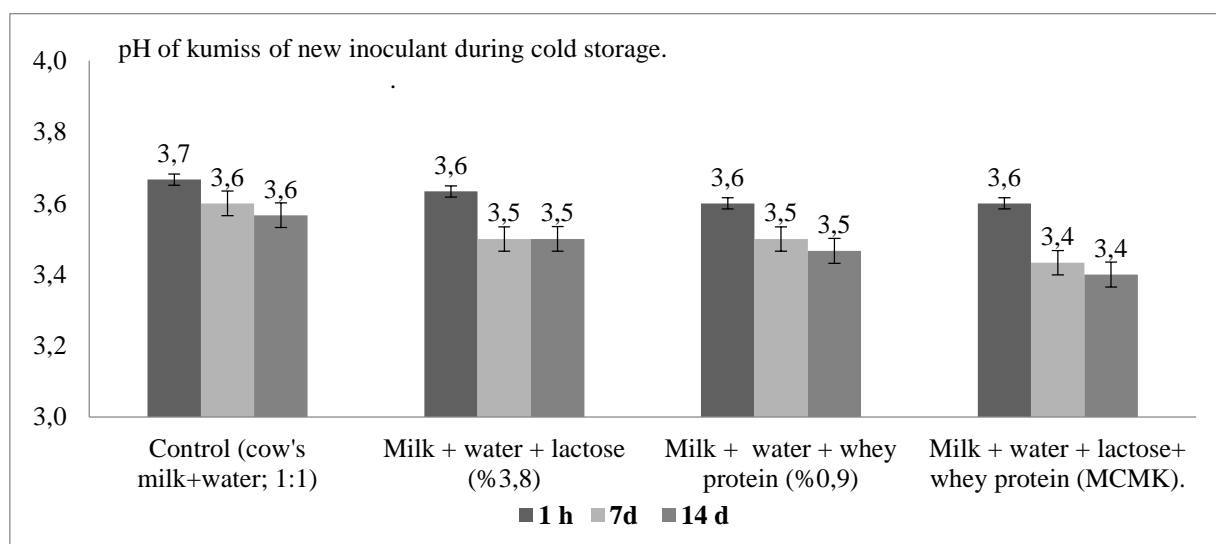


Figure 6b. The pH changes of kumiss samples during cold storage, 4 °C.

The general liking scores of the samples are given in Figure 6c. Control samples were liked the least and the MCMK samples the most. The panelists sought this taste because they were familiar with the taste of buttermilk. Control samples were reported to be thick, sticky,

and tasteless. It was reported that some of the water added samples were bitter and tasteless. Adding lactose to milk together with water created a sourer taste, and adding WP created a more aromatic and tart taste.

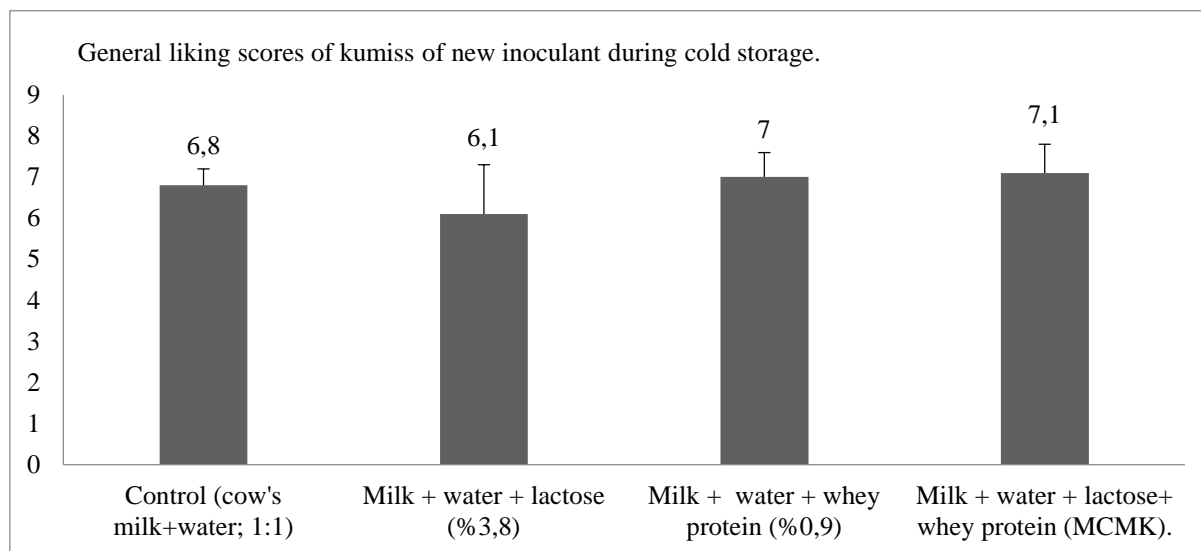


Figure 6c. General liking scores of the different kumiss samples during cold storage, 4 °C.

The mare's kumiss that purchased from a commercial sell point was not liked by the panel members. Nevertheless, MCMK has found to be more aromatic and attractive for drink. All the panelists reported that there was no similarity between this new product (MCMK) and mare's kumiss, but that they would prefer to consume this product over mare's kumiss (data not shown). After this step, 4 different inoculants were prepared by selecting 5 each from MRS, M17 and PDA colonies. After the obtained MCMK samples were kept at 4 °C for 1 h, acidity, pH and general liking tests were performed (Figure 7). The results of the analysis were compared with the results obtained from the commercial mare's kumiss. Horse kumiss had a general liking score of 3.4 ± 2.1 and panelists did not like the acrid and bitter taste in it. The M17 + PDA sample had the lowest appreciation score, with the highest acidity and lowest pH values. MRS + M17 + PDA samples containing 15 isolates were the best samples from other samples in terms of acidity development, pH decrease and general liking score.

As a result of Maldi-Toff analysis, 9 out of 15 isolates could not be identified. Two of the isolates were *Lb. bulgaricus*, 2 of them *Str. thermophilus*, one was *Saccharomyces* sp. and the other was *Torula* sp.

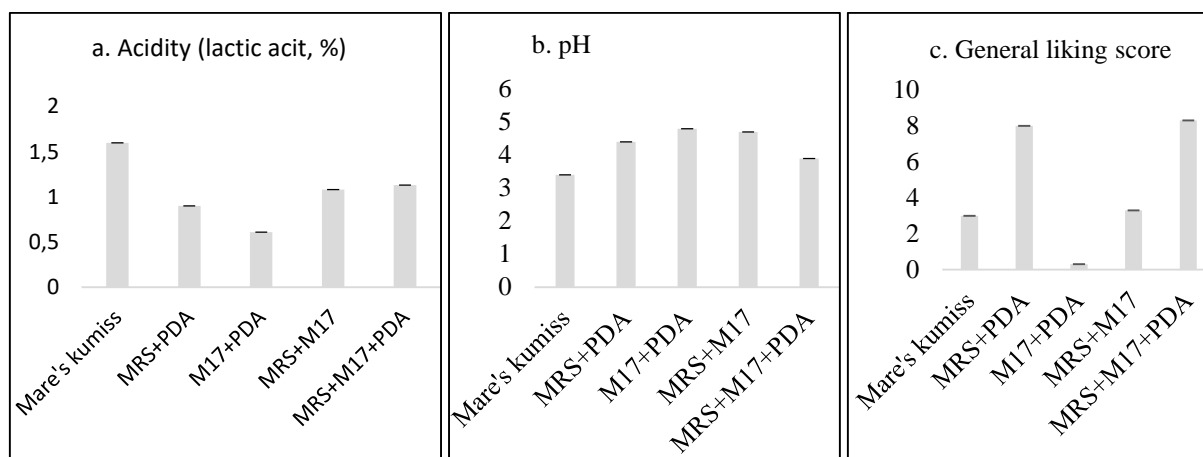


Figure 7. Acidity (lactic acid, %) (a), pH (b) and general liking scores (c) of kumiss samples inoculated with consortia of different strains of bacteria and yeasts.

*Mare's kumiss; a commercial product purchased for using as benchmark sample. Predominant five isolates taken from each MRS; de-Man Rogosa Sharpe agar, M17; M17 agar, PDA; Potato dextrose agar plates inoculated from kumiss samples.

Discussion

Kumis is a product developed by the Central Asian and Caucasian communities in the historical process and produced and traded in homes and industry until today (Tegin & Gönülalan, 2014b). It is known that mare's milk is different from cow, sheep, goat and buffalo milk (Hinz et al., 2012). It is similar to albuminous milks such as human and goat milk in terms of serum proteins and high lactose content (Hinz et al., 2012). It is known that more than a century ago, products obtained as a result of fermentation of cow's milk with kumiss instead of mare's milk are used in the treatment of sick and weak individuals (George et al., 1872; Dhewa et al., 2015; Musaev et al., 2021). It has been reported that kumiss has the potential to be consumed widely in other communities (Yangilar et al., 2016; de Melo Pereira et al., 2022). However, the biggest reason limiting this potential is the inability to produce sufficient mare's milk (Shaimardanova, 2012; Afzaal et al., 2021). Efforts are constantly being made to produce kumiss by using other milks, especially cow's milk, which is the most abundant milk in the world. Legielski (1874) has mentioned that soft kumiss, hard kumiss and diabetic kumiss are made from cow's milk. In this study, although mare's kumiss was not liked by the panelists, MCMK was liked.

In some studies, kumiss was produced without adding water to cow's milk (Malacarne et al., 2002; Rakhmanova et al., 2021). Modification from the cow's milk has been made in different ways. The water ratio that add to milk is not similar in studies (Özer, 1997; Teichert et al., 2020). In this study, after adding water to milk at a ratio of 1: 1, 3.8% lactose and 0.9% WP were added to increase lactose to 6% and WP to 1.2%, as in mare's milk. We could not

find any other study that modified cow's milk in this way. Therefore, comparing the findings of this study with the findings of other studies may not be confirmatory. It has been also stated in the previously made studies that many different parameters may affect one or more quality parameters of kumis (Malacarne et al., 2002; Teichert et al., 2020).

There is no production and consumption of mare's milk in Türkiye. On the other hand, mare's kumiss is produced only by a Kyrgyz family business and sold directly to the consumer. Kumiss obtained from this family business was used as inoculant in the study and as reference sample in taste tests. The acidity of the kumiss we supplied was 1.57 ± 0.1 and the pH was 3.9 ± 0.1 . The samples came in 24 of 250 mL glass bottles in a parcel. It was observed that there was no difference between the samples in the analyzes performed on 3 randomly selected samples. None of the panelists liked these kumiss and refused to drink it. However, one of our students, who is a citizen of Turkmenistan, stated that this kumis, which we do not like, is very tasty, very pleasant and has the same characteristics as the mare's milk kumiss that he is accustomed to drinking in his country. This result showed us that food consumption habits should be taken into consideration more. Even if enough of our MCMK is produced in Türkiye, it will not be easy for its consumption to become widespread. For this reason, it may not be appropriate for mare's kumiss consumers. The MCMK developed in this study, which our panelists liked to drink and defines as a product that does not resemble yoghurt, kumiss or ayran, may not have pleasant taste for some other consumers.

In this study, UHT market milk from the same batch was used. In this way, we have avoided the mistakes that may arise from heating, cooling, homogenization and standardization. Coliform group bacteria and *staphylococci* were not found in milk, commercial kumiss and experimental samples. In this study, MCMK was obtained by adding 5% of kumiss to milk. Then MCMK itself was used as 5% inoculant. Later, the inoculating culture was developed. More than 5% inoculant has been used in traditional kumiss production (Pastukhova & Gerbeda, 1982; Ishii et al., 2014; Wu et al., 2021). Traditional mare's milk is made in the form of increasing the amount by adding raw mare's milk to the kumis made before (Wu et al., 2021). Possibly, thanks to the constantly high acidity value in the product and the continued fermentation of the kumiss dominant culture, the reproduction of harmful bacteria in raw milk is suppressed and the hygienic quality of the product increases as the product is fermented. It is probably possible to use raw milk in this way. However, there are also researchers who report that the use of raw mare's milk in kumiss may be harmful in terms of hygiene and public health (Kınık et al., 2000; Dankow et al., 2006; Pastukhova & Gerbeda, 1982). Probably such a production method is not suitable for commercial kumiss production. It is clear that this

production model will cause difficulties in hygienic and standard production. For this reason, it has been suggested that milk should be pasteurized, as in yoghurt, ayran and kefir, for the standard production (Özer, 1997; Küçükçetin et al., 2003; Zhang et al., 2020).

While there is less protein and fat in the composition of mare's milk than cow's milk, there is more serum protein and lactose (de Melo Pereira et al., 2022). In order to make these values of cow's milk similar to mare's milk, full-fat cow's milk was modified. Values are given in Table. The MCMK is easy to produce, cheap and have the qualities to set an example for technological applications. Very different incubation methods have been used in the production of mare's kumis and other experimental kumiss studies. Shaking incubations were mostly made (Koroleva, 1988; Malacarne et al, 2002). Studies using static incubation have also been made (Küçükçetin et al., 2003). In this study, it was determined that a bitter and prosaic taste was formed in the shaken kumiss samples made after adding water to the cow's milk. These flavors did not occur in the shaken samples of cow's milk without modification. It was seen that excessive shaking would not be appropriate in the samples with added water. Static incubated samples yielded results similar to those produced with static for 12 hours and shaking every 3 hours for 12 hours (Figure 4b). In the light of these results, it was concluded that it would be appropriate to use static incubation because it is more suitable for the industry and economy and probably has a longer shelf life of kumiss.

In the Turkish Food Codex Legislation on Fermented Dairy Products (Legislation No: 2009/ 25), kumiss is stated as “*Lactobacillus delbrueckii* spp. *bulgaricus* and *Kluyveromyces marxianus* cultures are used as fermented milk product”. In this Legislation, although it was not stated that mare's milk should be used in production, no information was given about the milk to be used. The reason for this may be that kumiss is not yet traded in Türkiye. The Legislation may not be fully detailed. The protein content of kumis is not reported in the Legislation. The ethanol content is at least 0.5%. The amount of lactic acid is at least 0.7%, and number of specific microorganisms (cfu/g) is at least 10⁷, the number of added microorganisms (cfu/g) is at least 10⁶ and the number of yeast is at least 10⁴ (cfu/g). Salt content is not reported. The findings obtained from this study were found to be in compliance with the Legislation. The acidity of MCMK was at least 0.7% lactic acid (Figure 1 – 3, 4a, 6a, 7a). The amount of alcohol in the MCMK did not exceed 0.5%. It was observed that the bacteria and yeast contents were in compliance with the criteria reported in the Legislation even on the 14th d of cold storage. In order for the kumis produced in this study to fully comply with the Legislation, it is necessary to increase the amount of alcohol. Alcohol content naturally increases especially in the first week of cold storage (Ishii et al., 2014; Dönmez et al., 2014; Tang et al., 2020). However, on

the 14th d of cold storage in this study, the alcohol rate remained below 0.5%, which was the desired value in the Legislation. Since the alcohol content is not higher than 0.5%, it is not possible to produce and trade this kumis in Türkiye. Because the product does not provide the values required in the Legislation. In this study, it was aimed to produce non-alcoholic kumiss and our findings are suitable for the purpose of our study. It has been reported that *Saccharomyces lactis* is the main yeast producing alcohol in kumiss, there are differences in the amount of alcohol according to the fermentation time, and the amount of alcohol is 1% even in sweet kumis (Li et al., 2020). In this study, samples were taken from low alcohol beer production models (Yaygın, 1994). Salt was not added to the samples for easier evaluation of the resulting flavors.

It has been mentioned that the trade of kumiss will be increased thanks to the development of production technology (Berlin, 1962; Özer, 1997). Küçükçetin (2003) modified cow's milk using the membrane filtration technique and it was reported that the produced kumiss was more popular than mare's milk kumiss. In another study, the shelf-life of the kumiss has been increased (Ender et al., 2006).

In previous studies, similar to our study, kumiss milk has been prepared by adding water, sugar, whey and other supplements to cow's milk (Özer, 1997; Küçükçetin et al., 2003). However, there is no complete similarity and harmony between the studies. Our study is probably most similar to the study by Küçükçetin (2003). The researcher used mare's kumiss as the main inoculant at a rate of 20% to modified cow's milk (90% water, 6.4% WP and 3.6% milk powder). We obtained kumiss from the same farm as the researcher and used as inoculant at first step of the study. In our study, the process was simplified by adding water to cow's milk in equal proportions, adding lactose and WP to make the content look like mare's milk. The researcher reported that mare's kumiss received the highest score in sensory tests. However, in this study, mare's kumiss was not liked by the panelists and MCMK was the most liked (Figure 7c). Küçükçetin (2003) made his inoculant at a different way from us. Inoculant production medium and the kumiss milk were incubated at 22 °C with shaking. We did it statically at 28 °C. Differences in alcohol levels may be due to different applications. It may not be accurate to make a one-to-one comparison with Küçükçetin's and our results.

Since different materials and methods were used in the researches, it is difficult to compare the results. Although the starter cultures of kumiss are traded, standard strains have not yet been found. In this study, mare's kumiss was used to develop inoculant and sequential MCMK were made for inoculant adaptation. We tried to select culture strains from MCMK dominant flora. At this stage, more research should be done to develop best starter culture

appropriate for material, method and cultural demands. Rakhmanova et al. (2021) selected a strain from mare's kumiss (colonies that grew by incubating the MRS agar plates used in strain selection at 37 °C and PDA agar plates at 28 °C) for cow's milk kumiss and fermented with a combination of the two strains. Researchers have suggested incubation at 36 °C for 16 hours by adding 4% of culture obtained by the combination of a bacterium and yeast to milk. The researchers have determined that yeasts were dominant in the mare's milk and bacteria in cow's milk. It has also been reported by the researchers that acidity and pH development are higher in mare's milk kumiss. Although the study has been designed differently from our study, the aims are similar.

Conclusion

The use of 5% freshly prepared kumiss or a consortium of bacteria and yeasts selected from kumiss appeared to be recommendable as inoculant. Modification of cow's milk by addition of 50% (v/v) water, 3.8% (w/v) lactose and 0.9% whey proteins in it can be suitable for making kumiss like fermented dairy drink. Static incubation of milk at 28 °C for 24 h, and 4.4 pH and 0.7% lactic acid levels in kumiss appeared to be appropriate for making such a drink. A pH of 3.5 to 4, a maximum of 1.5% lactic acid level in the drink appeared to be good values for such a drink at the 14th d of cold storage. It is concluded in this study that more detailed studies on the subject are needed to develop cow's milk kumiss or kumiss-like drinks.

Financial Support

This research received grant from Siirt University Scientific Research Projects Coordination Office.

Ethical Statement

This study does not present any ethical concerns.

Conflict of Interest

The authors declared that there is no conflict of interest.

References

- Afzaal, M., Saeed F., Anjum, F., Waris, N., Husaain, M., Ikram, A., Ateeq, H., Muhammad Anjum, F., & Suleria, H. (2021). Nutritional and ethnomedicinal scenario of koumiss: A concurrent review. *Food Science and Nutrition*, 9(11), 6421-6428. <https://doi.org/10.1002/fsn3.2595>

- Bansal, S., Singh, A., Mangal, M., & Sharma, S.K. (2013). Isolation and characterization of lactic acid bacteria from fermented foods. *International Journal of Plant Research*, 26(2), 32530. <https://doi.org/10.5958/j.2229-4473.26.2.092>
- Behera, S.K, Panda, K.S., Kayitesi, E., & Mulaba-Bafubandi, A.F. (2017). Kefir and Koumiss Origin, Health Benefits and Current Status of Knowledge. In: C. Ray and Didier Montet (Ed.), *Fermented Food* (1st ed., pp.400-417). CRC Press.
- Berlin, P.J. (1962). *Kumiss*. In Bulletin 4, International Dairy Federation, Brussels, Belgium: 4-16.
- Dankow, R., Wojtowski, J., Pikul, J., Niznikowski, R., & Cais-Sokolinski, D. (2006). Effect of lactation on the hygiene quality and some milk physicochemical traits of the Wielkopolska mares. *Archiv fur Tierzucht*, 49, 201-206.
- de Melo Pereira, G.V., de Carvalho Neto, D.P., Maske, B.L., De Dea Lindner, J., & Vale, A.S. (2022). An updated review on bacterial community composition of traditional fermented milk products: what next-generation sequencing has revealed so far? *Critical Reviews in Food Science and Nutrition*, 62(7), 870-889. <https://doi.org/10.1080/10408398.2020.1848787>
- Dhewa, T., Mishra, V., Kumar, N., & Sangu, K. (2015). Koumiss: The nutritional and therapeutic values. pp. 483-494 in *Fermented Milk and Dairy Products*. CRC Press, Boca Raton, FL.
- Dönmez, N., Kısadere, İ., Balaban, C., & Kadiralieva, N. (2014). Effects of traditional homemade koumiss on some hematological and biochemical characteristics in sedentary men exposed to exercise. *Biotechnic and Histochemistry*, 89, 558-563.
- Dugan, F.M. (2009). Fermentative microorganisms in the prehistory of Europe, the Steppes, and Indo-Iranian Asia and their contemporary use in traditional and probiotic beverages. *Fungi*, 2, 4.
- Eliş Yildiz, S., Yiğit, A., Duman Aydin, B., Karadağ Sari, E., Deprem, T., & Taşçı Koral, S. (2015). Effects of kefir, koumiss, milk and yoghurt administration on distribution of plasma cells and mast cells in mice spleen. *Kafkas Üniversitesi Veteriner Fakültesi Dergisi*, 21(2), 195-201. <https://doi.org/10.9775/kvfd.2014.12015>
- Ender, G., Karagözlü, C., Yerlikaya, O., & Akbulut, N. (2006): *Dünya’da ve Türkiye’de tüketimi artan fermente süt içecekleri*. 149-152. 9. Gıda Kongresi. 24 May - 26 May 2006, Bolu, Türkiye.
- Erdem, B., & Gundogdu, I. (2018a). An investigation on koumiss treatment in the context of health tourism: a literature review. *TURIZAM*, 22(3), 107-120.
- Erdem, B., & Gundogdu, I. (2018b). Koumiss treatment in the context of health tourism: A research in Kyrgyzstan. *International Journal of Medical Science and Health Research*, 7(11), 135-155.
- George, J.T. (1872). Koumiss, Blanda, Syre, Sigre, or Airen. *British Medical Journal*, 2(612), 325. <https://doi.org/10.1136/bmj.2.612.325>
- Gülmez, C., & Atakişi, O. (2020). The effects of koumiss supplementation on body weight, food intake, nesfatin-1 and irisin levels in BALB/C mice. *Veterinary Archives*, 90(6), 627-636.
- Hinz, K., O'Connor, P.M., Huppertz, T., Ross, R.P., & Kelly, A.L.J. (2012). Comparison of the principal proteins in bovine, caprine, buffalo, equine and camel milk. *Dairy Researches*, 79(2), 185-191. <https://doi.org/10.1017/S0022029912000015>
- Ishii, S., Hosino, B., Komiyama, H., Uehara, A., & Nurtazin, S. (2014). Study on production and properties of koumiss of herders in Mongolian dry steppe. *Journal of Arid Land Studies*. 24(1), 195-197.
- Kınık, Ö., Akalın, S. & Gönç, S. (2000). Kıymız üretimi ve özellikleri üzerinde bir araştırma. *Gıda*, 25(5), 379-384.
- Kırdar, S.S., & Tegin., R.A.A. (2022). Koumiss: a review of history, processing condition, functional properties and industrial application. In: Akbarishahabi, L. (Ed.), *Contemporary Multidisciplinary Technical Research* (1st ed., pp. 145-168. SRA Academic Publishing.
- Koroleva, N.S. (1988). Technology of kefir and kumys. *Bulletin of IDF*. 227, 96-100.
- Kozhahmetova, Z., & Kasenova, G. (2013). Selection of lactic acid bacteria and yeast for koumiss starter and its impact on quality of koumiss. *Applied Technologies & Innovations*, 9(4), 113-117.
- Küçükçetin, A., Yaygın, H., Hinrichs, J., & Kulozik, U. (2003). Adaptation of bovine milk towards mares' milk composition by means of membrane technology for koumiss manufacture. *International Dairy Journal*, 13, 945-951.
- Legielski, V.A. (1874). On the various preparations of koumiss and their use in medicine. *British Medical Journal*, 1(688), 229-231.
- Li, H, Wang, Y., Zhang, T., Li, J., Zhou Y., Li, H., & Yu, J. (2020). Comparison of backslopping and two-stage fermentation methods for koumiss powder production based on chemical composition and nutritional properties. *Journal of the Science of Food and Agriculture*, 100(4), 1822-1826. <https://doi.org/10.1002/jsfa.10220>
- Liu, W., Wang, J., Zhang, J., Mi, Z., Gesudu, Q., & Sun, T. (2019). Dynamic evaluation of the nutritional composition of homemade koumiss from Inner Mongolia during the fermentation process. *Journal of Food Processing and Preservation*, 43(8), 1-7. <https://doi.org/10.1111/jfpp.14022>

- Maksyutov, R., Solovieva, E., Mamtsev, A., & Kozlov, V. (2013). Technology development of kumis functional drink. *Ukrainian Journal of Food Science*, 1(2), 175-180.
- Malacarne, M., Martuzzi, F., Summer, A., & Mariani, P. (2002). Protein and fat composition of mare's milk: Some nutritional remarks with reference to human and cow's milk. *International Dairy Journal*, 12(11): 869-877.
- Marsh, A.J., Colin, H., Ross, H.R., & Cotter, P.D. (2014). Fermented beverages with health-promoting potential: Past and future perspectives. *Trends in Food Science & Technology*, 38, 113-124. <https://doi.org/10.1016/j.tifs.2014.05.002>.
- McGuire, G. (2017). Cultural histories of kumiss: tuberculosis, heritage and national health in post-Soviet Kazakhstan. *Central Asian Survey*, 36(4), 493-510. <https://doi.org/10.1080/02634937.2017.1327420>
- Musaev, A., Sadykova, S., Anambayeva, A., Saizhanova, M., Balkanay, G., & Kolbaev, M. (2021). Mare's milk: Composition, properties, and application in medicine. *Archives of Razi Institute*, 76(4), 1125-1135. <https://doi.org/10.22092/ari.2021.355834>
- Nurtazin, S., Ishii, S., & Hoshin, B. (2015). Mare's milk and kumys. *KAZNU Bulletin Ecology Series*, 1(1), 43.
- Özer M (1997): *Farklı yöntemlerle inek sütünden kıymız üretimi üzerinde bir araştırma*. Yüksek Lisans Tezi. Ankara Üniversitesi Fen Bilimleri Enstitüsü, Ankara.
- Pastukhova, Z.M., & Gerbeda, V.V. (1982). Comparative lipid composition of mare's milk and a koumiss mixture prepared with cow's milk. *Vopr Pitan*, 1, 34-36.
- Pouch, D.F., & Ito, K. (2001). *Compendium of methods for the microbiological examination of foods*. American Health Association Washington DC.
- Rakhmanova, A., Wang, T., Xing, G., Ma, L. Hong, Y., Lu, Y., Xin, L., Xin, W., Zhu, Q., & Lü, X. (2021). Isolation and identification of microorganisms in Kazakhstan koumiss and their application in preparing cow-milk koumiss. *Journal of Dairy Science*, 104(1), 151-166. <https://doi.org/10.3168/jds.2020-18527>
- Reiner, K. (2012). Carbohydrate fermentation protocol. *Energy*, 11, 12.
- Sadler, G.D., & Murphy, P.A. (1984). pH and titratable acidity. In: S.S. Nielsen (Ed.), *Food analysis* (3th ed., pp.207-225). Springer, New York.
- Sevilmiş, G. (2016). Gıda güvenliğinde neredeyiz? Mevcut durum-öneriler. *İstanbul Ticaret Odası Ar-Ge Bülteni*, 28-33.
- Shaimardanova, Z.D. (2012). Koumiss and its medical quality (Based on foreign sources XIX-early XX centuries). *International Journal of Experimental Education*, 12, 53-54.
- Sun, Z., Liu, W., Zhang, J., Yu, J. Zhang, W., Cai, C., Menghe, B., Sun, T., & Zhang., H. (2010). Identification and characterization of the dominant lactobacilli isolated from koumiss in China. *The Journal of General and Applied Microbiology*, 56(3), 257-265. <https://doi.org/10.2323/jgam.56.257>
- Tang, H., Ma, H., Hou, Q., Li, W., Xu, H., Liu, W., Sun, Z., Haobisi, H., & Menghe, B. (2020). Profiling of koumiss microbiota and organic acids and their effects on koumiss taste. *BMC Microbiology*, 20(85), 1-11. <https://doi.org/10.1186/s12866-020-01773-z>
- Tegin, R.A.A. & Gönülalan, Z. (2014a). Kıymızların bazı mikrobiyolojik özelliklerinin araştırılması: Kırgızistan, Narın Bölgesi. *MANAS Journal of Engineering*, 2(2), 1-8.
- Tegin, R.A.A. & Gönülalan Z. (2014b). Bütün yönleriyle doğal fermente ürün, kıymız. *MANAS Journal of Engineering*, 2(1), 23-34.
- Teichert, J., Cais-Sokolińska, D., Danków, R., Pikul, J., Chudy, S., Bierzuńska, P., Bierzuńska, P., & Kaczyński ŁK. (2020). Color stability of fermented mare's milk and a fermented beverage from cow's milk adapted to mare's milk composition. *Foods*, 19; 9(2), 1-11. <https://doi.org/10.3390/foods9020217>
- Uçar, A., Yılmaz, M.V., & Çakıroğlu, F.P. (2016). Food Safety – Problems and Solutions. In book: Significance, Prevention and Control of Food Related Diseases. Chapter 1. <http://dx.doi.org/10.5772/63176>
- Wang, J., Chen, X., Liu, W., Yang, M., Airidengcaicike, & Zhang, H (2008). Identification of *Lactobacillus* from koumiss by conventional and molecular methods. *European Food Research and Technology*, 227(5), 555-561. <https://doi.org/10.1007/s00217-008-0880-4>
- Wu, Y., Li, Y., Gesudu, Q., Zhang, J., Sun, Z., Halatu, H., Menghe, B., & Liu, W. (2021). Bacterial composition and function during fermentation of Mongolia koumiss. *Food Science and Nutrition*, 9(8), 4146-4155. <https://doi.org/10.1002/fsn3.2377>
- Xia, Y., Yu, J., Liu, H., Feng, C., & Shuang, Q. (2021). Novel insight into physicochemical and flavor formation in koumiss based on microbial metabolic network. *Food Research International*, 149, 1-11. <https://doi.org/10.1016/j.foodres.2021.110659>
- Yangılar, F., Oğuzhan, P., & Çelik, P. (2016). Eşsiz bir içeceğimiz: Kıymız. *Ege Üniversitesi Fen Bilimleri Enstitüsü Dergisi*, 6(1), 123-133.
- Yao, G., Yu, J., Hou, Q., Hui, W., Liu, W., Kwok, L.Y., Menghe, B., Sun, T., Zhang, H., & Zhang, W. A. (2017). A perspective study of koumiss microbiome by metagenomics analysis based on single-cell

- amplification technique. *Frontiers in Microbiology*, 8(165), 1-11.
<https://doi.org/10.3389/fmicb.2017.00165>
- Yaygın, H. (1994). Kımız ve özellikleri. Milli Süt ve Süt Ürünleri Sempozyumu, 2-3 Haziran 1994, İstanbul.
- Ying, A., Adachi, Y., & Ogawa, Y. (2004). Classification of lactic acid bacteria isolated from chigoe and mare milk collected in Inner Mongolia. *Nihon Chikusan Gakkaiho*, 75(3), 245-252.
<https://doi.org/10.1111/j.1740-0929.2004.00183.x>
- Zhang, M., Dang, N., Ren, D., Zhao, F., Lv, R. Ma, T., Bao, Q., Menghe, B., & Liu, W. (2020). Comparison of bacterial microbiota in raw mare's milk and koumiss using pacbio single molecule real-time sequencing technology. *Frontiers in Microbiology*, 27(11), 1-13. <https://doi.org/10.3389/fmicb.2020.581610>

Can thermal imaging technique be an effective method to assess pulp health in dogs?: a pilot study

Candemir ÖZCAN^{1,a,*}, Kürşad YİĞİTARSLAN^{2,b}

¹Kastamonu University, Faculty of Veterinary Medicine, Department of Surgery, Kastamonu, Türkiye; ²Burdur Mehmet Akif Ersoy University, Faculty of Veterinary Medicine, Department of Surgery, Burdur, Türkiye.

^aORCID: <http://orcid.org/0000-0003-2186-5305>; ^bORCID: <http://orcid.org/0000-0003-4416-1597>

*Corresponding author: cozcan@kastamonu.edu.tr

Received 05.05.2023 - Accepted 16.06.2023 - Published 30.06.2023

Abstarct: This study aimed to determine the effectiveness of thermograms obtained from canine teeth of dogs with healthy gingiva and no tooth discoloration in assessing pulp vitality and quickly determining tooth vitality. The study included 64 canine teeth of 16 non-brachiocephalic, crossbred, male dogs with healthy periodontal tissue and no radiolucent areas in the periapical region. Thermograms of the canine teeth were taken and it was evaluated whether the coronal pulp tissue caused a temperature difference on the tooth surface. In the statistical analysis, it was determined that the coronal pulp caused a temperature increase of 0.34°C on the tooth surface ($P > 0.05$). As a result, it was concluded that the thermal camera can give an idea to the physician in the evaluation of blood flow in the pulp and help in deciding tooth vitality.

Keywords: Dog, pulp vitality, thermography.

Termal görüntüleme tekniği köpeklerde pulpa sağlığını değerlendirmede etkili bir yöntem olabilir mi?: ön çalışma

Özet: Bu çalışma, sağlıklı diş etlerine sahip ve dişinde herhangi bir renk değişikliği gözlenmeyen köpeklerin kanin dişlerinden alınan termogramların pulpa canlılığını değerlendirmedeki etkinliğini belirleyebilmek ve diş canlılığına hızlı bir şekilde karar verebilmek amacıyla yapıldı. Çalışmada sağlıklı periodontal dokuya sahip ve radyografide periapikal bölgede radyolusent alanlara rastlanmayan 16 adet non-brakiosefalik, melez, erkek köpeğe ait 64 adet kanin diş dahil edildi. Kanin dişlere ait termogramlar alınarak koronal pulpa dokusunun diş yüzeyinde bir sıcaklık farkı oluşturup oluşturmadığı değerlendirildi. Yapılan istatistik analizde koronal pulpanın diş yüzeyinde 0,34°C bir sıcaklık artışına sebep olduğu tespit edildi ($P > 0,05$). Sonuç olarak termal kameranın pulpada kan akımının değerlendirilmesinde hekime bir fikir verebileceği ve diş canlılığına karar vermede yardımcı olabileceği kanısına varıldı.

Anahtar kelimeler: Köpek, pulpa canlılığı, termografi.

Introduction

The dental pulp is a vital tissue inside the tooth. The dental pulp consists of blood vessels, nerves, connective tissue, and specialized cells. It serves several functions, including providing nourishment to the tooth, conveying sensory information, and participating in the formation of dentin. The dental pulp is protected by the hard tissues of the tooth, enamel, and dentin (Kazmi et al., 2022). The volume of the pulp cavity decreases with age, but various

factors can influence its size. These factors encompass tooth type, tooth position, gender, breed, nutritional status, and environmental factors (Maeda, 2020). Dental pulp has three parts: coronal pulp, radicular pulp, and apical foramen. Coronal pulp fills the pulp cavity in the crown part of the tooth (Kazmi et al., 2022).

In veterinary dentistry, determining the state of pulpal health is crucial for identifying and treating a range of dental pathologies. However, accurately assessing the condition of the pulp can be challenging due to the protective layer of enamel and dentin that surrounds it, and the fact that animals cannot communicate their pain to their caregivers (Proulx et al., 2022). Given the difficulty in accurately assessing pulpal health in veterinary dentistry, it is crucial to exercise caution when interpreting the results of pulp tests to avoid misdiagnosis and inappropriate treatment. Therefore, the results of such tests must be scrutinized closely and evaluated with care (Chen & Abbott, 2009).

Various methods are used by veterinarians to evaluate dental vitality in dogs, and some of the most used methods include:

Visual Inspection of the Crown of the Tooth: The visible part of a tooth, known as the crown, is made up of three main components: enamel, dentin, and pulp. Any modifications to these structures can result in changes to the tooth's appearance due to the way it transmits and reflects light. Discoloration of teeth can be categorized based on where the staining occurs, either on the outer surface (extrinsic) or within the tooth itself (intrinsic) (Feigin et al., 2022).

Veterinary professionals recognize the importance of tooth discoloration as a potential indicator of tooth nonvitality and can diagnose and recommend appropriate treatment options with a high degree of accuracy (Hale, 2001).

Discoloration of teeth can appear in a range of shades from yellow to dark brown, as well as pink and purple. Among these colors, pink, yellow, and gray are the most observed, and they can be indicative of changes in the pulp of traumatized teeth. Pink discoloration, for instance, may occur due to factors such as intrapulpal hemorrhage or internal resorption (Feigin et al., 2022). Pulpal ischemia and pulpal death without bacterial contamination may produce subtle tooth discoloration (Holan & Fuks, 1996)

The issue of tooth discoloration poses two significant obstacles for dentists. Firstly, it requires an understanding of the underlying causes and their impact on the overall health of the affected teeth (Hattab et al., 1999). Secondly, determining the most suitable treatment plan can be a challenge (Feigin et al., 2022).

Electric Pulp Test (EPT): This method is used to determine the vitality of a tooth pulp by applying an electric current to the tooth and measuring the response of the pulp. During this

test, an electric signal is applied to a tooth and a live pulp typically responds with a sensation such as pain. The device used during the test controls the strength and duration of the electric signals applied to the tooth, indicating the status of the tooth pulp (Chen & Abbott, 2009). The ionic flow of dentinal fluid within the dentinal tubules leads to the generation of action potentials from intact A delta fibers, resulting in a positive outcome (Narhi et al., 1979).

The electric pulp test provides information about nerve conduction and the presence of nerve fibers, but it cannot determine the integrity and health status of the pulp. It has been reported that there is no relationship between the positive response obtained from the electric pulp test and the histological condition of the pulp (Mumford, 1967).

Teeth that have suffered trauma, although alive, temporarily lose their sensory functions and do not respond to electric pulp testing, while teeth with partial necrosis, despite the absence of blood flow in the pulp, give a positive response (Peterson et al., 1999).

Cold Test: The cold test is the most used pulp sensitivity test. Its application causes the dentinal fluid within the dentinal tubules to contract and move outward (Brännström, 1963; Brännström, 1986). This sudden movement of dentinal fluid exerts hydrodynamic forces on the A-delta nerve fibers within the pulp-dentin complex, resulting in sharp localized pain (Proulx et al., 2022). The cold test is performed using ice sticks (0°C), solid carbon dioxide gas (CO₂) sticks (-78°C), ethyl chloride (-5°C), and dichlorodifluoromethane (DDM) (-50°C). The main difference between the tests is the temperature differential applied (Fleury & Regan, 2006). The cold test can be used to differentiate between reversible and irreversible reasons. After the stimulus is removed, it should be assessed whether the pain continues or disappears immediately. If there is pain that persists even after the stimulus has been removed, it may indicate irreversible pulpitis (Gopikrishna et al., 2009).

Laser Doppler Flowmetry (LDF): LDF is a method that allows direct measurement of blood flow in small blood vessels of the microvascular system. It was first used by Gazelius et al. (1986) in dentistry. LDF is used to measure blood flow in the pulp for vitality assessment of traumatized teeth. In periodontics, it is used to measure gingival blood flow after crest augmentation, and in reason, it is used to measure gingival blood flow in flaps after Le Fort I osteotomy (Dodson et al., 1994; Zanetta-Barbosa et al., 1993). In this technique, the laser beam is directed onto the tissue where blood flow is to be measured. When the beam enters the tissue, it is scattered and absorbed by moving red blood cells and stationary tissue elements. According to the Doppler principle, photons scatter and change their frequency when they encounter moving red blood cells. Photons encountering stationary elements are scattered but do not change their position in Doppler. Part of the beam is reflected to the photon detector, creating

a signal. Red blood cells constitute the most moving objects in the dental pulp. Therefore, the reflected and collected photons provide a measure of blood flow in the pulp (Gazelius et al., 1986; Wilder-Smith, 1988).

Pulse Oximeter: Pulse oximeter, is a SaO₂ imaging device commonly used in medicine to reason oxygen saturation levels in the blood of patients undergoing intravenous anesthesia. It is a completely objective test that does not rely on subjective reactions from the patient. The pulse oximeter sensor has two light-emitting ends: one that emits red light (640 nm) and the other that emits infrared (940 nm) light. On the other side of the tissue where the ends are applied is a photodetector. Oxygenated hemoglobin and non-oxygenated hemoglobin absorb red and infrared light in different amounts, which is detected by the photodetector. The relationship between the pulsatile changes in red light absorption and those in infrared light absorption is evaluated by the pulse oximeter, and arterial blood saturation is determined (Gopikrishna et al., 2009).

Dental Transillumination: This method involves applying a light source from the back of the tooth and observing the tooth's interior for any cavities or fractures. It is a useful test for identifying any issues within the tooth. It has many applications in restorative dentistry. One of them is using near-infrared light transillumination (NILT) for early detection and minimally invasive treatment of carious lesions (Vinothkumar, 2021). The principle of this method is to light on the teeth and see the carious areas as darker than the healthy ones (Marouane & Chtioui, 2020). This method can be an alternative or a supplement to radiography. It has been shown to be reliable, repeatable, and effective (Lara-Capi et al., 2017; Marouane & Chtioui, 2020).

Dental transillumination also uses light to illuminate the tooth and measure the blood flow in the pulp chamber. This method uses laser speckle imaging (LSI) technology to provide light from the back of the tooth and capture images from the front of the tooth. Near-infrared light (NILT) can be used as a light source (Stoianovici et al., 2011). This method can help to assess dental vitality without radiation exposure and with minimal invasiveness (Stoianovici et al., 2011; Zhang & Yelick, 2010). However, it is stated that the electric pulp testing method is less reliable than the cold test in detecting non-vital teeth (Proulx et al., 2022).

Radiography: X-ray imaging is used to visualize the structures inside the canine tooth. This method is very useful for detecting problems in the roots of the tooth. Dental radiographs provide essential information for the diagnosis of endodontic disease. Radiographs do not provide direct information on pulpal health, but many of the effects of pulpal pathology are radiographically visible (Dupont & DeBowes, 2009). The points to pay attention to in radiographs are the width and number of pulp horns, the width and shape of the pulp chamber,

the width and shape of the pulp canal, the thickness and density of dentin, the width and position of the apical foramen, the presence and size of periradicular lesions (Edwards et al., 2021; Rowe & Ford, 1990).

There are objective methods that measure dental vitality directly or determine the blood flow or oxygen saturation of the pulp. These include laser Doppler flowmetry, spectrophotometry, pulse oximetry, thermography, and optical coherence tomography (Gopikrishna et al., 2009; Aubeux et al., 2021; Grabliauskienė et al., 2021). The advantages of these methods are that they can evaluate dental vitality without radiation exposure, painlessly and non-invasively. The disadvantages are that they are expensive, lack standardized protocols, and can be affected by various factors (Gopikrishna et al., 2009; Aubeux et al., 2021).

There are also subjective methods that indirectly measure dental vitality or determine the pulp's sensitivity status. These include thermal tests, electrical tests, test cavities, and anesthesia use. The advantages of these methods are that they are easy to apply and low-cost. The disadvantages are that they expose to radiation, cause pain and invasiveness, and give subjective results. One of the reasons for preferring objective methods in animals is that they do not give subjective results and do not require cooperation with the patient for the responses to be obtained (Gopikrishna et al., 2009; Aubeux et al., 2021).

A thermal camera is used to determine the health status of the gums in dogs (Yiğitarıslan et al., 2023). It is also stated that a thermal camera can be an effective method in distinguishing different clinical findings in the gums of dogs (Yiğitarıslan & Özcan, 2023). It is emphasized that the temperatures in the examined regions should be correlated with the temperature in different regions of the body and that the degree of acceptability of these temperature changes should be determined (Kaya et al., 2023).

Different methods have been reported in the literature to evaluate pulp vitality. Sensory analyses performed to evaluate pulp vitality in dogs may result in false negative or false positive outcomes. We think that thermal imaging may be an effective method for an objective evaluation of pulp vitality. This study was conducted to demonstrate that the coronal pulp in dogs with healthy teeth causes a temperature increase on the tooth surface and to report that this temperature increase may be used as an auxiliary diagnostic method for objectively evaluating pulp vitality.

Materials and Methods

Animals: In this study, 16 non-brachycephalic male dogs with healthy gums, which were brought to the Surgery Clinic of Burdur Mehmet Akif Ersoy University Faculty of

Veterinary Medicine for castration, were used as animal subjects. The examination was performed on canine teeth with numbers 104 (Canine₁₀₄), 204 (Canine₂₀₄), 304 (Canine₃₀₄), and 404 (Canine₄₀₄) according to the Triadan numbering system.

Inclusion criteria: A periodontal probe was used to determine the periodontal health of the dogs. X-ray was taken in an oblique position for examination of the periapical region. Dogs with no clinical bleeding in the gums and no radiolucent areas in the periapical region on radiograph were included in the study.

Anesthesia: An anesthesia device (Draeger, Primus[®], Germany) that had two vaporizers and an automatic ventilator was used to perform general anesthesia on dogs. A preanesthetic dose of 0.1 mg/ kg of diazepam (Diazem amp[®] IM/IV, 10 mg/2 ml, Deva, Istanbul) was given intravenously and anesthesia was induced with 3 mg/kg of propofol (Propofol[®] 1% Fresenius, Germany). A disposable endotracheal tube (Rüsch, Willy-Rüsch Ltd., Germany) with a suitable size was inserted to keep the airway open. Sevoflurane (Sevoflurane, USP[®], United States), a volatile anesthetic, was used to maintain anesthesia.

Examination and taking thermograms: The dogs were placed in a lateral position on the examination table while they were under anesthesia. Thermograms of canine teeth from both sides of the upper and lower jaws were taken from 20 cm away with a thermal camera (Trotec[®] EC060V, 160x120 pixels, France) (Figure 1).

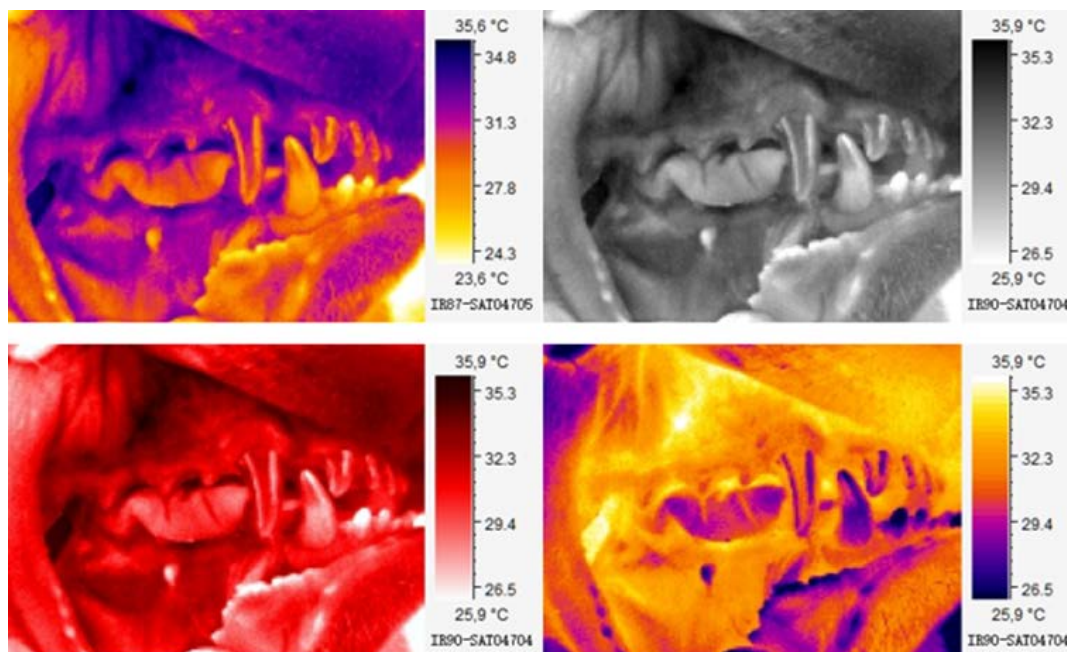


Figure 1. The appearance of the thermal image of the pulp tissue on the tooth surface of a dog with a vital tooth in different color palettes.

Evaluation of thermograms: IC IR Report Software® program was used to analyze thermograms and the temperature difference between the pulp tissue projection on the tooth surface and the rest of the tooth area was recorded (Figure 2). The region of interest (ROI) was determined based on the average temperature of the area. The temperature difference between the areas was calculated.

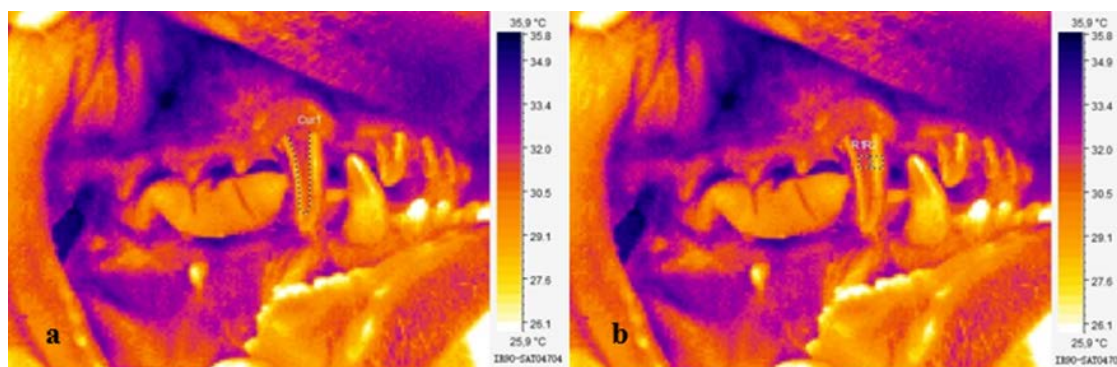


Figure 2. a: Thermal image of the pulp tissue on the tooth surface. b: Obtaining temperature data from R1 (pulp temperature on the tooth surface) and R2 regions.

Statistical analysis: PASW Statistics 18 software was used for data analysis. Independent Samples T Test analysis was performed to determine the statistical significance level between the R1 and R2 area temperatures of the teeth numbered according to the triadan numbering system. Mann Whitney U analysis method was used to determine the statistical significance level of the temperature difference ($\Delta T^{\circ}\text{C}$) between maxillary (104 and 204 number) and mandibular (304 and 404 number) canine teeth. $P < 0.05$ was considered statistically significant. The values in the article are given as mean \pm standard error.

Results

Dental and gingival examinations of 16 male dogs aged 2-5 years, brought to the Surgery Clinic of Burdur Mehmet Akif Ersoy University, Faculty of Veterinary Medicine, Animal Hospital with castration request, were performed. Clinical and thermographic examination of 64 canine teeth was performed. The temperatures measured in the ROI area are shown in Table 1.

The average R1 area temperature of canine teeth numbered 104 was measured as $32.71 \pm 0.33^{\circ}\text{C}$ and R2 area temperature as $32.28 \pm 0.31^{\circ}\text{C}$. The R1 area temperature representing the temperature caused by the pulp on the enamel surface of all teeth was higher than the R2 area temperature. The temperature difference between the areas was measured as 0.43°C . However, this temperature difference was not statistically significant ($P > 0.05$).

Table 1. The temperature of the coronal pulp on the tooth surface (R1) and the enamel temperature (R2) in canine teeth.

Case No	Canine ₁₀₄		Canine ₂₀₄		Canine ₃₀₄		Canine ₄₀₄	
	R1	R2	R1	R2	R1	R2	R1	R2
1	33.8	32.7	36.2	35.8	34.7	34.4	33.5	33.0
2	31.5	31.1	31.7	31.4	31.5	31.4	32.2	31.9
3	31.6	31.3	31.5	31.1	31.5	31.4	32.5	32.4
4	31.9	31.5	31.9	31.5	32.0	31.8	31.4	31.3
5	32.3	32.0	33.0	32.3	32.5	31.8	31.9	31.7
6	34.3	33.8	32.9	32.8	31.8	31.6	31.3	30.4
7	33.3	32.8	31.5	31.3	30.2	30.0	31.8	31.6
8	31.8	31.6	30.6	30.2	30.7	30.6	30.2	30.1
9	30.6	30.3	31.3	31.0	31.6	31.2	30.7	30.3
10	33.3	32.8	33.1	32.8	32.9	32.6	33.0	32.8
11	34.7	34.1	33.7	33.3	34.1	33.8	33.2	33.0
12	33.2	32.5	34.0	33.6	30.9	30.6	31.5	31.2
13	30.4	30.2	33.7	33.2	33.3	33.1	33.1	32.7
14	34.1	33.7	34.6	34.3	32.4	32.1	33.9	33.4
15	34.4	34.1	33.6	33.1	32.7	32.5	32.2	32.0
16	32.3	32.1	33.7	33.4	33.6	33.3	32.8	32.5

The average R1 area temperature of canine teeth numbered 204 was measured as $32.93\pm 0.36^{\circ}\text{C}$ and R2 area temperature as $32.56\pm 0.35^{\circ}\text{C}$. The R1 area temperature of all teeth was higher than the R2 area temperature. The temperature difference between the areas was measured as 0.36°C . The temperature difference was not statistically significant ($P > 0.05$).

The average R1 area temperature of canine teeth numbered 304 was measured as $32.27\pm 0.31^{\circ}\text{C}$ and R2 area temperature as $32.01\pm 0.30^{\circ}\text{C}$. The R1 area temperature of all teeth was higher than the R2 area temperature. The temperature difference between the areas was measured as 0.26°C . The temperature difference was not statistically significant ($P > 0.05$).

The average R1 area temperature of canine teeth numbered 404 was measured as $32.20\pm 0.25^{\circ}\text{C}$ and R2 area temperature as $31.89\pm 0.25^{\circ}\text{C}$. The R1 area temperature of all teeth was higher than the R2 area temperature. The temperature difference between the areas was measured as 0.30°C . The temperature difference was not statistically significant ($P > 0.05$).

The average R1 area temperature of canine teeth numbered 404 was measured as $32.20\pm 0.25^{\circ}\text{C}$ and R2 area temperature as $31.89\pm 0.25^{\circ}\text{C}$. The R1 area temperature of all teeth was higher than the R2 area temperature. The temperature difference between the areas was measured as 0.30°C . The temperature difference was not statistically significant ($P = 0.66$).

A temperature difference of 0.34°C was detected between the coronal pulp temperature and enamel surface temperature values of 64 canine teeth. However, this temperature difference was not statistically significant ($P > 0.05$).

The ΔT value of maxillary and mandibular canine teeth (numbered 104 and 204) was 0.59°C higher than the ΔT value of mandibular canine teeth (numbered 304 and 404). However, this difference was not statistically significant ($P < 0.05$). The ΔT values are shown in Table 2.

Table 2. The temperature difference ($\Delta T^{\circ}\text{C}$) between the R1 and R2 areas in canine teeth.

Case No	Canine ₁₀₄ $\Delta T^{\circ}\text{C}$ (R1-R2)	Canine ₂₀₄ $\Delta T^{\circ}\text{C}$ (R1-R2)	Canine ₃₀₄ $\Delta T^{\circ}\text{C}$ (R1-R2)	Canine ₄₀₄ $\Delta T^{\circ}\text{C}$ (R1-R2)
1	1.1	0.4	0.3	0.5
2	0.4	0.3	0.1	0.3
3	0.3	0.4	0.1	0.1
4	0.4	0.4	0.2	0.1
5	0.3	0.7	0.7	0.2
6	0.5	0.1	0.2	0.9
7	0.5	0.2	0.2	0.2
8	0.2	0.4	0.1	0.1
9	0.3	0.3	0.4	0.4
10	0.5	0.3	0.3	0.2
11	0.6	0.4	0.3	0.2
12	0.7	0.4	0.3	0.3
13	0.2	0.5	0.2	0.4
14	0.4	0.3	0.3	0.5
15	0.3	0.5	0.2	0.2
16	0.2	0.3	0.3	0.3

Discussion

The dental pulp is a vital tissue inside the tooth. The dental pulp consists of blood vessels, nerves, connective tissue, and specialized cells. It serves several functions, including providing nourishment to the tooth, conveying sensory information, and participating in the formation of dentin. The dental pulp is protected by the hard tissues of the tooth, enamel, and dentin (Kazmi et al., 2022). Hence, it is necessary to test that the pulp is alive, and its vitality continues for the tooth to remain vital. Since the pulp is living tissue, a temperature change on the tooth surface would be caused by the blood flow here.

The volume of the pulp cavity decreases with age. Other factors affect pulp size. These include tooth type, tooth position, gender, race, nutritional status, and environmental factors (Maeda, 2020). However, the pulp does not always cause a temperature change on the tooth surface as seen in Figure 1. It was thought that this was due to the shrinkage of the pulp volume caused by age and other factors mentioned in the literature.

Dental pulp has three parts: coronal pulp, radicular pulp, and apical foramen. Coronal pulp fills the pulp cavity in the crown part of the tooth (Kazmi et al., 2022). In this study, only the coronal pulp temperature was evaluated. The coronal pulp provides a temperature increase in an area equal to its volume on the tooth surface. Although there is no statistically significant

temperature increase, the temperature increase on the tooth surface can be distinguished in different color palettes on thermograms (Figure 1).

In veterinary dentistry, determining the state of pulpal health is crucial for identifying and treating a range of dental pathologies. However, accurately assessing the condition of the pulp can be challenging due to the protective layer of enamel and dentin that surrounds it, and the fact that animals cannot communicate their pain to their caregivers (Proulx et al., 2022). In methods determined by the sensory response, situations may be evaluated as a false positive or false negative. The dog's failure to respond in situations where there is pain can cause erroneous evaluations. The method used in this study provides the possibility of objective evaluation based on temperature increase. The thermal camera's sensitive detectors detect even the smallest temperature changes. Thus, it was thought that the thermal camera could give an idea to the clinician about pulp health.

EPT is used to determine the vitality of a tooth pulp by applying an electric current to the tooth and measuring the response of the pulp. During this test, an electric signal is applied to a tooth and a live pulp typically responds with a sensation such as pain. The device used during the test controls the strength and duration of the electric signals applied to the tooth, indicating the status of the tooth pulp (Chen & Abbott, 2009). Evaluations made with a thermal camera do not require a sensory response. Therefore, a thermal camera provides an advantage to the clinician in evaluating pulp health status.

There are objective methods that measure dental vitality directly or determine the blood flow or oxygen saturation of the pulp. These include laser Doppler flowmetry, spectrophotometry, pulse oximetry, thermography, and optical coherence tomography (Aubeux et al., 2021; Gopikrishna et al., 2009; Grabliauskienė et al., 2021). The advantages of these methods are that they can evaluate dental vitality without radiation exposure, painlessly and non-invasively. The disadvantages are that they are expensive, lack standardized protocols, and can be affected by numerous factors (Aubeux et al., 2021; Gopikrishna et al., 2009). In this study, difficulties were encountered in standardizing the diagnostic protocol. There are not enough studies where pulp vitality is evaluated with the thermal camera.

Conclusion

This study is the first study that used thermographic methods to evaluate pulp health in dogs. It was observed that the pulp cavity in the healthy canine tooth caused a 0.34°C increase on the tooth surface in dogs. To see the adequacy of the thermal camera and the reliability of

the findings obtained in this regard, studies comparing different examination methods are needed.

Financial Support

This research received no grant from any funding agency/sector.

Ethical Statement

This research was carried out based on the permission of Burdur Mehmet Akif Ersoy University Local Animal Ethics Committee dated 13.03.2019 and numbered 504.

Conflict of Interest

The authors declared that there is no conflict of interest.

References

- Aubeux, D., Renard, E., Pérez, F., Tessier, S., Geoffroy, V., & Gaudin, A. (2021). Review of animal models to study pulp inflammation. *Frontiers in Dental Medicine*, 2, 673552. <https://doi.org/10.3389/fdmed.2021.673552>
- Brännström, M. (1963). A hydrodynamic mechanism in the transmission of pain-producing stimuli through the dentine. *Sensory Mechanisms in Dentine*, 73-79.
- Brännström, M. (1986). The hydrodynamic theory of dentinal pain: sensation in preparations, caries, and the dentinal crack syndrome. *Journal of Endodontics*, 12(10), 453-457. [https://doi.org/10.1016/S0099-2399\(86\)80198-4](https://doi.org/10.1016/S0099-2399(86)80198-4)
- Chen, E., & Abbott, P.V. (2009). Dental pulp testing: a review. *International Journal of Dentistry*, 2009. <https://doi.org/10.1155/2009/365785>
- Dodson, T.B., Neuenschwander, M.C., & Bays, R.A. (1994). Intraoperative assessment of maxillary perfusion during Le Fort I osteotomy. *Journal of Oral and Maxillofacial Surgery*, 52(8), 827-831. [https://doi.org/10.1016/0278-2391\(94\)90228-3](https://doi.org/10.1016/0278-2391(94)90228-3)
- Dupont, G., & DeBowes, L. (2009). Endodontic Disease. In: L. DeBowes (Ed.), *Atlas of Dental Radiography in Dogs and Cats* (1st ed., pp. 142-171). Elsevier-Saunders.
- Edwards, D., Stone, S., Bailey, O., & Tomson, P. (2021). Preserving pulp vitality: part one-strategies for managing deep caries in permanent teeth. *British Dental Journal*, 230(2), 77-82. <https://doi.org/10.1038/s41415-020-2590-7>
- Rowe, A.H.R., & Ford, T.P. (1990). The assessment of pulpal vitality. *International Endodontic Journal*, 23(2), 77-83. <https://doi.org/10.1111/j.1365-2591.1990.tb00843.x>
- Feigin, K., Bell, C., Shope, B., Henzel, S., & Snyder, C. (2022). Analysis and assessment of pulp vitality of 102 intrinsically stained teeth in dogs. *Journal of Veterinary Dentistry*, 39(1), 21-33. <https://doi.org/10.1177/08987564211060387>
- Fleury, A., & Regan, J.D. (2006). Endodontic diagnosis: clinical aspects. *Journal of the Irish Dental Association*, 52(1), 28-38.
- Gazelius, B., Olgart, L., Edwall, B., & Edwall, L. (1986). Non-invasive recording of blood flow in human dental pulp. *Dental Traumatology*, 2(5), 219-221. <https://doi.org/10.1111/j.1600-9657.1986.tb00148.x>
- Gopikrishna, V., Pradeep, G., & Venkateshababu, N. (2009). Assessment of pulp vitality: a review. *International Journal of Paediatric Dentistry*, 19(1), 3-15. <https://doi.org/10.1111/j.1365-263X.2008.00955.x>
- Grabliauskienė, Ž., Zamaliauskienė, R., & Lodienė, G. (2021). Pulp vitality testing with a developed universal pulse oximeter probe holder. *Medicina*, 57(2), 101. <https://doi.org/10.3390/medicina57020101>
- Hale, F. A. (2001). Localized intrinsic staining of teeth due to pulpitis and pulp necrosis in dogs. *Journal of Veterinary Dentistry*, 18(1), 14-20. <https://doi.org/10.1177/089875640101800102>
- Hattab, F.N., Qudeimat, M.A., & Al-Rimawi, H.S. (1999). Dental discoloration: an overview. *Journal of Esthetic and Restorative Dentistry*, 11(6), 291-310. <https://doi.org/10.1111/j.1708-8240.1999.tb00413.x>

- Holan, G., & Fuks, A.B. (1996). The diagnostic value of coronal dark-gray discoloration in primary teeth following traumatic injuries. *Pediatric Dentistry*, 18(3), 224-227.
- Kaya, F., Bozkurt, G., Ozcan, C., Cortu, A., & Yildiz, B.N.K. (2023). Could the different estrus periods significantly affect body temperature on clinical examination in bitches? *Journal of Thermal Biology*, 114, 103547. <https://doi.org/10.1016/j.jtherbio.2023.103547>
- Kazmi, S., Shepherd, S., Revie, G., Hector, M., & Mânica, S. (2022). Exploring the relationship between age and the pulp and tooth size in canines. A CBCT analysis. *Australian Journal of Forensic Sciences*, 54(6), 808-819. <https://doi.org/10.1080/00450618.2021.1882567>
- Lara-Capi, C., Cagetti, M.G., Lingström, P., Lai, G., Cocco, F., Simark-Mattsson, C., & Campus, G. (2017). Digital transillumination in caries detection versus radiographic and clinical methods: an in-vivo study. *Dentomaxillofacial Radiology*, 46(4), 20160417. <https://doi.org/10.1259/dmfr.20160417>
- Maeda, H. (2020). Aging and senescence of dental pulp and hard tissues of the tooth. *Frontiers in Cell and Developmental Biology*, 8, 605996. <https://doi.org/10.3389/fcell.2020.605996>
- Marouane, O., & Chtioui, F. (2020). Transillumination-aided infiltration: A diagnostic concept for treating enamel opacities. *Journal of Esthetic and Restorative Dentistry*, 32(5), 451-456. <https://doi.org/10.1111/jerd.12602>
- Mumford, J.M. (1967). Pain perception threshold on stimulating human teeth & the histological condition of the pulp. *British Dental Journal*, 123, 427-433.
- Narhi, M., Virtanen, A., Kuhta, J., & Huopaniemi, T. (1979). Electrical stimulation of teeth with a pulp tester in the cat. *European Journal of Oral Sciences*, 87(1), 32-38. <https://doi.org/10.1111/j.1600-0722.1979.tb01937.x>
- Peterson, K., Söderström, C., Kiani-Anaraki, M., & Levy, G. (1999). Evaluation of the ability of thermal and electrical tests to register pulp vitality. *Dental Traumatology*, 15(3), 127-131. <https://doi.org/10.1111/j.1600-9657.1999.tb00769.x>
- Proulx, C., Dumais, Y., Beauchamp, G., & Steagall, P. (2022). Reliability of electric pulp test, cold pulp test, or tooth transillumination to assess pulpal health in permanent dog teeth. *Journal of Veterinary Dentistry*, 39(2), 133-141. <https://doi.org/10.1177/089875642211076363>
- Stoianovici, C., Wilder-Smith, P., & Choi, B. (2011). Assessment of pulpal vitality using laser speckle imaging. *Lasers in Surgery and Medicine*, 43(8), 833-837. <https://doi.org/10.1002/lsm.21090>
- Vinothkumar, T.S. (2021). Application of near-infrared light transillumination in restorative dentistry: a review. *The Journal of Contemporary Dental Practice*, 22(11), 1355-1361. <https://doi.org/10.5005/jp-journals-10024-3204>
- Wilder-Smith, P.E. (1988). A new method for the non-invasive measurement of pulpal blood flow. *International Endodontic Journal*, 21(5), 307-312. <https://doi.org/10.1111/j.1365-2591.1988.tb01140.x>
- Yiğitarşlan, K., & Özcan, C. (2023). Determination of gingival temperatures of dogs with healthy gums by means of a thermal camera. *Veterinary Journal of Mehmet Akif Ersoy University*, 8(1), 19-25. <https://doi.org/10.24880/maeuofd.1193654>
- Yiğitarşlan, K., Özcan, C., & Cetintav, B. (2023). Thermographic Examination of the Gingiva of 16 Dogs. *Journal of Veterinary Dentistry*, 40(1), 38-46. <https://doi.org/10.1177/08987564221117738>
- Zanetta-Barbosa, D., Klinge, B., & Svensson, H. (1993). Laser Doppler flowmetry of blood perfusion in mucoperiosteal flaps covering membranes in bone augmentation and implant procedures. A pilot study in dogs. *Clinical Oral Implants Research*, 4(1), 35-38. <https://doi.org/10.1034/j.1600-0501.1993.040105.x>
- Zhang, W., & Yelick, P.C. (2010). Vital pulp therapy-current progress of dental pulp regeneration and revascularization. *International Journal of Dentistry*, 856087. <https://doi.org/10.1155/2010/856087>

Operative approach to a case of perineal laceration in an Arabian mare

Öznur YILMAZ^{1,a,*}, Tarık ŞAFAK^{2,b}, Mehmet Akif KILINÇ^{3,c}, Burak Fatih YÜKSEL^{4,d},
Kerem ERCAN^{5,e}, Ali RİŞVANLI^{4,6,f}

¹Siirt University, Faculty of Veterinary Medicine, Department of Obstetrics and Gynecology, Siirt, Türkiye;
²Kastamonu University, Faculty of Veterinary Medicine, Department of Obstetrics and Gynecology, Kastamonu, Türkiye;
³Bingöl University, Faculty of Veterinary Medicine, Department of Obstetrics and Gynecology, Bingöl, Türkiye;
⁴Fırat University, Faculty of Veterinary Medicine, Department of Obstetrics and Gynecology, Elazığ, Türkiye;
⁵Siirt University, Faculty of Veterinary Medicine, Department of Internal Medicine, Siirt, Türkiye;
⁶Kyrgyz-Turkish Manas University, Faculty of Veterinary Medicine, Department of Obstetrics and Gynecology, Bishkek, Kyrgyzstan.

^aORCID: <https://orcid.org/0000-0003-0424-9471>; ^bORCID: <https://orcid.org/0000-0002-6178-4641>; ^cORCID: <https://orcid.org/0000-0003-1577-1556>; ^dORCID: <https://orcid.org/0000-0002-7256-9189>; ^eORCID: <https://orcid.org/0000-0003-4914-8578>; ^fORCID: <https://orcid.org/0000-0001-5653-0025>

*Corresponding author: oznur.yilmaz@siirt.edu.tr

Received 21.09.2022 - Accepted 24.04.2023 - Published 30.06.2023

Abstract: In this report, a case of perineal laceration of a purebred Arabian breed of 5 years old brought to the Clinic of Obstetrics and Gynecology, Faculty of Veterinary Medicine, Fırat University was presented. As a result of the examination, it was determined that the lips of the vulva were intact, and the rupture was shaped in the perineal region above the rectum, anus, and vulva as distinct from the rectovaginal laceration after the parturition in mares. For the treatment of the animal, perineoplasty was performed on three different dates, but the targeted success could not be achieved because the rectovaginal fistula was formed.

Keywords: Mare, perineoplasty, rectovaginal laceration.

Arap ırk kısrakta perineal laserasyon olgusuna operatif yaklaşım

Özet: Bu vaka sunumunda, Fırat Üniversitesi Veteriner Fakültesi Doğum ve Jinekoloji Kliniği'ne getirilen safkan Arap ırkı 5 yaşlı bir kısrakta görülen bir perineal laserasyon olgusu sunulmuştur. Yapılan muayene sonucunda kısraklarda doğum sonrası ortaya çıkan rektovajinal yırtıklardan farklı olarak vulva dudaklarının sağlam olduğu ve yırtığın rektum, anüs ve vulvanın üstündeki perineal bölgede şekillendiği tespit edildi. Hayvanın tedavisi için 3 değişik tarihte perineoplasti operasyonu yapıldı, ancak rektovajinal fistül şekillendiği için hedeflenen başarıya ulaşamadı.

Anahtar kelimeler: Kısrak, perineoplasti, rektovajinal laserasyon.

Introduction

Perineal lacerations are common in primiparous mares. In cases of difficult parturition, rectovaginal tears occur as a result of the foal's abnormal presentation, position, and posture during parturition, as a result of excessive pressure of the foal's nails on the lateral and dorsal walls of the birth canal (Akar & Yıldız, 2017; Jalim & McKinnon, 2010). It is more common in mares than in cattle and other domestic animals. The prominence of the vestibulovaginal sphincter and the remnant of the hymen play an important role in the formation of rectovaginal laceration in primiparous mares (Elkasapy & Ibrahim, 2015). The rectum and vagina are

classified according to the degree of impact. First-degree lacerations involve only the dorsal commissure of the vulva and the vestibular mucosa. In second-degree lacerations, the vestibular mucosa and submucosa are affected. Lesions continue to the muscles of the perineal body, including the vulva muscle. Third-degree lacerations cause rupture of the perineum, anal sphincter, floor of the rectum, and roof of the vestibule, resulting in a common opening between the vestibulum and rectal mucosa (Kaşıkçı et al., 2005; Mosbah, 2012). The vagina and vestibulum are contaminated with feces because the integrity of the tissues is lost. Thus, inflammation occurs in the vagina, cervix, and even the uterus it tends to heal spontaneously in first and second-degree cases. Moreover, daily cleaning of wounds, anti-inflammatory drugs, broad-spectrum antibiotics, and antiseptic pomade can be applied (Akar & Yıldız, 2017). In third-degree tears, operative interventions are required to maintain the mare's fertility. Since the tissues are usually highly edematous and contaminated, the surgical intervention should be waited for 4-6 weeks, considering the degree of postpartum injury (Pooniya et al., 2019).

In this report, a case of rupture of the ventral part of the anal sphincter without deterioration of the integrity of the vulvar lips, unlike classical rectovaginal tears, is presented. In addition, it aimed to provide information about the surgical intervention approach in such a case of perineal rupture.

Case Description

A five-year-old Arabian mare was brought to Clinic of Obstetrics and Gynecology, Faculty of Veterinary Medicine, Firat University, with a complaint of a perineal laceration. According to the information received from the animal owner, it was learned that the mare vaginal delivery to a foal due to dystocia a year ago. It was reported that a perineal laceration was also present at the time of parturition. The perineal laceration was diagnosed by clinical examination of the mare (Figure 1).

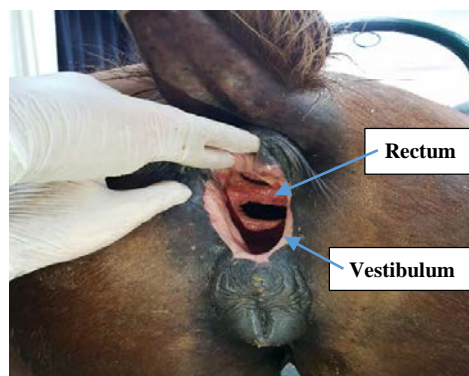


Figure 1. Preoperative view of the perineal laceration.

An informed consent form was obtained from the patient owner for the applications on the mare. Perineal laceration cases are usually seen after parturition. Therefore, before any operative intervention, it is necessary to wait about 6 weeks for the removal of postpartum edema. In this case, the mare was taken to the operation after 24 hours of limited feeding, as it had been 1 year since the case. After the operation, green grass was fed to ensure that the stool was soft. For the treatment of the mare, a 2-stage perineoplasty operation was planned, considering the Goetz technique (Kazemi et al., 2010). In the first stage, it was aimed to connect the septum between the rectum and vagina, and in the second stage, to connect the perineal region (in this case, suturing the anal sphincter because the vulvar lip preserved its integrity). Before the operation, the rectum was emptied as much as possible and a cotton plug was inserted into the rectum. The tail was bandaged and removed, and the area was disinfected. To provide anesthesia, Xylazine hydrochloride (0.20 mg/ kg) and 2% Lidocaine (1.0-1.5 mg/ 100kg) were administered into the epidural space. In addition, 2% Lidocaine (20 ml) was applied locally to the injury site. Simple continuous sutures were made with absorbable suture material (PGLA, USP: 1, Medeks, Türkiye) to connect the rectum and vaginal mucosa. Postoperatively, Penicillin G-Streptomycin sulfate (20,000/ 2.5 IU/ kg) was administered for 7 days and Meloxicam (0.6 mg/ kg) was administered intravenously as a single dose. For the second operation, the healing of the stitches was expected and the second operation was performed 21 days later. In the second operation, the integrity of the anal sphincter and the perineum region between the vulva and anus was ensured (Figure 2). In the examination performed 1 week after these operations, the desired success could not be achieved due to the formation of a rectovaginal fistula as a postoperative complication (Figure 3).

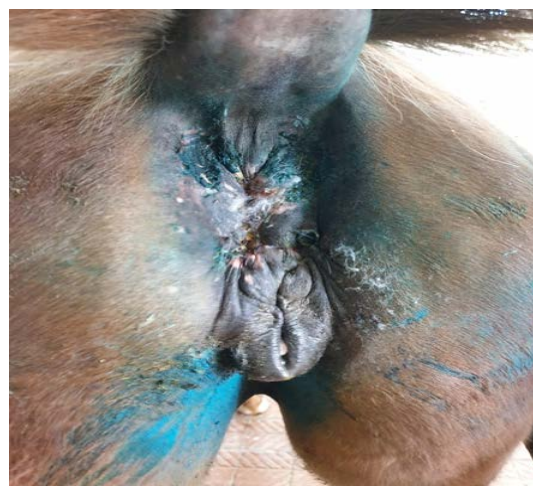

Figure 2. Suturing the anal sphincter and perineum after the second operation.

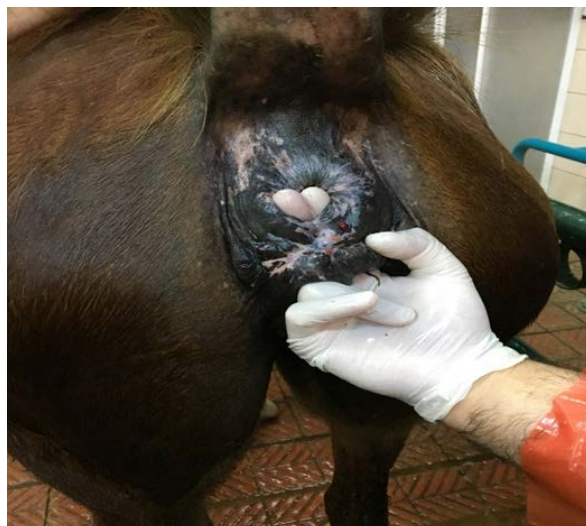

Figure 3. Rectovaginal fistula formed after the operation.

Discussion

Perineal lacerations in mares are a serious complication usually observed after difficult parturition. Contamination, inflammation, and edema occur in the region due to perineal lacerations (Singh & Saharan, 2017). Many methods, such as Goetz, Pedicle Flap, Aanes two-stage, and slight modifications, are used in cases of third-degree perineal laceration (Schönfelder & Sobiraj, 2004; Kazemi et al., 2010). Complications of the methods used for the treatment of third-degree perineal laceration cases include rectovaginal fistula formation, urine accumulation, complete opening of the repair, constipation, tenesmus, and performance difficulty (Kazemi et al., 2010). These operations are carried out in one stage or two-stage. Compared to a two-stage operation, where the second operation is performed 2-4 weeks later, the advantages of a single-stage operation include less hospital stay, shorter preoperative and postoperative care time, and a single surgical procedure. Two-stage operations are also advantageous in terms of the mare's ability to defecate more easily. Also, the rectum is less likely to be affected, and forcing the mare to defecate will result in the separation of the sutures or fistula (Kazemi et al., 2010). In this case, considering the advantages of the two-stage operation, a 2-stage operation was performed. However, a rectovaginal fistula formed as a postoperative complication.

It is reported that fertility will be positively affected after the operations performed in perineal laceration cases and the mare becomes pregnant again. Kazemi et al. (2010) reported that a pregnancy rate of 70.1% was obtained in mares who underwent operative intervention, and therefore, operative interventions are indicated, especially in mares that are genetically important., and it was reported that operative interventions are indicated, especially in mares

with genetically important issues. Papa et al. (2014) achieved a pregnancy rate in 14 of 18 mares due to the operative intervention with Modifiye Pouret's surgical method. In another study, the two-stage technique was modified and used in 6 mares with a 3rd-degree perineal laceration. Moreover, the recovery rate was 83.3%; the pregnancy rate was 50% (Samı et al., 2013).

Conclusion

As a consequence of this, operative interventions in cases of perineal laceration have been shown to have a positive impact on the mare's fertility. As a result, it is beneficial to experiment with surgical interventions, particularly in mares who are genetically important.

Financial Support

This research received no grant from any funding agency/sector.

Ethical Statement

This study does not present any ethical concerns.

Conflict of Interest

The authors declared that there is no conflict of interest.

Acknowledgements

This case report was presented as a poster presentation at "VIII. National & II. International Congress of Turkish Society of Veterinary Gynecology" between 10-13 October 2019 in Antalya/Türkiye.

References

- Akar, Y., & Yıldız, H. (2017). Puerperal Period Problems. In: Kaymaz M, Findik M, Risvanli A, Köker A. (Ed.), *Obstetrics and Gynecology in Mares* (pp.219-248). Medipress.
- Elkasapy, A.H., & Ibrahim, I.M. (2015). Contribution to reconstruction of third degree rectovestibular lacerations in mares. *Open Veterinary Journal*, 5(1), 23-26.
- Jalim, S.L., & McKinnon, A.O. (2010). Surgical correction of rectovaginal fistula in mares and subsequent fertility. *Australian Veterinary Journal*, 88(6), 211-214. <https://doi.org/10.1111/j.1751-0813.2010.00576.x>
- Kaşıkcı, G., Huriye, H.K., Alkan, S., Düzgün, O., & Aktaş, M. (2005). A modified surgical technique for repairing third-degree perineal lacerations in mares. *Acta Veterinaria Hungarica*, 53(2), 257-264. <https://doi.org/10.1556/avet.53.2005.2.11>
- Kazemi, M.H., Sardari, K., & Emami, M.R. (2010). Surgical repair of third-degree perineal laceration by Goetz technique in the mare: 7 cases (2000-2005). *Iranian Journal of Veterinary Research*, 11(2), 184-188.
- Mosbah, E. (2012). A modified one-stage repair of third-degree rectovestibular lacerations in mares. *Journal of Equine Veterinary Science*, 32(4), 211-215. <https://doi.org/10.1016/j.jevs.2011.08.024>

- Papa, F.O., Melo, C.M., Monteiro, G.A., Papa, P.M., Guasti, P.N., Maziero, R.R.D., Derussi, A.A.P., Magalhães, L.C.O. & Martin, I. (2014). Equine perineal and vulvar conformation correction using a modification of Poret's technique. *Journal of Equine Veterinary Science*, 34(3), 459-464. <https://doi.org/10.1016/j.jevs.2013.07.019>
- Pooniya, R., Sharma, S.K., Jhamb, D.K., Saini, R., & Kumar, S. (2019). One stage surgical management for third-degree recto-vaginal laceration in mares: A report of two cases. *The Indian Journal of Veterinary Sciences and Biotechnology*, 14(04), 59-62. <https://doi.org/10.21887/ijvsbt.14.4.16>
- Sami, N.S., Mohindroo, J., Mahajan, S.K., Raghunath, M., Sangwan, V., Kumar, A., Anand, A., Singh, T., & Singh, N. (2013). Surgical management of third degree perineal laceration in young mares. *Indian Journal of Animal Sciences*, 83(5), 525-526.
- Schönfelder, A.M., & Sobiraj, A. (2004). A vaginal mucosal pedicle flap technique for repair of rectovaginal fistula in mares. *Veterinary Surgery*, 33(5), 517-520. <https://doi.org/10.1111/j.1532-950x.2004.04071.x>
- Singh, P., & Saharan, S. (2017). Surgical management of perineal laceration in mares. *MOJ Surgery*, 4(4), 86-87.

***Trichodectes pinguis* (Phthiraptera: Ischnocera: Trichodectidae) and *Haemaphysalis erinacei* (Acari: Ixodida: Ixodidae) infestation on brown bears in Erzurum province**

Rıdvan KİRMAN^{1,a,*}, Muzaffer AKYÜZ^{1,b}, Veysel DOĞAN^{2,c}

¹Atatürk University, Faculty of Veterinary Medicine, Department of Parasitology, Erzurum, Türkiye;

²Kastamonu University, Faculty of Veterinary Medicine, Department of Animal Nutrition and Nutritional Disorders, Kastamonu, Türkiye.

*ORCID: <https://orcid.org/0000-0001-5437-089X>; ^bORCID: <https://orcid.org/0000-0002-6095-7870>; ^cORCID: <https://orcid.org/0000-0002-1148-5416>

*Corresponding author: ridvan.kirman@atauni.edu.tr

Received 25.11.2022 - Accepted 16.05.2023 - Published 30.06.2023

Abstract: Brown bears (*Ursus arctos*), which host various ectoparasites, are the largest carnivores in Türkiye. The present study represents tick and louse species found in brown bears in Erzurum. Four brown bears (3 dead, 1 alive) were brought to the parasitology laboratory and four brown bears were examined in terms of ectoparasite infestation. Transparency protocol was applied for louse samples, and species identification of all ectoparasites was performed under a stereo microscope. All lice and ticks were identified as *Trichodectes pinguis* and *Haemaphysalis erinacei*, respectively. There are limited studies concerning wildlife animal ectoparasites in Türkiye, especially on bears.

Keywords: Brown bear, *Haemaphysalis erinacei*, *Trichodectes pinguis*, *Ursus arctos*, wildlife.

Erzurum ilindeki boz ayılarında *Trichodectes pinguis* (Phthiraptera: Ischnocera: Trichodectidae) ve *Haemaphysalis erinacei* (Acari: Ixodida: Ixodidae) enfestasyonu

Özet: Bozayılar Türkiye'deki en büyük karnivorlardır ve birçok farklı ektoparazite konaklık yapmaktadırlar. Bu çalışmada, Erzurum ilindeki bozayılarda bulunan ektoparazit türleri sunulmuştur. Ektoparaziter muayene amacıyla bozayılar (3 ölü, 1 canlı) parazitoloji laboratuvarına getirildi. Bit türlerinin teşhisi amacıyla şeffaflandırma protokolü uygulandı. Bit ve kene türlerinin tür teşhisleri stereo mikroskop altında gerçekleştirildi. Dişi ve erkek bitler *Trichodectes pinguis* olarak teşhis edildi. Bir dişi ve bir erkek kene *Haemaphysalis erinacei* olarak tespit edildi. Türkiye'de özellikle ayılarda olmak üzere yabani hayvanların ektoparazitlerine yönelik az sayıda çalışma bulunmaktadır.

Anahtar kelimeler: Bozayı, *Haemaphysalis erinacei*, *Trichodectes pinguis*, *Ursus arctos*, vahşi yaşam.

Introduction

Brown bears (*Ursus arctos*) are the largest carnivores in Türkiye. They have widespread habitat in the Black Sea and Eastern Anatolia Regions. The bear population in Türkiye varies between 3,400-4,000, and the majority of this population is located in the Eastern Anatolia Region (Ambarlı et al., 2016). Wild animals carry a large number of ectoparasites that are not threatening to their health (Durden, 2001). However, they can cause adverse effects on animal

health by causing anemia, dermatitis, alopecia, skin sensitization, reduced growth rates, secondary infections, the transmission of pathogens, reduced reproductive success, and triggering inflammatory reactions (Durdan, 2001; Rakotonanahary et al., 2017). *Trichodectes* spp. (Phthiraptera: Ischnocera: Trichodectidae) can infest many animals, including bears (Durdan, 2001). There are a few studies about *Trichodectes pinguis* (*T. pinguis*) on bears around the world (Rogers & Rogers, 1976; Yokohata et al., 1990) and a study in Türkiye (Dik & Kılınç, 2015). Though the disease risk caused by chewing louse on brown bears is not known clearly, a previous study reported a case of alopecia and hyperpigmentation caused by chewing louse on bears (Esteruelas et al., 2016). Ticks can be vectors for some protozoans such as *Babesia* sp. and *Hepatozoon ursi*, which were detected in previous studies on bears (Ikawa et al., 2011; Kubo et al., 2008; Orkun & Emir, 2020). In this study aimed to identify the louse and tick species infesting in brown bears in Erzurum province of Türkiye.

Case Description

Brown bears (3 dead, 1 alive) that were found in the Yakutiye, Pasinler, and Uzundere districts of Erzurum were brought to the parasitology laboratory for ectoparasitic examinations. One of brown bear was alive and it was a cub. Therefore, ectoparasites were collected directly without the need for sedation. Ectoparasites were collected from bears with forceps and they were examined under a stereo microscope (Nikon, SMZ 745T, Japan). Transparency protocol was applied for species identification in lice. Lice were kept in 10% KOH solution for 24-48 hours and then in distilled water for 24 hours. It was again passed through the alcohol series (30-70-80-96%) every 24 hours. They were mounted on slides in entellan (Hopkins, 1954). Species identification of tick samples and lice was performed under a stereo microscope (Nikon, SMZ745T, Japan), and light microscope (Nikon, Eclipse Ci, Japan), respectively in accordance with morphological criteria (Dik & Kılınç, 2015; Estrada-Peña et al., 2017; Kusakisako et al., 2022).

Three of the four brown bears were observed to be infested with at least one ectoparasite species. Male and female lice that were collected from two adult bears were identified as *T. pinguis* (Figure 1). A female and a male tick were collected from a baby bear and they were identified as *Haemaphysalis erinacei* (*Hae. erinacei*) (Figure 2). There was no coinfection by ticks and lice.




Figure 1. *T. pinguis*, **a:** male, **b:** female, **c:** spiculum (black arrow), **d:** spermatheca (black arrow).




Figure 2. *Haemaphysalis erinacei*, Male; **a:** dorsal view, **b:** ventral view (spur on coxa IV (yellow arrow)), **c:** dorsal cornua (blue arrow), **d:** stigma (green arrow), Female; **e:** dorsal view, **f:** ventral view, **g:** female

Discussion

Wild animals and their ectoparasites play an important role as reservoirs and/ or vectors of zoonotic agents for humans and domestic animals (Morse, 1995). Limited studies are available regarding ectoparasites on wild mammals in Türkiye (Aydin et al., 2011; Dik & Yamaç, 2017; Orkun & Vatansever, 2021). Besides, studies on the presence of *T. pinguis* (Dik & Kılınç, 2015) and *Hae. erinacei* (Girişgin et al., 2018) in brown bears are limited. In the present study, *T. pinguis* and *Hae. erinacei* in brown bears were reported for the first time in Erzurum. *Trichodectes pinguis* has been reported from bears in this study for the second time in Türkiye. In a previous study, it was detected on a brown bear in Van province (Dik & Kılınç, 2015). *Haemaphysalis erinacei*, a three-host tick species, has been detected in foxes, hedgehogs, and rabbits in studies conducted on different wild animals in Türkiye (Estrada-Peña et al., 2017; Girişgin et al., 2018; Hoogstraal, 1959). Although it mostly affects hedgehogs and small and medium-sized mammals that hunt hedgehogs, there are studies showing that it also infests bears (Girişgin et al., 2018; Kolonin, 2007). Studies on bear ectoparasites in Turkey are limited due to the danger of bear attacks, geographical difficulties, and hunting ban (Dik & Kılınç, 2015).

Conclusion

In today's world, human beings are involved in wildlife for sport, picnics, finding new agricultural areas, and hunting. Therefore, it is necessary to investigate wild animals' ectoparasites, which are possible vectors and/or reservoirs for pathogens some of which are zoonotic. Although studies on wildlife are limited, the necessity of more studies in this area comes to the forefront due to the increase in the population of wild animals which are under protection.

Financial Support

This research received no grant from any funding agency/sector.

Ethical Statement

Ethical approval was obtained from the Ataturk University Animal Research Local Ethics Committee (Approval no: 2015/ 27) for the study.

Conflict of Interest

The authors declared that there is no conflict of interest.

Acknowledgment

This study was presented as a poster presentation at the “22nd Parasitology Congress” in Aydın, Turkey.

References

- Ambarlı, H., Ertürk, A., & Soyumert, A. (2016). Current status, distribution, and conservation of brown bear (Ursidae) and wild canids (gray wolf, golden jackal, and red fox; Canidae) in Turkey. *Turkish Journal of Zoology*, 40, 944-956. <https://doi.org/10.3906/zoo-1507-51>
- Aydın, M.F., Balkaya, İ., Aktaş, M., & Dumanlı, N. (2011). Erzurum ilinde üç kırmızı tilkide (*Vulpes vulpes*) kene (Ixodoidea) ve pire (Siphonaptera) türleri. *Türkiye Parazitoloji Dergisi*, 35(2), 110-113. <https://doi.org/10.5152/tpd.2011.27>
- Dik, B., & Kılınç Ö.O. (2015). First case of *Trichodectes pinguis* (Phthiraptera: Ischnocera: Trichodectidae) on a Bear (*Ursus arctos*) in Turkey. *Türkiye Parazitoloji Dergisi*, 39, 313-315. <https://doi.org/10.5152/tpd.2015.4040>
- Durden, L.A. (2001). Lice (Phthiraptera). In: Samuel, W.M., Pybus, M.J., Kocan, A.A. (Ed.), *Parasitic Diseases of Wild Mammals* (pp. 3e17). Iowa State University Press.
- Esteruelas, N.F., Malmsten, J., Bröjer, C., Grandi, G., Lindström, A., Brown, P., Swenson, J.E., Evans, A.L. & Arnemo, J.M. (2016). Chewing lice *Trichodectes pinguis pinguis* in Scandinavian brown bears (*Ursus arctos*). *International Journal for Parasitology: Parasites and Wildlife*, 5, 134-138. <https://doi.org/10.1016/j.ijppaw.2016.02.002>
- Estrada-Peña, A., Mihalca, A.D., & Petney, T.N. (2017). *Ticks of Europe and North Africa*. Springer.
- Girişgin, A., Çimenlikaya, N., Bah, S., Aydın, A., & Girişgin, O. (2018). Türkiye’de Bazı Yabani Memelilerde Bulunan Dış Parazit Türlerinin İlk Kayıtları. *Uludağ Üniversitesi Veteriner Fakültesi Dergisi*, 37(2), 133-136.
- Hoogstraal, H. (1959). Biological observations on certain Turkish *Haemaphysalis* ticks (Ixodoidea-Ixodidae). *Journal of Parasitology*, 45(2), 227-232. <https://doi.org/10.2307/3286538>
- Hopkins, G. H. E. (1954). Notes on some *Mallophaga* from bears. *The Entomologist*, 87, 140-146.
- Ikawa, K., Aoki, M., Ichikawa, M. & Itagaki, T. (2011). The first detection of *Babesia* species DNA from Japanese black bears (*Ursus thibetanus japonicus*) in Japan. *Parasitology International*, 60, 220-222. <https://doi.org/10.1016/j.parint.2011.02.005>
- Kolonin, G.V. (2007). Mammals as hosts of Ixodid ticks (Acarina, Ixodidae). *Entomological Review*, 87, 401-412. <https://doi.org/10.1134/S0013873807040033>
- Kubo, M., Uni, S., Agatsuma, T., Nagataki, M., Panciera, R. J., Tsubota, T., Nakamura, S., Sakai, H., Masegi, T. & Yanai, T. (2008). *Hepatozoon ursi* n. sp. (Apicomplexa: Hepatozoidae) in Japanese black bear (*Ursus thibetanus japonicus*). *Parasitology International*, 57, 287-294. <https://doi.org/10.1016/j.parint.2008.01.002>
- Kusakisako, K., Niiyama, H., Asano, E., Haraguchi, A., Hakozaki, J., Nakayama, K., Nakamura, S., Shindo, J., Kudo, N., & Ikadai, H. (2022). Morphological and molecular phylogenetical identification of *Tricodectes pinguis* from Japanese black bears (*Ursus thibetanus japonicus*) in Aomori Prefecture, Japan. *The Journal of Veterinary Medical Science*, 84(7), 1015-1018. <https://doi.org/10.1292/jvms.22-0107>
- Morse, S.S. (1995). Factors in the emergence of infectious diseases. *Emerging Infectious Diseases*, 1, 7-15.
- Orkun, O., & Emir, H. (2020). Identification of tick-borne pathogens in ticks collected from wild animals in Turkey. *Parasitology Research*, 119, 3083-3091. <https://doi.org/10.1007/s00436-020-06812-2>
- Orkun, O., & Vatansver, Z. (2021). Rediscovery and first genetic description of some poorly known tick species: *Haemaphysalis kopetdaghica* Kerbabaev, 1962 and *Dermacentor raskemensis* Pomerantzev, 1946. *Ticks and Tick-borne Diseases*, 12(4), 101726. <https://doi.org/10.1016/j.ttbdis.2021.101726>
- Rakotonanahary, R. J., Harrison, A., Maina, A. N., Jiang, J., Richards, A. L., Rajerison, M., & Telfer, S. (2017). Molecular and serological evidence of flea-associated typhus group and spotted fever group rickettsial infections in Madagascar. *Parasites & Vectors*, 10, 125. <https://doi.org/10.1186/s13071-017-2061-4>
- Rogers, L.L., & Rogers, S.M. (1976). Parasites of Bears: A review. *Bears: their biology and management*, 411-430.
- Yokohata, Y., Fujita, O., Kamiya, M., Fujita, T., Kaneko, K. & Ohbayashi, M. (1990). Parasites from the Asiatic black bear (*Ursus thibetanus*) on Kyushu Island, Japan. *Journal of Wildlife Diseases*, 26, 137-138. <https://doi.org/10.7589/0090-3558-26.1.137>

Evaluation of common liver masses and clinical and operative findings in a dog

Ali Said DURMUŞ^a, Eren POLAT^{b,*}

Firat University, Faculty of Veterinary Medicine, Department of Veterinary Surgery, Elazığ, Türkiye.

^aORCID: <https://orcid.org/0000-0003-4873-5690>; ^bORCID: <https://orcid.org/0000-0002-3999-1310>

*Corresponding author: erenpolat@firat.edu.tr

Received 11.05.2023 - Accepted 08.06.2023 - Published 30.06.2023

Abstract: In this case report, it was aimed to evaluate the clinical, laboratory and operative findings of liver masses encountered in a 13-year-old Golden Retriever dog. It was determined that the dog who presented with complaints of difficulty in walking and swelling in the abdominal region had an excessive swelling in the abdominal region and an asymmetrical appearance. It was determined that hematocrit (HCT), red blood cells count (RBC) and hemoglobin level (HGB) decreased significantly, while alanine aminotransferase (ALT) activity increased critically. The radiographic and ultrasonographic examination of the abdomen, it was determined that the internal organs were not visible and abnormal fluid was accumulated. An experimental laparotomy was performed. During the operation, tumor-like masses in different sizes were determined on the liver lobes. In the postoperative period, the patient was euthanized at the request of the owner, due to the worsening of the patient's health condition and the recurrence of abdominal distension.

Keywords: Dog, liver, mass, tumor.

Bir köpekte karşılaşılan yaygın karaciğer kitleleri ile klinik ve operatif bulgularının değerlendirilmesi

Özet: Bu olgu sunumunda 13 yaşındaki Golden Retriever ırkı bir köpekte karşılaşılan karaciğer kitlelerinin klinik, laboratuvar ve operatif bulgularının değerlendirilmesi amaçlandı. Yürüme güçlüğü ve karın bölgesinde şişlik şikayeti ile gelen köpeğin abdominal bölgesinde aşırı bir şişlik olduğu ve asimetrik bir görünümünün olduğu belirlendi. Hematokrit değeri (HCT), alyuvar miktarı (RBC) ve hemoglobin düzeyinin (HGB) belirgin olarak düştüğü, alanine aminotransferase (ALT) düzeyinin ise kritik düzeyde arttığı belirlendi. Abdomenin radyografik ve ultrasonografik muayenesinde iç organların net olarak görünmediği ve anormal bir sıvı biriktiği belirlendi. Deneysel laparotomi yapıldı. Operasyon sırasında karaciğer lobları üzerinde farklı boyutlarda tümör benzeri kitlelerin olduğu belirlendi. Postoperatif dönemde hastanın sağlık durumunun kötüye gitmesi ve karın şişliğinin nüksetmesi sebebiyle hasta sahibinin isteğiyle hasta ötenazi edildi.

Anahtar kelimeler: Köpek, karaciğer, kitle, tümör.

Introduction

Primary liver tumors account for only 0.6% to 1.5% of all tumor cases encountered in dogs (Liptak et al., 2013; Patnaika et al., 1980). The incidence of liver tumors developing because of metastasis of tumors originating from the spleen, pancreas, and gastrointestinal system is 2.5 times higher than primary liver tumors. While liver tumors are mostly malignant in dogs, they are benign in cats (Liptak et al., 2013).

Primary liver tumors can be seen in three different morphologies such as solid, nodular and diffuse (Liptak et al., 2013; Saritaş et al., 2014). Solid masses are limited to a single liver lobe, while nodular masses occur in more than one liver lobe (Liptak et al., 2013). The most radical technique in the treatment of liver masses is lobectomy (Saritaş et al., 2014). Hepatocellular carcinomas and benign tumors with solid character have a good prognosis after surgical extirpation and a low risk of recurrence (Liptak et al., 2013).

Hemangiosarcoma is a prevalent form of sarcoma affecting the liver in dogs (Kang et al., 2009; Karabağlı et al., 2011). It is characterized by the development of malignant tumors originating from vascular endothelial cells, commonly observed in the spleen, right atrium, and liver (Hirsch et al., 1981; Kang et al., 2009; Martins et al., 2013; Park et al., 2016). Certain breeds, including German Shepherds, Golden Retrievers, Labrador Retrievers, Boxers, Schnauzers, and Bernese Mountain Dogs, have been found to have a predisposition to hemangiosarcoma, which is typically diagnosed in older dogs (Hirsch et al., 1981; Karabağlı et al., 2011; Martins et al., 2013). In hemangiosarcoma cases, clinical symptoms often differ according to the organ where the tumor is located. The most important symptom seen in hepatic hemangiosarcomas is the hemoperitoneum due to intra-abdominal hemorrhages. An increase in abdominal volume and an asymmetrical appearance occur due to hemoperitoneum (Martins et al., 2013; Park et al., 2016).

In this case report, it was aimed to evaluate the clinical, laboratory and operative findings of liver masses encountered in a 13-year-old Golden Retriever dog.

Case Description

The case involved a 13-year-old male Golden Retriever dog who had been brought to Firat University Animal Hospital due to a complaint of pronounced abdominal swelling. During the history assessment, it was revealed that the dog had been experiencing fatigue, gait disturbance, and excessive abdominal swelling for the past month.

During the clinical examination, thorough inspection and palpation revealed a notable and asymmetrical swelling in the abdomen. Additionally, it was observed that the dog exhibited signs of dehydration, and the capillary refill time was delayed. Radiographic examination indicated indistinct visualization of the abdominal organs, accompanied by abnormal fluid accumulation in the abdomen (Figure 1). Subsequent ultrasonographic examination was impeded by the presence of fluid accumulation, hindering the assessment of internal organs. The puncture procedure was performed to determine the nature of the abdominal fluid, which confirmed the presence of blood (hemoperitoneum).

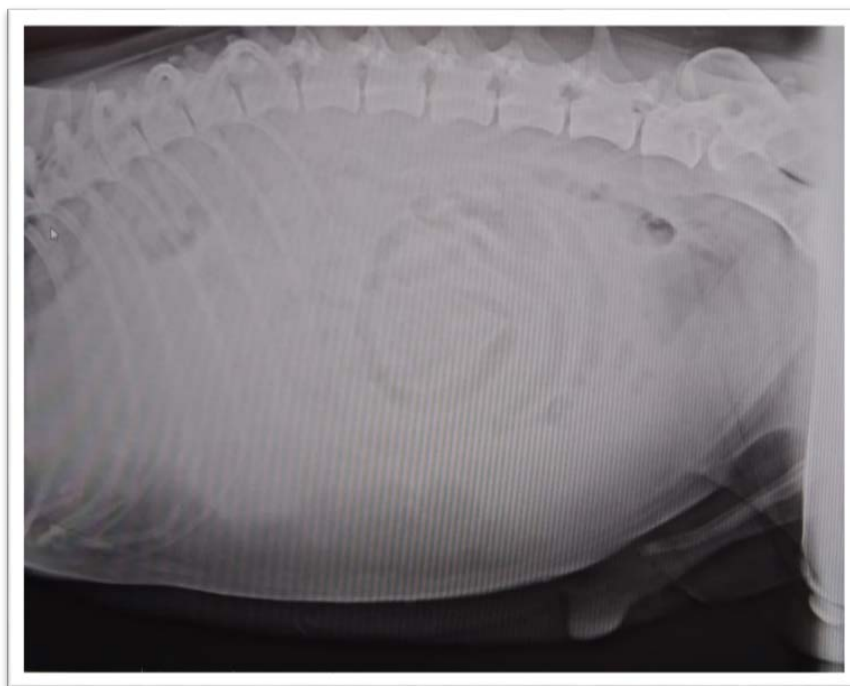


Figure 1. Laterolateral abdominal radiograph.

The dog's hemogram examination revealed an elevated count of granulocytes, while there was a significant decrease in critical values such as hematocrit (HCT), red blood cells count (RBC), and hemoglobin (HGB) (Table 1).

Table 1. Results of some hemogram parameters.

Parameter	Values	Unit	References Value
RBC	1.53	$10^{12}/L$	4.95-7.87
HGB	3.3	g/dL	11.9-18.9
HCT	10.4	%	35-57
PLT	151	$10^9/L$	211-621
MCV	68.1	fL	66-77
MCH	21.5	pg	21-26.2
MCHC	32.0	g/dL	32-36.3

RBC: red blood cells, HGB: hemoglobin, HCT: hematocrit, PLT: platelet, MCV: mean cell volume, MCH: mean cell hemoglobin, MCHC: mean cell hemoglobin concentration.

Moreover, the routine biochemical analysis of blood serum indicated a notable increase in levels of Alanine aminotransferase (ALT), amylase (AMY), glucose (GLU), albumin (ALB), and creatine kinase (CK). Additionally, the dog exhibited hypoalbuminemia and hypoproteinemia (Table 2).

Table 2. Results of some blood biochemistry parameters.

Parameter	Values	Unit	References Value
ALT	481	U/L	10-118
ALP	21	U/L	20-150
CK	422	U/L	20-200
AMY	> 3000	U/L	400-2500
GLU	30.84	Mmol/L	3.89-7.95
ALB	18.3	g/L	22-44
TP	47.7	g/L	52-82

ALT: alanine aminotransferase, ALP: alkaline phosphatase, CK: creatine kinase, AMY: amylase, GLU: glucose, ALB: albumin, TP: total protein.

After performing a puncture procedure, it was observed that the bloody fluid in the dog's abdominal cavity re-accumulated one week following its initial drainage. Based on clinical and laboratory examinations, there was a suspicion that the condition may involve progressive hepatocellular damage. Due to the respiratory distress and increased fatigue caused by the hemoperitoneum, an experimental laparotomy was deemed necessary with the consent of the dog's owner.

The surgical site for the operation was prepared spanning from the dog's tenth intercostal space to the aperture pelvis cranialis. The dog was administered 2 mg/kg xylazine hydrochloride intramuscularly, followed by 10 mg/kg ketamine hydrochloride as described by Safak et al. (2021) for general anesthesia, approximately 10 minutes later. A median incision was made, starting 2 cm caudal to processus xiphoidea to the 2 cm cranial to the dog's penis. By conducting blunt dissection, the subcutaneous connective tissues were separated, exposing the line alba (Figure 2). Using scissors with a blunt end, the abdominal cavity was accessed. Subsequently, approximately 8 liters of bloody fluid was drained via an aspirator. Following fluid drainage, a comprehensive examination of all abdominal organs, particularly the liver, was performed, revealing no pathological formations except for the presence of numerous nodular masses of varying sizes in the liver. The affected liver lobes were carefully taken out from the abdomen and inspected (Figure 2). Based on the patient's age, breed, and clinical examination findings, hemangiosarcoma was suspected. Masses were taken for biopsy from the liver lobes of the patient. The abdominal cavity was closed using standard surgical procedures, and the skin was sutured with simple separate stitches. Postoperatively, the patient received intramuscular amoxicillin-clavulanic acid with a dosage of 8.75 mg/kg/day for one week. Pain management was provided with intravenous administration of meloxicam at a dose of 0.3 mg/kg/day for one week. The dog's owner was informed about the option of starting chemotherapy for the patient. In the initial week following the surgery, the patient's general condition was good, attributed to the evacuation of the hemoperitoneum. However, on the tenth

postoperative day, due to the recurrence of abdominal distension, worsening general condition, and unfavorable prognosis, and at the request of the owner, the patient was euthanized. According to the morphological structure of the masses, it was thought that it might be hemangiosarcoma, since the patient's owner did not accept the necropsy of the patient after euthanasia and the histopathological results were not reported to us.

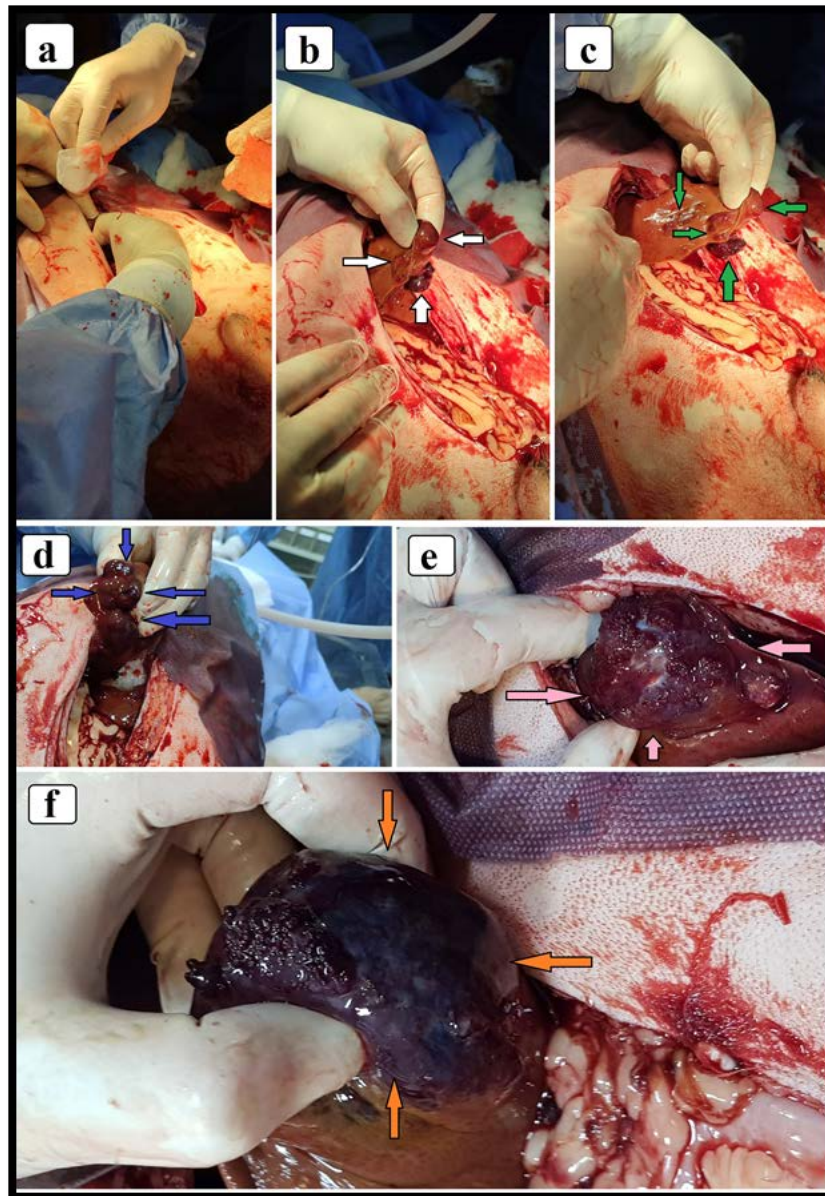


Figure 2. Incision of the laparotomy line (a), removal of the liver from the abdomen (b), appearance of different nodular masses on the liver lobes (b. c. d. e. f) (arrows).

Discussion

Only 0.6% to 1.5% of tumors in dogs are of hepatic origin (Patnaika et al., 1980; Liptak et al., 2013). The incidence of liver tumors, which are formed because of metastasis of tumors originating from the spleen, pancreas and digestive system, is higher (Liptak et al., 2013). Park et al. (2016) reported that the tumor in a Siberian Husky dog, in which they detected hemangiosarcoma in its liver, originated in the spleen. Martins et al. (2013) reported that a Pinscher dog with hemangiosarcoma detected in the left lobe of its liver had dark red or black nodular lesions on the lung, kidney, stomach and peritoneum. Kang et al. (2009) reported that they found primary hemangiosarcoma in the liver of a Schnauzer dog. In this case report, a large number of tumoral formations were detected in the liver of the dog, and other organs were macroscopically normal, and it was thought that it might be a tumor of liver origin.

Hemangiosarcoma is recognized as one of the most prevalent liver tumors in dogs, commonly observed in older individuals. Certain breeds such as German Shepherds, Golden Retrievers, Labrador Retrievers, Boxers, Schnauzers, and Bernese Mountain dogs are known to have a predisposition to this condition (Hirsch et al., 1981; Kang et al., 2009; Karabağlı et al., 2011; Martins et al., 2013). Park et al. (2016) reported a case of hepatic hemangiosarcoma in a Siberian Husky (12 years old), and it also been described in 3 years old Pinscher dog (Martins et al., 2013) and 6 years old Schnauzer dog (Kang et al., 2009). In the present case report, we discussed the encounter of numerous masses, suspected to be primary liver hemangiosarcoma, in a 13-year-old Golden Retriever dog.

The most common clinical finding in liver hemangiosarcomas is hemoperitoneum due to intra-abdominal hemorrhages. Due to hemoperitoneum, an increase in volume and an asymmetrical appearance occur in the abdomen. Exercise intolerance and prolongation of capillary filling time are other important symptoms encountered in hepatic hemangiosarcoma cases (Kang et al., 2009; Martins et al., 2013; Park et al., 2016). In this case report, it was determined that the dog's abdominal volume increased due to hemoperitoneum and had an asymmetrical appearance. Again, the dog's exercise intolerance and the delayed capillary refill time are compatible with the literature. Kang et al. (2009) reported that the serosal details disappeared in the abdominal radiograph of the dog with hepatic hemangiosarcoma and the fluid was homogeneously distributed to the abdomen. In this case report, the presence of abnormal fluid accumulation in the abdomen and the inability to visualize the abdominal organs in the radiographic and ultrasonographic examinations are compatible with the literature.

Similar to many other diseases, hemangiosarcoma cases lead to alterations in hematological and blood biochemistry parameters. In a study by Park et al. (2016) involving a

dog with spleen-derived hemangiosarcoma, a decrease in HCT, HGB, and platelet (PLT) levels were observed, alongside a significant increase in ALT, AST, and ALP activities. Similarly, Kang et al. (2009) reported a case of primary liver hemangiosarcoma in which HCT and PLT levels decreased, while ALT, AST, and ALP activities increased significantly. Hypoglycemia, hypoalbuminemia, and hypoproteinemia were also detected in the dog. In this case report, it was determined that the dog with a liver-originating mass exhibited a decrease in RBC, HCT and HGB values, along with a significant increase in serum ALT, CK, and AML activities. Additionally, the dog was found to have hypoalbuminemia and hypoproteinemia. In the context of hepatic hemangiosarcomas, the dog's history, clinical examination findings, as well as HCT, HGB, and ALT activities, were deemed crucial markers. Unlike other cases, the increase in AML value suggested that the dog also had pancreatic damage.

Liver tumors can be seen in solid, nodular, or diffuse morphologies (Liptak et al., 2013; Saritaş et al., 2014). Solid masses are limited to a single liver lobe, while nodular masses occur in more than one liver lobe (Liptak et al., 2013). The most radical technique in the treatment of liver masses is lobectomy. Another option in the treatment of hepatocellular carcinomas, other than lobectomy, is liver transplantation (Saritaş et al., 2014; Atlas et al., 2021). Park et al. (2016) reported that they applied lobectomy and splenectomy to the dog they detected hemangiosarcoma in the left lobe of the liver and spleen. They reported that they wanted to apply chemotherapy in the postoperative period, but the patient's owner did not accept it. They reported that the mass metastasized to the lungs in the following period and the patient died in a short time. Kang et al. (2009) reported that they started symptomatic treatment for a dog with primary hepatic hemangiosarcoma, but then discontinued the medication due to the owner's further investigations and refusal to treat. It was reported that the patient died in a very short time. In this case report, it was decided to administer chemotherapy because the mass was nodular and diffuse morphology, lobectomy would not yield any results, and finding the necessary donor for liver transplantation was even more difficult than human medicine. However, the patient's general condition deteriorated, the prognosis was unfavorable, and the patient was euthanized at the request of the owner.

Conclusion

In conclusion, in this case report, clinical, laboratory, and operative findings of diffuse liver masses observed in a dog with clinical and laboratory findings consistent with primary liver hemangiosarcoma, which is rarely encountered in dogs, and is known to have an unfavorable prognosis, were discussed. It has been concluded that this case report will

contribute to the literature and form a basis for treatment options that can be developed in the future.

Financial Support

This research received no grant from any funding agency/sector.

Ethical Statement

This study does not present any ethical concerns.

Conflict of Interest

The authors declared that there is no conflict of interest.

References

- Atlas, A., Tatlı, F., Büyükfirat, E., & Karahan M.A. (2021). Karaciğer transplantasyonu cerrahisinde postoperatif mortalite ve morbiditeye etki eden faktörlerin retrospektif incelenmesi. *Journal of Anesthesiology and Reanimation Specialists' Society*, 29(1), 18-24. <https://doi.org/10.5222/jarss.2021.88597>
- Hirsch, V.M., Jacobsen, J., & Mills, J.H.L. (1981). A retrospective study of canine hemangiosarcoma and its association with acanthocytosis. *Canadian Veterinary Journal*, 22(5), 152-155.
- Kang, M.H., Heo, R.Y., & Park, H.M. (2009). Primary hepatic hemangiosarcoma (HSA) in a Schnauzer dog. *Korean Journal of Veterinary Research*, 49(3), 249-252.
- Karabağlı, G., Düzgün, O., Yıldar, E., Erdoğan, Ö., & Gürel, A. (2011). A hemangiosarcoma case in a dog. *İstanbul Üniversitesi Veteriner Fakültesi Dergisi*, 37(2), 161-165.
- Liptak, J.M., Dernell, W.S., & Withrow, S.J. (2013). Liver tumors in cats and dogs. *Compendium on Continuing Education for the Practicing Veterinarian*, 26(1), 50-57.
- Martins, B.D.C., Torres, B.B.J., Rodriguez, A.A.M., Gamba, C.O., Cassali, G.D., Lavalle, G.E., Martins, G.D.C., & Melo, E.G. (2013). Clinical and pathological aspects of multicentric hemangiosarcoma in a Pinscher dog. *Arquivo Brasileiro de Medicina Veterinária e Zootecnia*, 65(2), 322-328. <https://doi.org/10.1590/S0102-09352013000200003>
- Park, J., Lee, H.B., & Jeong, S.M. (2016). Liver lobe torsion with hemangiosarcoma in a dog. *Journal of Veterinary Clinics*, 33(6), 376-380. <http://dx.doi.org/10.17555/jvc.2016.12.33.6.376>
- Patnaika, A.K., Hurvitz, A.I., & Lieberman, P.H. (1980). Canine hepatic neoplasms: a clinicopathologic study. *Veterinary Pathology*, 17(5), 553-564. <https://doi.org/10.1177/030098588001700504>
- Safak, T., Yilmaz, O., Ercan, K., Yuksel, B., Ocal, H. (2021). A case of vaginal hyperplasia occurred the last trimester of pregnancy in a Kangal bitch. *Ankara Üniversitesi Veteriner Fakültesi Dergisi*, 68(3), 307-310. <https://doi.org/10.33988/auvfd.76465>
- Sarıtaş, Z.K., Bozkurt, M.F., Korkmaz, M., Başer, F.D., & Civelek, T. (2014). Hepatocellular carcinoma in a dog. *Erciyes Üniversitesi Veteriner Fakültesi Dergisi*, 11(3), 221-225.

Aluminum and toxicity

Sedat GÖKMEN^{1,a,*}, Burcu GÜL^{2,b}

¹Kastamonu University, Faculty of Veterinary Medicine, Department of Pharmacology and Toxicology, Kastamonu, Türkiye; ²Fırat University, Faculty of Health Sciences, Department of Nursing, Elazığ, Türkiye.
^aORCID: <https://orcid.org/0000-0002-4793-3030>; ^bORCID: <https://orcid.org/0000-0002-9122-8953>

*Corresponding author: sgokmen@kastamonu.edu.tr

Received 09.05.2023 - Accepted 20.06.2023 - Published 30.06.2023

Abstract: Aluminum (Al) is the third most prevalent element on earth after oxygen and silicon. Al compounds are used in the production of many different products including pots, pans, paints, varnishes, lubricants, cosmetics, vaccinations, pharmaceuticals, and nano-carrier systems, in the field of veterinary medicine and industry. The toxicity in animals can occur through various routes, including ingestion (food, drinking water), inhalation (air, pharmaceutical, agrochemical), and injection (pharmaceutical, vaccine). Acute poisoning in animals is rare and usually occurs following exposure. Numerous pathological effects have been associated with Al accumulation in mammalian tissues. The accumulation in tissues can Al accumulation in mammalian tissues causes various pathological disorders affecting nervous, immune, skeletal, reproductive system, lungs and breast health. The toxic effects of Al cause oxidative stress, immunological changes, genotoxicity, proinflammatory, peptide denaturation or transformation, enzymatic dysfunction, metabolic dysregulation, amyloidogenesis, membrane disruption, iron dyshomeostasis, apoptosis, necrosis and dysplasia. Al is neurotoxic, increases the permeability of the blood brain barrier and inhibits many important enzymes in the brain. This study aimed to reveal the toxicity of Al, its mechanism of action and its relationship with conditions such as vaccines, cancer, etc. in animals.

Keywords: Aluminum, effects, toxicity, veterinary medicine.

Alüminyum ve toksisite

Özet: Alüminyum (Al), oksijen ve silikondan sonra yeryüzünde en yaygın bulunan üçüncü elementtir. Al bileşikleri, veteriner hekimlik ve sanayi alanında tencere, tava, boya, vernik, yağlayıcı, kozmetik, aşı, ilaç ve nano-taşıyıcı sistemler gibi birçok farklı ürünün üretiminde kullanılmaktadır. Hayvanlarda toksisite, yutma (gıda, içme suyu), soluma (hava, farmasötik, zirai ilaç) ve enjeksiyon (ilaç, aşı) dahil olmak üzere çeşitli yollarla meydana gelebilir. Hayvanlarda akut zehirlenme nadirdir ve genellikle kronik maruziyetin bir sonucu olarak ortaya çıkar. Çok sayıda patolojik etki, memeli dokularında Al birikimi ile ilişkilendirilmiştir. Dokulardaki birikimi sinir, bağışıklık, iskelet, üreme sistemi, akciğer ve meme sağlığını etkileyen çeşitli patolojik bozukluklara neden olur. Al'ın toksik etkileri oksidatif strese, immünolojik değişikliklere, genotoksositeye, proinflatuar etkiye, peptit denatürasyonuna veya transformasyonuna, enzimatik işlev bozukluğuna, metabolik düzensizliğe, amiloidogenez, membran bozulmasına, demir dishomeostazına, apoptoz, nekroz ve displaziye neden olur. Al nörotoksiktir, kan beyin bariyerinin geçirgenliğini bozar ve beyindeki birçok önemli enzimi inhibe eder. Bu çalışmanın amacı hayvanlarda Al'un toksisitesi, etki mekanizması ve aşı, kanser vb. durumlarla ilişkisini ortaya koymaktır.

Anahtar kelimeler: Alüminyum, etkiler, zehirlilik, veteriner hekimlik.

Introduction

Aluminum (Al) is widespread in the environment, constituting approximately 8% of the earth's crust. After oxygen and silicon, it is the third most prevalent element (Gupta et al., 2013; Herndon, 2015), and it was first identified in 1827 (Liu et al., 2008). Al is a soft, nonmagnetic, ductile, and silvery-white metal (Soni et al., 2001).

Al metal is derived primarily from bauxite, which contains Al (Gupta, 2012a). Natural processes or anthropogenic sources both release it into the environment (Bjerregaard et al., 2015). Al occurs naturally in the trivalent state (Al^{3+}) as silicates, oxides, and hydroxides. Al does not exist in the environment as a pure metal because of its high reactivity; instead, it combines with other elements, for example, sodium and fluorine, and forms combinations with organic substances (Gupta, 2012a). The substances in question are Al chloride, Al hydroxide, Al nitrate, Al sulfate, Al potassium, Al phosphate, Al ammonium sulfate, and Al silicate (Igbokwe et al., 2019).

In environments contaminated by industrial waste, both animals and humans may be exposed to high levels of Al. Several chemical compounds containing Al are widely used in a wide range of products and processes. The compounds are used in pharmaceuticals (drugs, buffered aspirin antacids, astringents), vaccines, fumigants, and pesticides, in addition to paints and varnishes, cosmetics, detergents, water treatment and purification, tanning leather, waterproofing clothes and concretes, industrial filtration, and measuring radiation exposure (Gupta, 2012a; Igbokwe et al., 2019).

While Al rarely has toxicological consequences in animals when exposed acutely, it can cause a number of problems when exposed subacutely or chronically. Toxicosis induced by Al accumulation in mammalian tissues has been linked to numerous pathological effects. According to reports, poisoning from Al accumulation in mammalian tissues can cause a variety of pathological disorders that affect the nervous system, immune system, skeleton system, lungs, mammary health, and reproductive system.

Al primarily accumulates in the nervous tissues and brain. It is believed to play a significant role in the emergence of neurodegenerative diseases (such as Parkinson's disease) in humans. It is also associated with encephalopathy and amyotrophic lateral sclerosis. In Simmental calves, Frank et al. (1992) reported multifocal polioencephalomyelomalacia correlated with high Al levels (Frank et al. 1992). Many domestic and wildlife species, in addition to fish, have shown adverse effects from high Al levels. Al has also been involved in the etiology of grass tetany, and a clinical description such as grass tetany was reported. Because Al quickly passes the placental and the blood-brain barrier, developmental toxicity and

neurotoxicity appear to be of special concern when it comes to Al toxicity. Al phosphide, a common insecticide, has been found in cases of cow poisoning, which is of interest from a toxicological perspective. In cases like these, the majority of the hazardous effects arise from phosphine (PH₃) gas, which is produced from phosphide in the gastrointestinal system (Igbokwe et al., 2019; Gupta, 2012a).

Toxicokinetic: Al toxicity in animals can occur through various routes, including ingestion (food and drinking water), inhalation (air, pharmaceuticals, and agrochemicals), and injection (pharmaceuticals and vaccines). The toxicity of Al depends on various factors, such as the age and health of the animal, the dose and duration of exposure, and the route of exposure (Gupta, 2012a, b). Al is absorbed after oral or inhalation exposure, while little or none is absorbed after dermal exposure. Al's bioavailability depends on its chemical form and particle size. After oral exposure, Al is primarily absorbed in the jejunum and duodenum. Al may be dissolved from insoluble species such as Al(OH)₃ by the gastric's acidic pH, facilitating absorption. It is well established that consuming Al(OH)₃ with citrus juices or certain common organic components of the diet (citrate, lactate and succinate, etc.) may significantly enhance Al absorption. Al is probably mostly taken in by passive diffusion through paracellular routes. Al could be taken up by mucous cells, which may prevent it from getting into the body. Free Al ions are found in very small amounts because they combine with numerous compounds in the body, amino acids, nucleotides, carbohydrates, and macromolecules. So, the toxicokinetic and toxicodynamic of Al can be different based on what these complexes are made of. Between 80 and 90% of the Al in the blood is linked to proteins in the plasma. There is evidence that Al binds mostly to transferrin and only a little bit to albumin. After dogs get Al through an IV, the average t_{1/2} of Al in their plasma is about 4.5 h. Al circulates to all organs, with the largest concentration in bone. Post-inhalation lung concentrations are the largest. The lungs contain 25% of Al and the skeleton 50%. Al accumulates in bone after long-term oral exposure and is slowly released. Al accumulates in the tissues of the brain, liver, kidneys, and hematological system. In the lungs, Al levels rise with aging. Al accumulates in the nucleus, lysosomes, and chromatin of the cell. Al levels in the brain are generally lower than in many other tissues. Al is known to cross the blood-brain barrier and get into the brain through transferrin receptor-mediated endocytosis. Al can infiltrate the brain via the olfactory tract, nasal epithelium, and axonal transport following inhalation. It's worth noting that the cells that accumulate the most Al are long-lived postmitotic cells like neurons. Increases in Al concentrations in the brain of rabbits of four to tenfold and ten to twentyfold are associated with neurotoxicity and mortality, respectively. An energy-dependent process actively removes Al from the brain. However, it has

been reported that with the increase in iron load in the body, the accumulation of Al in the tissues decreases, and the accumulation of Ca or Mg deficiency in the brain and tissues may increase. Aluminum is predominantly eliminated in the urine, with only trace amounts in the bile. Renal Al elimination depends on the Al complex. Renal Al elimination depends on the Al complex. Al in a low-molecular-weight compound can be filtered and expelled by the renal glomeruli, but not in a high-molecular weight complex. Animal studies show that Al levels in urine can rise 14-fold after a single exposure. Al is mostly eliminated in urine in the first 24 hours after exposure. This could be because of the high Al concentrations, which likely created unfilterable Al complexes, lowering the plasma filterable Al percentage. Aluminum only excretes a small amount in the milk due to the restricted GI tract absorption of Al. Unabsorbed Al is excreted in the feces following oral consumption (Gupta, 2012a).

Mechanism of the toxicity: Aluminum alters the vast majority of physical and cellular processes. Al's toxicity may be due to its interaction with the plasma membrane, apoplasmic, and symplasmic targets. Neurotoxic effects, such as neuronal atrophy are the most serious complications of Al toxicity (Jaishankar et al., 2014). Al's toxicity results primarily from its pro-oxidant activity, which causes oxidative stress, free radical attack, and lipid oxidation. Al ions interact with oxygen-containing amino acids, side chains, and the protein backbone to convert protein polypeptides to secondary structures, denaturing or altering their conformation or structure, as seen in β -amyloid. Al binds to nucleotide phosphate groups, affecting energy metabolism. Hepatocytes exposed to Al have decreased ATP synthesis, glycolysis, tricarboxylic acid cycle activity, and lipid oxidation. These metabolic disturbances may cause Al-exposed animals to lose weight and produce fewer eggs. Also, exposure to Al can disrupt iron homeostasis resulting in iron excess. Excess iron from Al has been proven to promote the peroxidation of lipids, damage to DNA, and reactive oxygen species-induced apoptosis (Igbokwe et al., 2019).

Aluminum toxicity is believed to primarily affect the skeletal and central nervous system. Although it is known that Al causes neurotoxicity, the mechanism remains unclear. Al mostly accumulates in the cortex, hippocampus, and amygdala, which are also parts of the brain rich in glutamatergic neurons and transferrin receptors. When Al enters the brain, it displaces and regulates the metabolism of physiological cations such as Mg, Ca, and Fe. According to research (Gupta, 2012a), the amounts of tissue and cytoplasmic calcium can influence Al neurotoxicity. Al disrupts neurotransmitter release and changes neurotransmitter systems by substituting calcium in the synaptic region.

Acute and chronic toxicity: Acute Al poisoning is rare in animals. However, a high acute dose or repeated exposure over an extended period can result in severe toxicological effects. The toxicity depends on its chemical form, exposure route, and animal species (Table 1). Female rabbits were lethally affected by a single oral exposure to 540 mg/kg of Al lactate. Al has been found to be lethal to mice in subchronic and chronic investigations, but not to rats or dogs. Dermatitis, nasal discharges, loss of pigmentation on the nose pad, and aggressive and violent behavior are all signs of intoxication in dogs. The toxic effects depend on which organ is affected. These effects may be caused in part by the accumulation of Al and the substitution of calcium, magnesium, and iron. The main target organs are the myocardium, bones and CNS. Aluminum deposits can cause changes in the bone by interfering with heme synthesis and causing anemia, in the heart by causing myocardial infarction, and in the brain by causing neurotoxicity and memory loss. Al can also lead to problems with the liver and kidneys and osteoarthritis (Gupta, 2012a).

Table 1. Al toxicity in pregnancy, lactation and neonates (Gomez et al., 1991; Golub et al., 1992; Reinke et al., 2003; Gupta, 2012a).

Form	Species	Toute	Toxic effect
Al-lactate	Rabbit	Injection	Embryotoxicity and neurotoxicity
Al-chloride	Rat	Injection	Al plasma levels increased 30-fold ↑, Al milk/plasma ratio 6.6, growth retardation, Brain and nuclear fraction (brain cell nuclei) of rat fetus and cub ↑
Al-lactate	Mice	Oral	Growth retardation in cub, Impaired negative geotaxis and decreased forelimb or rear limb grip strength
Al-hydroxide	Rat	Oral	Organogenesis, skeletal abnormalities ↑

Animal studies have shown that oral administration of Al compounds causes neurotoxicity (Abu-Taweel et al., 2012; Dey & Singh, 2022). Al toxicity in vulnerable animals, such as rabbit and cat, is characterized by gradual neurological impairment leading to death from status epilepticus. Neurofibrillary tangles are the most prominent early pathologic change in large neurons, proximal axons, and dendrites of neurons in many brain regions. This is associated with synaptic loss and dendritic tree atrophy. There is evidence to show that following exposure to Al, more severe problems emerge in the brain. Not all species demonstrate this Al reaction. For example, rats do not develop neurofibrillary tangles or encephalopathy, and monkeys develop neurofibrillary tangles only after receiving an Al infusion for more than a year. Frequently observed are impairments in cognitive and motor function as well as behavioral abnormalities (Liu et al., 2008).

Maternal mice exposed to doses of 184-250 mg/ kg/ day Al lactate during pregnancy and lactation showed prominent indications of neurotoxicity, such as paralysis, ataxia, splaying and dragging of the hind limbs (Golub et al., 1987; 1992). In other studies, rats given 12 mg/ kg/ day of Al fluoride in drinking water and a base diet for 45-52 weeks observed higher Al levels and also histological changes in the brain (Varner et al., 1993; 1998). There is some evidence that prenatal exposure to neurotoxic chemicals results in delayed development of the nervous system and modest neurobehavioral dysfunction without physical deformity. Al crosses the placental barrier and accumulates in embryonic tissues, causing embryonic/ fetal toxicity, birth defects, developmental and neurobehavioral toxicity. It is significant to note that the creation of the extremely toxic gas phosphine (PH₃), rather than Al, is the primary cause of the acute toxicity linked to the consumption of Al phosphide. There have been cases when cows have perished after consuming grains that have been fumigated with Al phosphide. Chronic exposure to Al causes an increase in Al levels in bones, which can lead to bone abnormalities such as decreased bone formation and demineralization, or even osteoarthritis. Dogs and pigs exposed to Al show osteomalacia. Al can induce pulmonary fibrosis when inhaled chronically. In addition, prolonged exposure to Al can result in hepatic and renal failure as well as endocrine disruption (Gupta, 2012a). Additionally, it has been reported to influence the IL-6 levels in rats administered ammonium chloride (Gul et al., 2022).

Al is very toxic to fish when solubilized under acidic or alkaline circumstances, which helps explain fish population crashes linked with freshwater acidification. Waterborne Al poisoning targets the gill since internal organ accumulation is slow. Toxic mechanisms include cationic Al species (particularly Al³⁺) impairing gill ionoregulation and/ or respiratory dysfunction due to precipitation of Al(OH)₃ or polymerization of Al hydroxides on the gill surface during water alkalization. The latter produces gill inflammation, histopathologies, and profuse mucus at pH 5-6. These toxic pathways decrease cardiovascular and aerobic swimming performance, malnutrition, growth, spontaneous activity, and reproduction. Episodic exposure to severe [Al] and low pH may limit many fish species, while chronic low-level exposure can increase resistance. Even 2-day exposure to moderately increased Al in freshwater impairs seawater tolerance in migratory salmonids like salmon smolts (Wilson, 2011).

Placental toxicity: Al crosses the membrane of the placenta and accumulates in the tissues of the fetus at amounts that are detrimental to fetal development. Al crosses the blood-brain barrier, penetrates the placental passage, and reaches the maternal milk. According to studies conducted on mice and rabbits, placenta has 4-5 times more Al than embryonic or maternal tissues (Yokel and McNamara, 1985; Cranmer et al., 1986). Importantly, the

accumulation of Al in the placentas of mice and rabbits does not preclude its accumulation in fetal tissues (Gupta; 2012a, b). During gestation, mice exposed to Al lactate (83 mg/ kg/ day) observed an increase in cleft palate, dorsal hypokyphosis, and delayed parietal ossification (Paternain et al., 1988). Studies have shown that Al retards the skeletal development of pups. Major fetal abnormalities include digit, wavy rib, missing rib, absence of xiphoid, and poor ossification, especially in the cranial bones, the lower part of the spine, and the long bones of the limb (Paternain et al., 1988; Bernuzzi et al., 1989). High rates of skeletal defects and poor ossification in fetuses whose mothers were given Al chloride show that Al has a negative effect on bone formation in fetuses. This is because Al binds to phosphate, lowering the amount of phosphate that can be used to make bones. Due to a problem with how blood clots, a lack of phosphate can also cause abdominal bleeding in the fetus. Also, neurotoxicity and neurobehavioral changes have been found in the pup of rat, mice, and rabbits that were given Al at amounts that did not adversely affect the mothers. Al citrate and Al nitrate, two other types of Al, can also have the same effects on growth. Growing embryos are generally more sensitive to Al toxicity than adults (Gupta, 2012b).

Numerous animal investigations have demonstrated that Al can pass through the placenta and accumulate in fetal tissue, particularly the bones (Table 1). A majority of studies focus on the effects of prenatal exposure to Al on postnatal development and pup behavior. Common results involved reduced birth weight, a slower rate of weight gain during lactation, abnormal skeletal development, impairment of neurological functions, increase in stillbirth and perinatal mortality rates. Additionally, Al has been detected in the milk of mothers exposed to Al for an extended period of time (Reinke et al., 2003). During gestation, administration of subcutaneous Al lactate to rabbit decreases litter size. Even at lower dosages (2.7 mg/ kg), stillbirth and postnatal mortality rates in the pup were marginally increased. During the period of lactation, young animals gained less weight (Yokel, 1984; 1985).

The harmful effects of Al on young rats through Al transfer during lactation (Yumoto et al., 2001). Oral administration of Al salts via drinking water, food or gavage has been shown to cause embryo/fetal damage in rats and mice.

Diagnosis: Aluminum poisoning can be identified by looking at the history of exposure, the symptoms, and the amount of Al. It can be measured in tissue, blood, urine, feces, and hair with an atomic absorption spectrometer or an inductively coupled plasma spectrometer. The only measurement of urine can indicate whether a person has recently been exposed to excessive levels of Al. High concentrations in the lung are typically indicative of inhalation exposure, whereas elevated concentrations in the bone, liver, and spleen indicate sequestration.

When Al phosphide poisoning is suspected, liver and kidney tests for Al and stomach/rumen content test for phosphine are performed in the diagnostic setting. Aluminum concentrations in cattle and sheep 6-11 ppm (in the liver) and 4-5 ppm (in the kidney) are considered toxic. Aluminum levels of ≥ 1.2 ppm in the canine liver are regarded as elevated. Dietary Al levels exceeding 1 200 ppm are considered toxic to cattle and sheep. There is insufficient data to establish a correlation between Al exposure levels and blood or urine levels (Gupta, 2012a).

Treatment: For acute Al toxicity, there is no particular treatment present. So, the treatment contains symptomatic and supportive therapies (Gupta, 2012a). Prevention and treatment of Al toxicity may involve decreasing ingestion and intestinal absorption, increasing renal extraction and tissue accumulation, and administering antioxidants and chelating agents (Igbokwe et al., 2019). Given activated charcoal can be beneficial. For chronic exposure, chelation therapy with deferoxamine or 3-hydroxypyridine-4-ones is highly efficacious (Gupta, 2012a). Deferoxamine, a crystalline base chelating drug, is used in the treatment of Al intoxication. The primary use of deferoxamine is as an iron-chelating medication to treat iron overload. But because iron and Al share some chemical properties, it can also effectively remove too much Al from the body. Malic acid, selenium, melatonin, boric acid, and vitamin C can be used to treat Al toxicity. Plants and extracts of ginger, grape seed, wheat grass powder, black tea, and fenugreek seed may be used to ameliorate the toxicosis caused by Al exposure. Moreover, chenodeoxycholic acid reduced the neurotoxicity of Al by increasing insulin sensitivity (Igbokwe et al., 2019), and propolis prevented the genetic and hepatic damage caused by Al poisoning (Turkez et al., 2010). As a chelating agent and antioxidant, chlorogenic acid was advantageous against the toxicity of Al (Cheng et al., 2019).

Relationship with cancer: Recent studies suggest that Al may play a role in two disorders affecting the mammary gland (breast cancer and cyst) (Ogoshi et al., 1994; Darbre, 2016; Gorgogietas et al., 2018). Al levels in the breast tissues of breast cancer patients were higher than in blood serum. Cancer patients had higher Al levels in nipple aspirates than healthy controls and breast cyst liquid had higher Al levels than milk or serum (Darbre et al., 2011; 2013a, b; Darbre, 2016). Al levels in breast cancer patients' nipple aspirates were correlated with biomarkers of inflammation and oxidative stress in the breast (Darbre et al., 2013b). Carcinogenesis is a possible result of the buildup in breast tissue, which may affect the biological features of breast epithelial cells. (Pineau et al., 2014). According to current findings, Al can cause DNA damage in human breast epithelial cells, leading to cell growth. As a result of working as a metalloestrogen, Al may increase the risk of breast cancer. In the presence of Al, the migratory and invasive properties of estrogen-responsive MCF-7 human breast cancer

cells were improved. Long-term Al exposure boosted the motility and matrix metalloproteinase production of estrogen-unresponsive human breast cancer cells in culture (MDA-MB-231) (Darbre et al., 2013a, b; Bakir & Darbre, 2015; Darbre, 2016).

Relationship with vaccine: Some adjuvants, such as Al compounds, enhance the development of aggregates, which are easier to phagocytose. Vaccines containing different levels of Al salts are used in both humans and animals (Spickler & Routh, 2003). Several commercial vaccinations use Al components (Table 2).

Table 2. Some types of vaccines used in veterinary medicine (Lindblad, 2004; Jensen-Jarolim, 2015; Burakova et al., 2018).

Viral vaccines	Bacterial vaccines	Experimental antiparasitic vaccines
Avian infectious bronchitis virus	<i>Bacteriodes nosodus</i>	<i>Cooperia punctata</i>
Canine hepatitis virus	<i>Bordetella bronchispetica</i> <i>Cl. botulinum</i> , <i>Cl. chauvoei</i> , <i>Cl. chauvoei</i> , <i>Cl. perfringens</i> , <i>Cl. septicum</i> , <i>Cl. sordellii</i>	<i>Nematospiroides dubius</i>
Foot-and-mouth Disease		<i>Onchocerca lienalis</i>
Newcastle Disease Virus	<i>Leptospira interrogans</i>	<i>Trichinella spiralis</i>
Bovine herpes virus 1 (IBRV)	<i>Pasteurella multocida</i>	
Parainfluenza virus type 3 (PI3V)	<i>Haemophilus somnus</i>	

Al salt causes high-titer IgG antibodies with long-term the immune system, ease of formulation, and safety. Early tests with potassium Al showed that the depot effect of the adjuvant increased the immune response in rabbit. Many therapeutic trials have used Al compounds with other adjuvants to boost Th1 cell-mediated responses and improve their efficiency against viral infections (Burakova et al., 2018). Al adjuvants increase the T helper 2 (Th2) immunological response by secreting IL-4. This produces IgG, IgE, and eosinophil, making these adjuvants ideal candidates for antibacterial and antiparasitic vaccines.

Vaccines containing Al may cause significant granulomas in sheep. Granulomas are frequently linked to storage adjuvants, and their resolution can take weeks or months. At the end of the 1980s, there was a worrying increase in the incidence of vaccine-associated sarcomas in cats. Currently, available data places the incidence of these sarcomas between 1 and 10 per 10,000 vaccinated cats. These vaccine-associated sarcomas form at the site of immunization, contain residual Al adjuvant, and have inflammatory features. They have been associated with rabies, feline leukemia, and additional vaccines. Al adjuvants can cause inflammation and cats should avoid them. Nevertheless, this recommendation is contentious.

Relationship with antacids: Aluminum- containing antacids include Al salts; Al hydroxide, Al magnesium silicate, Al phosphate, and Al chloride. Al-based mineral antacids

have the effect of increasing the pH of the stomach. But the salts can cause constipation. So, it's common practice to combine these active ingredients. Patients with kidney disease can use Al hydroxide to stop their bodies from absorbing as much phosphate because Al creates phosphate complexes in the intestine (Boothe, 2001; Segev et al., 2008; Papich, 2018).

Relationship with nanomedicine: Aluminum-oxide nanoparticles (Al-NPs) are among the most important nano-metals, with extensive applications in a variety of disciplines, including veterinary, medicine, food, agriculture, industry, engineering, and others. The using of Al-NPs results in their enormous release into the environment, which may have negative effects on animal and human health. The extensive application of Al-NPs in a variety of applications has adverse effects on animal and human health (Elkhadrawey et al., 2021). It has been reported that Al-NPs were rapidly absorbed and systemically distributed to many organs (kidney and liver) (Krause et al., 2020). It accumulated most in the kidneys, blood, liver, and brain. This showed that size is a barrier to the absorption of Al-oxide in rats (Balasubramanyam et al., 2009). Al-NPs may induce liver damage, kidney damage, neurological damage, oxidative stress, DNA damage, an inflammatory response, and apoptotic effects upon cellular accumulation. Some toxic effects are seen in Table 3 (Elkhadrawey et al., 2021).

Table 3. Studies on the toxic effects of Al nanoparticles.

Toxic effect	Species	Route	Effects
Hepatotoxicity	Rat	Injection	TP↓, TL↓, ALT↑ and AST↑ in serum, hepatic histopathological alterations
Hepatotoxicity	Rat	Oral	increase ALP, AST, ALT, LDH, GGT and bilirubin in plasma, histopathological changes
Hepatotoxicity	Mice	Oral	increase ALT and AST activities in serum, hepatic histopathological changes
Nephrotoxicity	Rat	Injection	increase urea and creatinine in serum, renal histopathological changes
Nephrotoxicity	Rat	Oral	increase urea, BUN and creatinine in plasma, renal histopathological changes; increase aggregation
Neurotoxicity	Mice	Injection	ROS↑, brain energy homeostasis disruption, ippocampus-dependent memory impairment, neuropathology induction
Neurotoxicity	Rat	Injection	Al accumulation, oxidative stress↑, hippocampus of acetylcholinesterase ↓
Neurotoxicity	Mice	Nasal drip	impaired spatial learning and memory, oxidative stress, pathological changes in the ultra-structure of mitochondria, mitochondrial dysfunction
Oxidative damage	Fish	Oral	Liver SOD↓, CAT↓, and GST↑
Oxidative damage	Mice	Oral	LPO↑ and GSH↓ in brain, liver, kidney and spleen
Genotoxicity	Mice	Oral	DNA damage↑ in brain, spleen, testis, liver, and kidney
Genotoxicity	Rat	Oral	DNA damage in testicular cells↑
Apoptotic effect	Rat	Oral	p53 level↑, PGC1α↓ and mTFA↓ in liver; Leyding cells caspase-3↑
Inflammatory	Mice	Nasal drip	TNF-α↑, IL-1β↑, and IL-6↑ in serum, spleen and thymus
Inflammatory	Rat	Oral	IFN-γ↑, TNF-α↑, IL-1β↑ and IL-6↑ in hippocampus

AST; Aspartate aminotransferase, ALT; Alanine aminotransferase, ALP; Alkaline phosphatase, GGT; Gamma glutamyltransferase, LDH; Lactate Dehydrogenase, BUN; Blood urea nitrogen, ROS; Reactive oxygen species, SOD; Superoxide Dismutase, CAT; Catalase, GST; Glutathione-S-Transferase, LPO; Lipid peroxidation, GSH; Glutathione, TNF-α; Tumor Necrosis Factor Alpha, IL; Interleukin, IFN; Interferon

Conclusion

There is no exact treatment for Al toxicity. In case of toxicity or overdose of Al, the effect of the cellular mechanism will be revealed by further studies. Perhaps it will be beneficial to develop and put into use new therapeutic agents and phytotherapeutic products to treat poisoning.

Financial Support

This research received no grant from any funding agency/sector.

Ethical Statement

This study does not present any ethical concerns.

Conflict of Interest

The authors declared that there is no conflict of interest.

References

- Abu-Taweel, G.M., Ajarem, J.S., & Ahmad, M. (2012). Neurobehavioral toxic effects of perinatal oral exposure to aluminum on the developmental motor reflexes, learning, memory and brain neurotransmitters of mice offspring. *Pharmacology Biochemistry and Behavior*, *101*(1), 49-56. <https://doi:10.1016/j.pbb.2011.11.003>
- Bakir, A., & Darbre, P.D. (2015). Effect of aluminium on migration of oestrogen unresponsive MDA-MB-231 human breast cancer cells in culture. *Journal of Inorganic Biochemistry*, *152*, 180-185. <https://doi:10.1016/j.jinorgbio.2015.09.001>
- Balasubramanyam, A., Sailaja, N., Mahboob, M., Rahman, M.F., Hussain, S.M., & Grover, P. (2009). In vivo genotoxicity assessment of aluminium oxide nanomaterials in rat peripheral blood cells using the comet assay and micronucleus test. *Mutagenesis*, *24*(3), 245-251. <https://doi:10.1093/mutage/geb003>
- Bernuzzi, V., Desor, D., & Lehr, P.R. (1989). Developmental alternations in offspring of female rats orally intoxicated by aluminum chloride or lactate during gestation. *Teratology*, *40*(1), 21-27. <https://doi:10.1002/tera.1420400104>
- Bjerregaard, P., Christian, B.I., & Andersen, O.A. (2015). Ecotoxicology of metals-sources, transport, and effects on the ecosystem. In: G.F. Nordberg, & M. Nordberg (Ed.), *Handbook on the toxicology of metals* (4th ed., pp. 425-459), Academic Press.
- Boothe, D.M. (2001). The analgesic, antipyretic, anti-inflammatory drugs. In: R. Adams. (Ed.), *Veterinary pharmacology and therapeutics* (8th ed., pp. 433-451). Iowa State University Press.
- Burakova, Y., Madera, R., McVey, S., Schlup, J. R., & Shi, J. (2018). Adjuvants for animal vaccines. *Viral Immunology*, *31*(1), 11-22. <https://doi:10.1089/vim.2017.0049>
- Cheng, D., Zhang, X., Tang, J., Kong, Y., Wang, X., & Wang, S. (2019). Chlorogenic acid protects against aluminum toxicity via MAPK/Akt signaling pathway in murine RAW264.7 macrophages. *Journal of Inorganic Biochemistry*, *190*, 113-120. <https://doi:10.1016/j.jinorgbio.2018.11.001>
- Cranmer, J.M., Wilkins, J.D., & Cannon, D.J. (1986). Fetal-placentalmaternal uptake of aluminum in mice following gestational exposure: effect of dose and route of administration. *Neurotoxicology*, *7*, 601-608.
- Darbre, P.D. (2016). Aluminium and the human breast. *Morphologie*, *100*, 65-74. <https://doi:10.1016/j.morpho.2016.02.001>
- Darbre, P.D., Bakir, A., & Iskakova, E. (2013a). Effect of aluminium on migratory and invasive properties of MCF-7 human breast cancer cells in culture. *Journal of Inorganic Biochemistry*, *128*, 245-249. <https://doi:10.1016/j.jinorgbio.2013.07.004>

- Darbre, P.D., Mannello, F., & Exley, C. (2013b). Aluminium and breast cancer: sources of exposure, tissue measurements and mechanisms of toxicological actions of breast of breast biology. *Journal of Inorganic Biochemistry*, 128, 257-261. [https://doi: 10.1016/j.jinorgbio.2013.07.005](https://doi:10.1016/j.jinorgbio.2013.07.005)
- Darbre, P.D., Pugazhendhi, D., & Mannello, F. (2011). Aluminium and human breast diseases. *Journal of Inorganic Biochemistry*, 105(11), 1484-1488. [https://doi: 10.1016/j.jinorgbio.2011.07.017](https://doi:10.1016/j.jinorgbio.2011.07.017)
- Dey, M. & Singh, R.K. (2022). Chronic oral exposure of aluminum chloride in rat modulates molecular and functional neurotoxic markers relevant to Alzheimer's disease. *Toxicology Mechanisms and Methods*, 32(8), 616-627. <https://doi:10.1080/15376516.2022.2058898>
- Elkhadrawey, B, El-Bialy, B., Shimaa, A.Z., Nermeen, E.B., & Hesham, E. (2021). Potential toxic effects of aluminum nanoparticles: An overview. *Journal of Current Veterinary Research*, 3(2), 94-106. [https://doi: 10.21608/JCVR.2021.199440](https://doi:10.21608/JCVR.2021.199440)
- Frank, A.A., Hedstrom, O.R., Braselton, W.E., Huckfeldt, R.E., & Snyder, S.P. (1992). Multifocal polioencephalomyelomalacia in Simmental calves with elevated tissue aluminum and decreased tissue copper and manganese. *Journal of Veterinary Diagnostic Investigation*, 4, 353-355. <https://doi:10.1177/104063879200400326>
- Golub, M.S., Gershwin, M.E., & Donald, J.M. (1987). Maternal and developmental toxicity of chronic aluminum exposure in mice. *Fundamental and Applied Toxicology*, 8, 346-357. [https://doi:10.1016/0272-0590\(87\)90084-4](https://doi:10.1016/0272-0590(87)90084-4)
- Golub, M.S., Keen, C.L., & Gershwin, M.E. (1992). Neurodevelopmental effect of aluminum in mice: fostering studies. *Neurotoxicology and Teratology*, 14(3), 177-182. [https://doi:10.1016/0892-0362\(92\)90013-z](https://doi:10.1016/0892-0362(92)90013-z)
- Gomez, M., Domingo, J.L., & Llobet, J.M. (1991). Developmental toxicity evaluation of oral aluminum in rats: influence of citrate. *Neurotoxicology and Teratology*, 13(3), 323-328. [https://doi:10.1016/0892-0362\(91\)90078-b](https://doi:10.1016/0892-0362(91)90078-b)
- Gorgogietas, V.A., Tsialtas, I., Sotiriou, N., Laschou, V.C., Karra, A.G., Leonidas, D.D., Chrousos, G.P., Protopapa, E., & Psarra, A.G. (2018). Potential interference of aluminum chlorohydrate with estrogen receptor signaling in breast cancer cells. *Journal of Molecular Biochemistry*, 7(1), 1-13.
- Gul, B., Yerebasan, U., Korkak, F.A., Yuce, H., Baykalir, Y., Parlak Ak, T., Gul, H.F. (2022). The effect of aloe vera on interleukin-6 levels in rats given aluminium chloride. International Asian Congress On Contemporary Sciences-VII. December 9-11, 414, Olongapo City, Philippines.
- Gupta, N., Gaurav, S.S., & Kumar, A. (2013). Molecular basis of aluminium toxicity in plants: a review. *American Journal of Plant Sciences*, 4(12), 21-37. [https://doi: 10.4236/ajps.2013.412A3004](https://doi:10.4236/ajps.2013.412A3004)
- Gupta, R. C. (2012a). Aluminum. In: R. C. Gupta. (Ed.), *Veterinary Toxicology Basic and Clinical Principle* (2nd ed., pp. 493-498). Academic Press.
- Gupta, R.C. (2012b). Placental toxicity. In: R.C. Gupta. (Ed.), *Veterinary Toxicology Basic and Clinical Principle* (2nd ed., pp. 319-336). Academic Press.
- Herndon, J.M. (2015). Aluminum poisoning of humanity and Earth's biota by clandestine geoengineering activity: implications for India. *Current Science*, 108(12), 2173-2177.
- Igbokwe, I.O., Igwenagu, E., & Igbokwe, N.A. (2019). Aluminium toxicosis: a review of toxic actions and effects. *Interdisciplinary Toxicology*, 12(2), 45-70. <https://doi:10.2478/intox-2019-0007>
- Jaishankar, M., Tseten, T., Anbalagan, N., Mathew, B.B., & Beeregowda, K.N. (2014). Toxicity, mechanism and health effects of some heavy metals. *Interdisciplinary Toxicology*, 7(2), 60-72. <https://doi:10.2478/intox-2014-0009>
- Jensen-Jarolim, E. (2015). Aluminium in allergies and allergen immunotherapy. *World Allergy Organization Journal*, 8(1), 1-7. <https://doi:10.1186/s40413-015-0060-5>
- Krause, B.C., Kriegel, F.L., Rosenkranz, D., Dreijack, N., Tentschert, J., Jungnickel, H., Jalili, P., Fessard, V., Laux, P., & Luch, A. (2020). Aluminum and aluminum oxide nanomaterials uptake after oral exposure-a comparative study. *Scientific Reports*, 10(1), 1-10. [https://doi: 10.1038/s41598-020-59710-z](https://doi:10.1038/s41598-020-59710-z)
- Lindblad, E.B. (2004) Aluminium compounds for use in vaccines. *Immunology Cell Biology*, 82(5), 497-505. <https://doi:10.1111/j.0818-9641.2004.01286.x>
- Liu, J, Robert, A., & Waalkes, M.P. (2008). Toxic effect of metal. In: C.D. Klaassen. (Ed.), *Casarett and Doull's toxicology the basic science of poisons* (8th ed., pp. 931-980). McGraw-Hill.
- Ogoshi, K., Yanagi, S., Moriyama, T., & Arachi, H. (1994). Accumulation of aluminum in cancers of the liver, stomach, duodenum and mammary glands of rats. *Journal of trace elements and electrolytes in health and disease*, 8(1), 27-31.
- Papich, G.P. (2018). Drugs for Treating Gastrointestinal Diseases. In: J.E. Riviere & M.G. Papich (Ed.), *Veterinary Pharmacology and Therapeutics* (10th ed., pp.1245-1277). Wiley.
- Patermain, J.L., Domingo, J.L., & Llobet, J.M. (1988). Embryotoxic and teratogenic effects of aluminum nitrate in rats upon oral administration. *Teratology*, 38, 253-257. <https://doi:10.1002/tera.1420380309>

- Pineau, A., Fauconneau, B., Sappino, A.P., Deloncle, R., & Guillard, O. (2014). If exposure to aluminium in antiperspirants presents health risk, its content should be reduced. *Journal of Trace Elements in Medicine and Biology*, 28(2), 147-150. [https://doi: 10.1016/j.jtemb.2013.12.002](https://doi:10.1016/j.jtemb.2013.12.002)
- Reinke, C.M., Breikreutz, J., & Leuenberger, H. (2003). Aluminum in over the-counter drugs: risks outweigh benefits. *Drug Safety*, 26, 1011-1025. <https://doi:10.2165/00002018-200326140-00003>
- Segev, G., Bandt, C., Francey, T., & Cowgill, L.D. (2008). Aluminum toxicity following administration of aluminum-based phosphate binders in 2 dogs with renal failure. *Journal of Veterinary Internal Medicine*, 22, 1432-1435. <https://doi:10.1111/j.1939-1676.2008.0206.x>
- Soni, M.G., White, S.M., Flamm, W.G., & Burdock, G.A. (2001). Safety evaluation of dietary aluminum. *Regulatory Toxicology and Pharmacology*, 33(1), 66-79. <https://doi:10.1006/rtph.2000.1441>
- Spickler, A.R., & Roth, J.A. (2003). Adjuvants in veterinary vaccines: modes of action and adverse effects. *Journal of Veterinary Internal Medicine*, 17(3), 273-281. <https://doi:10.1111/j.1939-1676.2003.tb02448.x>. PMID: 12774966
- Turkez, H., Yousef, M.I., & Geyikoglu, F. (2010). Propolis prevents aluminium-induced genetic and hepatic damages in rat liver. *Food and Chemical Toxicology*, 48(10), 2741-2746. [https://doi: 10.1016/j.fct.2010.06.049](https://doi:10.1016/j.fct.2010.06.049).
- Varner, J.A., Huie, C., & Horvath, W. (1993). Chronic AlF₃ administration. II. Selected histological observations. *Neuroscience Research Communications*, 13, 99-104.
- Varner, J.A., Jensen, K.F., & Horvath, W. (1998). Chronic administration of aluminum fluoride or sodium fluoride to rats in drinking water: alterations in neuronal and cerebrovascular integrity. *Brain Research*, 784, 284-298. [https://doi: 10.1016/s0006-8993\(97\)01336-x](https://doi:10.1016/s0006-8993(97)01336-x)
- Wilson, R.W. (2011). Aluminum. In: C.M. Wood, A.P. Farrell, & C.J. Brauner (Ed.), *Fish Physiology* (1 st ed., pp. 67-123). Academic Press.
- Yokel, R.A. (1984). Toxicity of aluminum exposure during lactation to the maternal and suckling rabbit. *Toxicology and Applied Pharmacology*, 75(1), 35-43. [https://doi:10.1016/0041-008x\(84\)90073-5](https://doi:10.1016/0041-008x(84)90073-5)
- Yokel, R.A. (1985). Toxicity of gestational aluminum exposure to the maternal rabbit and offspring. *Toxicology and Applied Pharmacology*, 79(1), 121-133. [https://doi:10.1016/0041-008x\(85\)90374-6](https://doi:10.1016/0041-008x(85)90374-6). PMID: 404939
- Yumoto, S., Nagai, H., Matsuzaki, H., Matsumura, H., Tada, W., Nagatsuma, E., & Kobayashi, K. (2001). Aluminium incorporation into the brain of rat fetuses and sucklings. *Brain Research Bulletin*, 55(2), 229-234. [https://doi:10.1016/s0361-9230\(01\)00509-3](https://doi:10.1016/s0361-9230(01)00509-3)