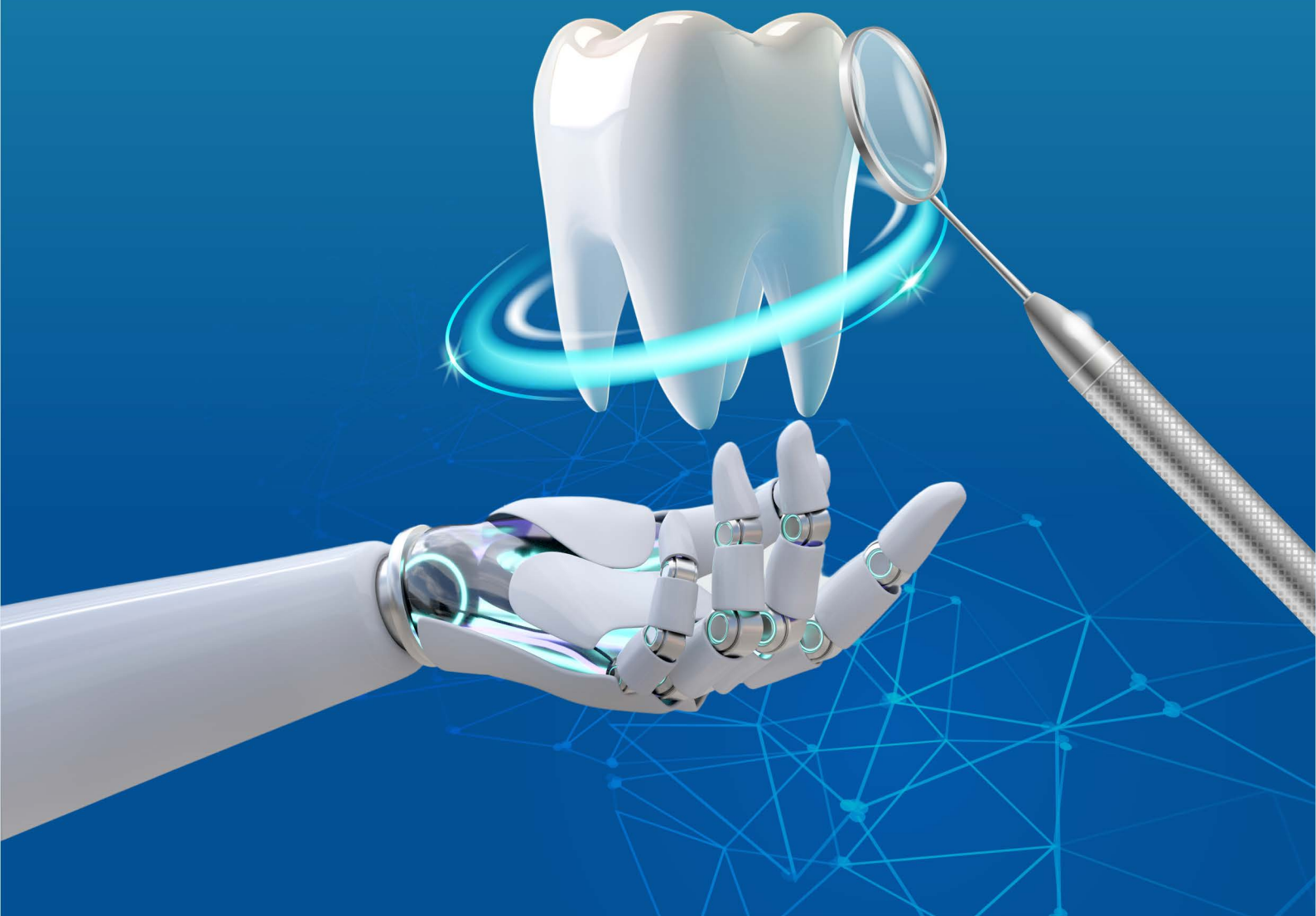


# NECMETTIN ERBAKAN UNIVERSITY DENTAL JOURNAL

Special Issue - Year:2024



# Necmettin Erbakan University Dental Journal

**Volume: 6, Current Approaches in Dentistry Special Issue (October 2024)**

International Peer Reviewed Journal

**Owner**

Necmettin Erbakan University

**Editor-in-Chief**

Assoc. Prof. Makbule Bilge Akbulut

**Publication Type**

National Periodical

**Publication Period**

Published third-annual

**Published Date**

October 2024

**Correspondence Address**

NEU PRESS Yaka Mah. Yeni Meram Cad. Kasım Halife Sok. No: 11 B Blok Zemin Kat

Posta Kodu: 42090 Meram / KONYA

**Phone:** +90 332 221 0 575

**Web:** [dergipark.org.tr/en/pub/neudhfdergisi](http://dergipark.org.tr/en/pub/neudhfdergisi)

**E-mail:** [neudentj@erbakan.edu.tr](mailto:neudentj@erbakan.edu.tr)

Necmettin Erbakan University Dental Journal - NEUDentJ - is an international peer reviewed third-annual journal

**E- ISSN:** 2687-5535

**DergiPark**  
AKADEMİK

## OWNER

Necmettin Erbakan University

## BOARD of EDITORS

### Editor

**Assoc. Prof. Makbule Bilge Akbulut**

Necmettin Erbakan University, Faculty of Dentistry, Department of Endodontics, Konya, Türkiye

### Associate Editors

**Assoc. Prof. Emine Begüm Büyükerkmen**

Necmettin Erbakan University, Faculty of Dentistry, Department of Prosthodontics, Konya, Türkiye

### Proofreading

**Oğuzhan Karayel**

Necmettin Erbakan University, Faculty of Dentistry, Konya, Türkiye

### Editor Assistants

**Sinem Alkurt**

Necmettin Erbakan University, Faculty of Dentistry, Konya, Türkiye

**Lala Jabbarova**

Necmettin Erbakan University, Faculty of Dentistry, Konya, Türkiye

**Ayşenur Kılıçoğlu**

Necmettin Erbakan University, Faculty of Dentistry, Konya, Türkiye

**Burcu Kızılırmak**

Necmettin Erbakan University, Faculty of Dentistry, Konya, Türkiye

**Fatma Doğan**

Necmettin Erbakan University, Faculty of Dentistry, Konya, Türkiye

**Fatma Beyza Deniz**

Necmettin Erbakan University, Faculty of Dentistry, Konya, Türkiye

**Hüseyin Biçer**

Necmettin Erbakan University, Faculty of Dentistry, Konya, Türkiye

**Ömer Öğütçen**

Necmettin Erbakan University, Faculty of Dentistry, Konya, Türkiye

**Sultan Uzun**

Necmettin Erbakan University, Faculty of Dentistry, Konya, Türkiye

**İrem Uysal**

Necmettin Erbakan University, Faculty of Dentistry, Konya, Türkiye

**Ayşenur Çetin**

Necmettin Erbakan University, Faculty of Dentistry, Konya, Türkiye

### Publishing Editor

**Mustafa Altıntepe**

Necmettin Erbakan University, Faculty of Dentistry, Konya, Türkiye

**Oğuzhan Karayel**

Necmettin Erbakan University, Faculty of Dentistry, Konya, Türkiye

**İrem Uysal**

Necmettin Erbakan University, Faculty of Dentistry, Konya, Türkiye

## EDITORIAL BOARD

### Oral and Maxillofacial Surgery

**Prof. Dr. Bozkurt Kubilay Işık**

Necmettin Erbakan University, Faculty of Dentistry

**Prof. Dr. Doğan Dolanmaz**

Bezmialem Vakıf University, Faculty of Dentistry

### Oral and Maxillofacial Radiology

**Assoc. Prof. Melek Taşşöker**

Necmettin Erbakan University, Faculty of Dentistry

**Prof. Dr. Kaan Orhan**

Ankara University, Faculty of Dentistry

### Restorative Dentistry

**Asst. Prof. Zeynep Dereli**

Necmettin Erbakan University, Faculty of Dentistry

**Prof. Dr. Nimet Ünlü**

Selçuk University, Faculty of Dentistry

### Endodontics

**Assoc. Prof. M. Bilge Akbulut**

Necmettin Erbakan University, Faculty of Dentistry

**Prof. Dr. Sema Belli**

Selçuk University, Faculty of Dentistry

### Orthodontics

**Asst. Prof. Ahmet Ertan Soğancı**

Necmettin Erbakan University, Faculty of Dentistry

**Prof. Dr. Ahmet Yağcı**

Erciyes University, Faculty of Dentistry

### Pedodontics

**Asst. Prof. Hazal Özer**

Necmettin Erbakan University, Faculty of Dentistry

**Assoc. Prof. Ebru Küçükylmaz**

İzmir Kâtip Çelebi University, Faculty of Dentistry

### Periodontology

**Assoc. Prof. Fatma Uçan Yarkaç**

Necmettin Erbakan University, Faculty of Dentistry

**Prof. Dr. Mustafa Tunalı**

Çanakkale Onsekiz Mart University, Faculty of Dentistry

### Prosthodontics

**Prof. Dr. Ali Rıza Tunçdemir**

Necmettin Erbakan University, Faculty of Dentistry

**Prof. Dr. Filiz Aykent**

Ankara Yıldırım Beyazıt University, Faculty of Dentistry

---

## INTERNATIONAL ADVISORY BOARD

**Prof. Dr. Mutlu Özcan**

University of Zurich, Center of Dental Medicine, Clinic of Reconstructive Dentistry, Zurich, Switzerland

**Dr. Ahmed Al-Dam**

Universitätsklinikum Hamburg-Eppendorf: Hamburg, Hamburg, DE

**Prof. Kim Kyung-A**

Kyung Hee University, Department of Orthodontics, Seoul, South Korea

**Dr. Milos Lazarevic**

University of Belgrade, School of Dental Medicine, Republic of Serbia

**Dr. Heeresh Shetty**

Nair Hospital Dental College, Mumbai, India

**Dr. Morena Petrini**

University of Chieti, Department of Medical Oral and Biotechnological Sciences, Chieti, Italy

**Dr. Yvoni Kirmanidou**

Aristotle University of Thessaloniki, Division of Fixed Prosthodontics and Implant Prosthodontics, Thessaloniki, Greece.

---

## ADVISORY BOARD

**Prof. Dr. Melek Akman**

Necmettin Erbakan University, Faculty of Dentistry

**Prof. Dr. Alparslan Esen**

Necmettin Erbakan University, Faculty of Dentistry

**Assoc. Prof. Elif Öncü**

Necmettin Erbakan University, Faculty of Dentistry

**Assoc. Prof. Emre Korkut**

Necmettin Erbakan University, Faculty of Dentistry

**Assoc. Prof. Arslan Terlemez**

Necmettin Erbakan University, Faculty of Dentistry

**Assoc. Prof. Makbule Tuğba Tunçdemir**

Necmettin Erbakan University, Faculty of Dentistry

**Assoc. Prof. Dilek Menziletoğlu**

Necmettin Erbakan University, Faculty of Dentistry

**Assoc. Prof. Aybüke Öcal Erdur**

Necmettin Erbakan University, Faculty of Dentistry

**Assoc. Prof. Durmuş Alperen Bozkurt**

Necmettin Erbakan University, Faculty of Dentistry

**Asst. Prof. Emine Begüm Büyükerkmen**

Necmettin Erbakan University, Faculty of Dentistry

**Assoc. Prof. Ceyda Akın**

Necmettin Erbakan University, Faculty of Dentistry

**Assoc. Prof. Mehmet Esad Güven**

Necmettin Erbakan University, Faculty of Dentistry

**Assoc. Prof. Merve Abaklı İnci**

Necmettin Erbakan University, Faculty of Dentistry

**Asst. Prof. Ali Altındağ**

Necmettin Erbakan University, Faculty of Dentistry

**Asst. Prof. Şeref Nur Mutlu**

Necmettin Erbakan University, Faculty of Dentistry

# CONTENTS

Research Article	
1	<b><i>Evaluation of Color and Translucency Changes of PEEK Material Veneered with Single-Shade Composite Resins</i></b> <i>Işıl KARAOKUTAN, İlayda AYVAZ,</i>
9	<b><i>Retrospective Radiographic Evaluation of Implant Complications: CBCT-Based Study</i></b> <i>Didem DUMANLI, Çiğdem ŞEKER2, Gediz GEDUK</i>
18	<b><i>The Effects of Different Restoration Materials on the Trueness of Intraoral Scanners</i></b> <i>Mehmet GÖZEN, Neslihan GÜNTEKİN, Ceyda AKIN</i>
27	<b><i>Assessment of the Radiopacity of Different Fissure Sealants Compared to Dental Hard Tissues</i></b> <i>Peris CELIKEL, Aybike BAS, Fatih SENGUL, Sera DERELIOGLU SIMSEK</i>
36	<b><i>Effects of Operator Experience and Scanning Distance on Intraoral Scanner Accuracy</i></b> <i>Taygun SEZER, Aybüke BAHADIR SEZER</i>
45	<b><i>The Effect of Patient-Specific Variables on the Need for Dental Treatment Under General Anesthesia in Children: A Retrospective Study</i></b> <i>Büşra MUSLU DİNÇ, Funda ARUN</i>
51	<b><i>Investigation of Fracture Strength and SEM Images of Different CAD-CAM Materials Applied to Two Different Inlay Cavities</i></b> <i>Rahime Zeynep ERDEM, Kevser KARAKAYA</i>
60	<b><i>Marginal Bone Loss and Clinical Evaluation of Angled Implants: A Retrospective Study</i></b> <i>Beyza ÖZTAŞ, Doğan İlğaz KAYA</i>
70	<b><i>Evaluation of Shear Bond Strength of Universal Adhesives to Dentin: in Vitro Study</i></b> <i>Irem Kubra CAL, Fatma OZTURK, Numan AYDIN, Serpil KARAOĞLANOĞLU</i>
79	<b><i>Effect of Energy Drinks on Surface Roughness and Weight Loss of Custom-Made Mouthguard Material</i></b> <i>Tuba ŞENOCAK, Alper ÖZDOĞAN, Tuğçe KAVAZ</i>
88	<b><i>Evaluation of the Effect of Background Color on the Color Change of Composite Resins of Different Translucencies</i></b> <i>İrem KAYA, Ahmet EROL, Nevin ÇOBANOĞLU</i>
97	<b><i>Comparison of Microleakage of Monolithic Zirconia after Surface Treatment and Thermal Cycles Using Data Analysis Software</i></b> <i>Emel ARSLAN, Halil Nuri ÖZDEMİR, Hatice SEVMEZ</i>
Case Report	
108	<b><i>A Contemporary Approach: Presentation of 4 Cases with the Entire Papilla Preservation (EPP) Technique</i></b> <i>Şükran ACIPINAR, Taha Yasin ERDOĞAN</i>
116	<b><i>Total Pulpotomy with MTA in Young Permanent Teeth: Case Series</i></b> <i>Menekşe ALİM, Mehmet BANİ</i>

## Evaluation of Color and Translucency Changes of PEEK Material Veneered with Single-Shade Composite Resins

Işıl KARAOKUTAN<sup>1\*</sup> İlayda AYVAZ<sup>2</sup>

<sup>1</sup> Assoc. Prof., Pamukkale University, Faculty of Dentistry, Department of Prosthodontics, Denizli, Türkiye, [dt.isilsentoregil@gmail.com](mailto:dt.isilsentoregil@gmail.com)

<sup>2</sup> Res. Ass., Pamukkale University, Faculty of Dentistry, Department of Prosthodontics, Denizli, Türkiye, [ilaydaayvaz147@gmail.com](mailto:ilaydaayvaz147@gmail.com)

### Article Info

#### Article History

Received: 21.06.2024

Accepted: 02.09.2024

Published: 15.10.2024

#### Keywords:

Polyetheretherketone,  
Color stability,  
Single-shade composite resin,  
Translucency,  
Artificial aging.

### ABSTRACT

**Aim:** The aim of this study was to evaluate the color and translucency changes of single-shade composites used in veneering polyetheretherketone (PEEK) material after aging.

**Materials and Methods:** 3 single-shade composites with different chemical structures and 1 conventional composite resin were applied on the PEEK material with a thickness of 2 mm (N=40, n=10). L, a, and b color coordinates of each specimen were measured three times with a spectrophotometer on a black, gray, and white background from the center of the specimen, and the average of these measurements was recorded. The specimens were subjected to 5000 cycles of thermal aging at 5-55°C. After aging, color measurements were repeated. Color changes ( $\Delta E_{00}$ ) and translucency parameters ( $\Delta TP_{00}$ ) of composite resin specimens were determined before and after aging using CIEDE 2000 color formulas. The data obtained were analyzed by one-way analysis of variance and Tukey HSD test ( $p < 0.05$ ).

**Results:** As a result of the study, the color change of all composite resin materials was found to be below the clinically acceptable limit ( $\Delta E = 1.8$ ). The lowest color change was observed in the traditional composite group, and a statistically significant difference was found between the other groups ( $p < 0.05$ ). The translucency change of single-shade composite materials was found to be statistically lower than that of conventional composite resin ( $p < 0.05$ ).

**Conclusion:** This study's results show that single-shade composite resins can be used as an optical alternative to traditional composites in direct veneering of the PEEK material.

## Tek-Renkli Kompozit Rezinlerle Veneerlenmiş PEEK Materyalinin Renk ve Translansensi Değişimlerinin Değerlendirilmesi

### Makale Bilgisi

#### Makale Geçmişi

Geliş Tarihi: 21.06.2024

Kabul Tarihi: 02.09.2024

Yayın Tarihi: 15.10.2024

#### Anahtar Kelimeler:

Polietereterketon,  
Renk stabilitesi,  
Tek renk kompozit rezin,  
Translansensi,  
Yapay yaşlandırma.

### ÖZET

**Amaç:** Bu çalışmanın amacı polieteterketon (PEEK) materyalinin veneerlenmesinde kullanılan tek renkli kompozitlerin yaşlandırma sonrası renk ve translansensi değişimlerinin değerlendirilmesidir.

**Gereç ve Yöntemler:** 3 adet farklı kimyasal yapıya sahip tek renkli kompozit ve 1 adet geleneksel kompozit rezin PEEK materyali üzerine 2 mm kalınlığında uygulandı (N=40, n=10). Her örneğin L, a, b renk değerlerinin ölçümü örneğin merkezinden olacak şekilde siyah, gri ve beyaz fon üzerinde spektrofotometre ile 3 kere yapıldı ve bu ölçümlerin ortalaması kaydedildi. Örnekler 5-55°C'de 5000 devir termal yaşlandırmaya tabii tutuldu. Yaşlandırma sonrası renk ölçümleri aynı şekilde tekrarlandı. Kompozit rezin örneklerin renk değişimleri ( $\Delta E_{00}$ ) ve translansensi parametresi ( $\Delta TP_{00}$ ) yaşlandırma öncesi ve sonrasında CIEDE 2000 renk formülleri kullanılarak belirlendi. Elde edilen veriler tek yönlü varyans analizi ve Tukey HSD testi ile istatistiksel analize tabii tutuldu ( $p < 0,05$ ).

**Bulgular:** Çalışmanın sonucunda tüm kompozit rezin materyallerinin renk değişimi klinik olarak kabul edilebilir sınırdan ( $\Delta E=1,8$ ) altında bulundu. En az renk değişimi geleneksel kompozit grubunda gözlemlendi ve diğer gruplar ile arasında istatistiksel olarak anlamlı fark bulundu ( $p < 0,05$ ). Tek renkli kompozit materyallerinin translansensi değişimi geleneksel kompozit rezinden istatistiksel olarak daha düşük bulundu ( $p < 0,05$ ).

**Sonuç:** Bu çalışmanın sonuçları PEEK materyaline uygulanan direkt veneerleme işlemlerinde, tek renkli kompozit rezinlerin geleneksel kompozitlere optik açıdan bir alternatif olarak kullanılabilceğini göstermektedir.

**To cite this article:** Karaokutan I, Ayvaz İ. Evaluation of Color and Translucency Changes of PEEK Material Veneered with Single-Shade Composite Resins. NEU Dent J. 2024;6(Special Issue):1-8. <https://doi.org/10.51122/neudentj.2024.109>

\*Corresponding Author: Işıl KARAOKUTAN, [dt.isilsentoregil@gmail.com](mailto:dt.isilsentoregil@gmail.com)



## INTRODUCTION

In order to ensure successful restorations, it is imperative for the materials used to possess favorable physical and chemical properties, as well as to closely replicate the color and translucency of the adjacent natural teeth.<sup>1</sup> This is because the esthetics of restorations play a pivotal role in their overall efficacy.<sup>2</sup> The field of dentistry has witnessed significant advancements in recent times, especially in the domain of metal-free treatment options.<sup>3</sup> In this context, several polymers have emerged as promising alternatives to ceramics for dental restoration procedures.<sup>3</sup> Polyether ether ketone (PEEK) is a state-of-the-art polymeric material that has been introduced in the field of dentistry and holds promise as a viable alternative substrate in prosthodontics. PEEK is a high-performance semi-crystalline thermoplastic polymer with a linear aromatic structure.<sup>4,5</sup> Its primary applications in dentistry are the creation of fixed dental prostheses, removable dentures, implant abutments, and components.<sup>6,7</sup> PEEK offers several advantages, such as enhanced biocompatibility, absence of metal, shaping flexibility with dental burs, and optimal physical properties.<sup>4,5</sup> Nonetheless, its primary drawbacks are a grayish color and low translucency, necessitating either resin composite or ceramics veneering, particularly in the esthetic zone.<sup>8</sup>

Achieving a composite restoration structurally and optically aligned with adjacent teeth is paramount in dental esthetic treatment. This level of harmonization is vital to ensuring patient satisfaction and acceptance of the treatment.<sup>9</sup> The utilization of multilayering techniques that rely on resin-based composites with varying opacity and shades has been found to replicate the natural appearance of teeth effectively.<sup>10</sup> However, this restorative procedure necessitates a meticulous selection of shades and a high level of technical proficiency, which can result in increased chair time and cost. Hence, there is a growing trend towards

streamlining the treatment process, which has the potential to mitigate technical sensitivities and bolster procedural efficacy.<sup>9</sup>

In the domain of restorative dentistry, the term 'chameleon effect' is utilized to denote the material's inherent capability to assimilate a hue similar to that of the neighboring tooth structure, thereby mimicking the natural appearance of teeth. This effect is a crucial aspect in the restoration process and aids in achieving a seamless blend between the artificial and natural elements of the teeth, thereby enhancing the overall esthetic value of the restoration.<sup>11,12</sup> This specific characteristic of dental property has instigated the creation of innovative dental composites that aim to simplify the process of selecting and reproducing shades. Natural teeth exhibit a range of characteristics, such as translucency, opalescence, and fluorescence, which must be accurately reproduced using resin composite materials during the restorative process to achieve optimal aesthetic outcomes.<sup>13</sup> Translucency is particularly noteworthy for its significant impact on the natural appearance of restorative materials.<sup>14</sup> Recently, resin-based composites have emerged, which are commonly referred to as "one shade" or "single shade" composite resins. These composites are designed to imitate all shades with just a single nominal shade esthetically.<sup>15</sup>

However, to the best of our knowledge, there is no study in the literature on using these new single-shade composites in veneering PEEK restorations. In light of this information, the objective of this study was to evaluate the color and translucency changes of single-shade composites used in veneering PEEK material after aging. The resins used for veneering were three single-shade composites with different chemical structures and a conventional multi-shade nanohybrid composite resin. The null hypothesis was that the color and translucency would not be affected by the composite resin type.



## MATERIALS AND METHODS

The PEEK specimens (Coprapeek, White Peaks Dental Systems GmbH & Co. KG., Essen, Germany) were configured as 2 mm thick and 10 mm diameter discs within the 3D design program (Autodesk Meshmixer v3.4.35, Autodesk Inc, San Rafael, CA, USA). They were then saved in standard tessellation language (STL) format and manufactured using a dental milling device (Coritec 550i, imes-icore, Eiterfeld, Germany) (N=40). One surface of the PEEK specimens was meticulously abraded under flowing water using 600-800-1000 grit sandpaper for 1 minute per grit to ensure consistent quality. A layer of A PEEK primer visio.link (Bredent GmbH & Co KG, Senden, Germany) was meticulously applied to the PEEK surface using a brush and subsequently light-cured for 90 seconds in a dual-mode light-curing unit (Labolight Duo, GC Europe, Leuven, Belgium). The prepared specimens were randomly divided into four subgroups (3 single shade and one conventional multishade) based on the applied composite resin (n=10): (1) A nanohybrid composite (Filtek Z550, 3M ESPE) (control), (2) a nanofilled composite resin (Omnichroma, Tokuyama), (3) a nanohybrid composite resin (Clearfill majesty ES-2, Kuraray) and (4) A bulk-fill nanohybrid ormocer (Admira Fusion x-tra, VOCO). Table 1 shows the composition of the tested composite resin materials. Composite resin materials were condensed onto PEEK specimens with a custom-made polytetrafluoroethylene mold (8 mm diameter and 2 mm thickness). Then, transparent glass was placed on top to obtain a flat surface and polymerized for 20 seconds with a light-

emitting diode (LED) light (Woodpecker B-Cure Plus, Guilin Guangxi, China). The specimens were placed in distilled water in a light-proof glass bottle with a screw cap for a duration of 24 hours. Initial color measurements were conducted within a color measurement cabinet coated with two layers of neutral gray paint. The cabinet was illuminated with a daylight lamp (D65) (TL-D Graphica 965 18W/965, Philips, Amsterdam, Holland) in accordance with Commission Internationale de l'Éclairage (CIE) standards, utilizing a portable spectrophotometer (Vita Easyshade Advance 4.0, Vita Zahnfabrik). Color change measurements were made on a gray background, and translucency change measurements were made on a black and white background. The spectrophotometer was configured to the single tooth measurement mode for the purpose of measuring the specimens. Prior to measuring each specimen, a calibration process was carried out by inserting the probe tip into the calibration port on the machine. The spectrophotometer probe was then placed perpendicular to the middle of the restorations, and three consecutive measurements were taken. The average value of these measurements was recorded. This protocol was repeated for all forty specimens. Upon completion of the initial color measurements, the specimens were promptly exposed to artificial aging at 5-55 °C (5000 cycles). The color measurements were conducted following the same procedure as the initial measurement, and the color difference and the relative translucency difference were determined using the  $\Delta E_{00}$  formulas:

$$\Delta E_{00} = \sqrt{\left(\frac{\Delta L^*}{K_L S_L}\right)^2 + \left(\frac{\Delta C^*}{K_C S_C}\right)^2 + \left(\frac{\Delta H^*}{K_H S_H}\right)^2 + R_T \left(\frac{\Delta C^*}{K_C S_C}\right)^2 \left(\frac{\Delta H^*}{K_H S_H}\right)^2}$$

$$TP_{00} = \sqrt{\left(\frac{L'_B - L'_W}{k_L S_L}\right)^2 + \left(\frac{C'_B - C'_W}{k_C S_C}\right)^2 + \left(\frac{H'_B - H'_W}{k_H S_H}\right)^2 + R_T \left(\frac{C'_B - C'_W}{k_C S_C}\right) \left(\frac{H'_B - H'_W}{k_H S_H}\right)}$$

**Table 1.** Compositions of the composite resin materials used in the study

Product	Composition	Type	Manufacturer
<b>Admira Fusion x-tra</b>	Ormocer® Organically modified silicic acid Aromatic and aliphatic dimethacrylates, methacrylate-functionalized polysiloxane, Ba-Al-glass, SiO <sub>2</sub> Filler rate: %84 wt	Bulk-Fill Nanohybrid Ormocer	Voco GMBH, Cuxhaven, Germany
<b>Clearfill Majesty ES-2</b>	Bis-GMA, Silanated barium glass filler, hydro aliphatic methacrylates phobic aromatic dimethacrylate pre polymerized organic filler. Filler rate: %78 wt	Nanohybrid	Kuraray, Okayama, Japan
<b>Omnichroma</b>	UDMA, TEGDMA, uniform sized supra-nano spherical filler (260 nm spherical SiO <sub>2</sub> -ZrO <sub>2</sub> ), and filler Filler content: 79 wt%	Nanofilled	Tokuyama Dental, Tokyo, Japan
<b>Filtek Z550 (Control)</b>	Matrix: BisGMA, UDMA, BisEMA, PEGDMA, TEGDMA Filler type: surface-modified zirconia/silica with a median particle size of 3 µm or less; Non-agglomerated/non-aggregated 20 nm surface-modified silica particles Filler rate: 82 wt%	Nanohybrid	3M ESPE, St. Paul, MN, USA

Abbreviations: UDMA, urethane dimethacrylate; Bis-GMA: bis-phenol-A glycidyl dimethacrylate; Bis-EMA, bisphenol-A-ethoxylated dimethacrylate; TEGDMA: triethylene glycol dimethacrylate; PEGDMA, polyethylene glycol dimethacrylate. Data are provided by manufacturers.

KC, KL, and KH serve as parametric factors that act as correction terms for experimental conditions. Additionally, RT is a rotation function for the interaction between chroma and hue differences in the blue region.

The data was analyzed using IBM SPSS version 23. The Shapiro-Wilk test was applied to assess the normal distribution of variances. One-way analysis of variance (ANOVA) was employed to compare color and translucency values across different composite resins, and the Tukey Honestly Significant Difference (HSD) test was conducted for multiple comparisons. The significance level was set at  $p < 0.05$ .

## RESULTS

The one-way ANOVA results (Table 2) showed significant differences among the color changes and relative translucency parameters of composite resins ( $p < 0.001$ ). The mean and standard deviation values of the color changes and relative translucency parameters from composite resins are illustrated in Table 3.

However, no significant difference was observed among the single-shade composite resin groups in both color and translucency change ( $p > 0.05$ ). The conventional multi-shade composite resin group showed the lowest color change ( $0.79 \pm 0.06$ ), followed by the supranano spherical-filled composite resin group ( $1.46 \pm 0.15$ ), nanofill composite resin group ( $1.52 \pm 0.11$ ) and nanohybrid filled ormocer based bulk-fill composite resin ( $1.59 \pm 0.09$ ) groups. All composite resin materials' color change was below the clinically acceptable limit ( $\Delta E = 1.8$ ). When relative translucency change was evaluated, the supranano spherical-filled composite resin group showed the lowest translucency change ( $0.25 \pm 0.06$ ), followed by the nanofill composite resin group ( $0.31 \pm 0.08$ ) and nanohybrid filled ormocer based bulk-fill composite resin ( $0.41 \pm 0.21$ ) groups. The conventional multi-shade composite resin group showed the highest relative translucency change ( $1.08 \pm 0.64$ ) with a statistically significant difference with single-shade composite resin groups.

**Table 2.** Results of one-way ANOVA for change in  $\Delta E_{00}$  and  $\Delta TP$  after artificial accelerated aging.

	Type III Sum of Squares	df	Mean Square	F	Sig.
$\Delta E_{00}$	49.23	3	16.219	401.973	<0.001
$\Delta TP$	38.649	3	12.883	367.273	<0.001

**Table 3.** Descriptive statistics of color change and translucency change values according to composite resin type

Composite Resin	Admira Fusion x-tra	Clearfill Majesty ES-2	Omnichroma	Filtek Z550 (Control)
$\Delta E_{00}$	1.59 ± 0.09 <sup>A</sup>	1.52 ± 0.11 <sup>A</sup>	1.46 ± 0.15 <sup>A</sup>	0.79 ± 0.06 <sup>B</sup>
$\Delta TP$	0.41 ± 0.21 <sup>a</sup>	0.31 ± 0.08 <sup>a</sup>	0.25 ± 0.06 <sup>a</sup>	1.08 ± 0.64 <sup>b</sup>

<sup>A-B</sup>: There is no difference between composite resins in color change with the same letter, <sup>a-b</sup>: There is no difference between composite resins in translucency change with the same letter

## DISCUSSION

The findings of the study showed that the composite resin type produced a statistically significant difference in color and translucency. Thus, the null hypothesis was rejected.

The growing focus on dental aesthetics in recent years has underscored the importance of precise color replication methods. Any inaccuracies in restoring the color of teeth can result in patient dissatisfaction and treatment failure.<sup>16</sup> Research indicates that 80% of patients experience dissatisfaction due to noticeable color variations between their dental restorations and adjacent teeth.<sup>17</sup> Therefore, the accurate selection and replication of shades are essential for ensuring successful restorations.

The CIELab color difference system is commonly employed in the evaluation of study outcomes. However, the CIEDE2000 system, a modification of the CIELab system, offers enhanced color perceptibility and acceptability. In a recent study conducted by Paravina et al.,<sup>18</sup> a group of volunteers, including laypersons, dental students and dentists, dental auxiliaries, and dental technicians, were involved in the observation of ceramics. The study aimed to establish the 50% perceptibility and acceptability threshold:  $\Delta E_{00} = 0.8$  denotes 50% perceptibility, while  $\Delta E_{00} = 1.8$  denotes 50% acceptability. None of the composite resin groups in this study presented results above the clinical acceptability threshold. In the present study, all the single-shade composite resin groups showed color change above the clinical perceptibility threshold. The results of this

study are consistent with those of a previous study in which single-shade composite resins were found to be above the clinical acceptability threshold, whereas multishade composite resin was above the clinical perceptibility threshold.<sup>19</sup>

The color stability of composite resins is influenced by the composition of the resin matrix and the type and size of the filler particles. The resin matrix plays a key role in determining the discoloration of composite resins. Various properties of the resin composition, including the chemical variances of resin monomers, the oxidation of unreacted monomers, and the concentration and/or type of initiators, activators, and inhibitors, collectively influence the discoloration potential of composite resins.<sup>20</sup> The color stability of resin monomers is influenced by their hydrophilic nature and water sorption capacity. A hydrophilic resin matrix with high water absorption can not only absorb water but also other colorant fluids, leading to discoloration.<sup>21</sup> On the other hand, filler particles don't absorb water but can attract it to their surface. Water sorption by the resin matrix may result in the hydrolysis of silane and the formation of microcracks, facilitating stain penetration and causing discoloration, thus reducing the restoration's lifespan.<sup>22</sup> It has been documented that resins with a higher degree of water sorption exhibit more pronounced discoloration when subjected to discoloration solutions.<sup>23</sup> Furthermore, it has been affirmed that the BisGMA-based resin matrix displays enhanced water sorption due to its hydrophilic nature, resulting in reduced stain resistance compared

to other methacrylate monomers, such as UDMA. Additionally, the increment of TEGDMA content in the resin matrix from 0% to 1% has been associated with a rise in water uptake of BisGMA-based resins from 3% to 6%.<sup>24</sup> In the current study, it is important to note that only the bulk-fill nanohybrid ormocer group lacks TEGDMA and Bis-GMA. Hence, it was anticipated that the color change would be lower in comparison to other single-shade composite resin groups and the conventional composite resin group. However, in line with previous studies, it was observed that ormocer-based composite exhibited a statistically higher level of discoloration compared to the conventional restorative material.<sup>25,26</sup> The discoloration observed can be attributed to the inadequate integration of siloxane particles between the resin matrix and the pre-polymerized microfilm products, potentially resulting from discoloration.<sup>26</sup> Despite the hydrophobic nature of the ormocer-based matrix, improper silanization of the organic and inorganic constituents, and incomplete integration into the resin matrix may facilitate the ingress of water and coloring agents into the composite resin, consequently leading to discoloration.<sup>26</sup> In the current study, similar to previous research,<sup>27,28</sup> it was observed that the color stability of single-shade composites was comparatively lower than that of conventional composites. This may be attributed to their resin matrix composition. The conventional multi-shade composite comprises high molecular weight monomers like BisEMA, which are renowned for their low water sorption, which is attributed to their hydrophobicity and high degree of conversion.<sup>29</sup>

The optical properties of restorative materials are impacted not only by the composition of organic matrix and inorganic fillers but also by including dyes and other chemical agents.<sup>30</sup> Pigments or colorants within a material selectively absorb light at specific

wavelengths and promote the scattering of other wavelengths.<sup>31</sup> The reflection and refraction of light at internal interfaces lead to multidirectional scattering within the material.<sup>31</sup> The translucency of the material assumes significant importance in the decision-making process pertaining to the restoration or replacement of dental restorations, particularly in areas emphasizing esthetic outcomes.<sup>32</sup> According to previous studies, BisGMA-based resin materials have demonstrated greater translucency in comparison to UDMA/TEGDMA-based resin materials.<sup>33,34</sup> The observed distinction in translucency between Bis-GMA and silica fillers in comparison to TEGDMA may be attributed to their closer refractive index alignment. Consequently, in the present study, the single-shade nanohybrid composite exhibited higher translucency than the control group. Furthermore, the UDMA/TEGDMA containing single-shade nanofilled composite demonstrated translucency results similar to those of single-shade Bis-GMA containing nanohybrid composite resin. Literature has indicated that nanofilled composites display heightened translucency owing to their smaller filler sizes, which fall below the wavelengths of visible light (380-780 nanometers).<sup>35</sup>

The study is subject to certain limitations. Firstly, due to its *in vitro* nature, it remains unable to precisely replicate the oral environment. Secondly, while the materials within the oral cavity exhibit concave and convex features following the anatomy, the study utilizes samples with flat surfaces. This may lead to differences in how materials reflect light. Third, a single thickness was used for veneering with composite resin. Different thicknesses may cause different translucencies. Therefore, future studies should investigate the color change of the single-shade composite resins with different thicknesses similar to tooth shape specimens.

## CONCLUSIONS

The study's findings demonstrate the potential use of single-shade composite resins as an optical alternative for direct veneering procedures on PEEK material. Although the observed color change exceeds that of conventional composite resins, it remains below the clinically acceptable threshold.

### Ethical Approval

This in-vitro study does not require ethics committee approval.

### Financial Support

The authors declare that this study received no financial support.

### Conflict of Interest

The authors deny any conflicts of interest related to this study.

### Author Contributions

Design: IK, Data collection or data entry: IK, IA, Analysis and interpretation: IK, IA, Literature search: IK, IA, Writing: IK, IA.

## REFERENCES

- den Hartog L, Slater JJ, Vissink A, Meijer HJ, Raghoobar GM. Treatment outcome of immediate, early and conventional single-tooth implants in the aesthetic zone: a systematic review to survival, bone level, soft-tissue, aesthetics and patient satisfaction. *J Clin Periodontol.* 2008;35:1073-86.
- Villarroel M, Fahl N, De Sousa AM, De Oliveira OB Jr. Direct esthetic restorations based on translucency and opacity of composite resins. *J Esthet Restor Dent.* 2011;23:73-87.
- Elsawaf M, Aboushady YS, El-Shabrawy SM. Veneering thickness effect on the optical properties of peek restorations (In vitro study). *Alex Dent J.* 2019;44:99-102.
- Stawarczyk B, Beuer F, Wimmer T, Jahn D, Sener B, Roos M, et al. Polyetheretherketone-a suitable material for fixed dental prostheses? *J Biomed Mater Res B Appl Biomater.* 2013;101:1209-16.
- Fuhrmann G, Steiner M, Freitag-Wolf S, Kern M. Resin bonding to three types of polyaryletherketones (PAEKs)-durability and influence of surface conditioning. *Dent Mater.* 2014;30:357-63.
- Kern M, Lehmann F. Influence of surface conditioning on bonding to polyetheretherketon (PEEK). *Dent Mater.* 2012;28:1280-3.
- Najeeb S, Zafar MS, Khurshid Z, Siddiqui F. Applications of polyetheretherketone (PEEK) in oral implantology and prosthodontics. *J Prosthodont Res.* 2016;60:12-9.
- Stawarczyk B, Keul C, Beuer F, Roos M, Schmidlin PR. Tensile bond strength of veneering resins to PEEK: impact of different adhesives. *Dent Mater J.* 2013;32:441-8.
- Lucena C, Ruiz-López J, Pulgar R, Della Bona A, Pérez MM. Optical behavior of one-shaded resin-based composites. *Dent Mater.* 2021;37:840-8.
- Dietschi D, Fahl N Jr. Shading concepts and layering techniques to master direct anterior composite restorations: an update. *Br Dent J.* 2016;221:765-71.
- Paravina RD, Westland S, Johnston WM, Powers JM. Color adjustment potential of resin composites. *J Dent Res.* 2008;87:499-503.
- Paravina RD, Westland S, Imai FH, Kimura M, Powers JM. Evaluation of blending effect of composites related to restoration size. *Dent Mater.* 2006;22:299-307.
- Terry DA, Geller W, Tric O, Anderson MJ, Tourville M, Kobashigawa A. Anatomical form defines color: function, form, and aesthetics. *Pract Proced Aesthet Dent.* 2002;14:59-67.
- Yu B, Ahn JS, Lee YK. Measurement of translucency of tooth enamel and dentin. *Acta Odontol Scand.* 2009;67:57-64.
- Iyer RS, Babani VR, Yaman P, Dennison J. Color match using instrumental and visual methods for single, group, and

- multi-shade composite resins. *J Esthet Restor Dent.* 2021;33:394-400.
16. Mayekar SM. Shades of a color. Illusion or reality? *Dent Clin North Am.* 2001;45:155-72.
  17. Elamin HO, Abubakr NH, Ibrahim YE. Identifying the tooth shade in group of patients using Vita Easyshade. *Eur J Dent.* 2015;9:213-7.
  18. Paravina RD, Ghinea R, Herrera LJ, Bona AD, Igiel C, Linninger M, et all. Color difference thresholds in dentistry. *J Esthet Restor Dent.* 2015;27:S1-9.
  19. Fidan M, Yağci Ö. Effect of aging and fiber-reinforcement on color stability, translucency, and microhardness of single-shade resin composites versus multi-shade resin composite. *J Esthet Restor Dent.* 2024;36:632-42.
  20. Barutcigil C, Yildiz M. Intrinsic and extrinsic discoloration of dimethacrylate and silorane-based composites. *J Dent.* 2012;40:e57-63.
  21. Bagheri R, Burrow MF, Tyas M. Influence of food-simulating solutions and surface finish on susceptibility to staining of aesthetic restorative materials. *J Dent.* 2005;33:389-98.
  22. Mair LH. Staining of in vivo subsurface degradation in dental composites with silver nitrate. *J Dent Res.* 1991;70:215-20.
  23. Reis AF, Giannini M, Lovadino JR, Ambrosano GM. Effects of various finishing systems on the surface roughness and staining susceptibility of packable composite resins. *Dent Mater.* 2003;19:12-8.
  24. Kalachandra S, Turner DT. Water sorption of polymethacrylate networks: bis-GMA/TEGDM copolymers. *J Biomed Mater Res.* 1987;21:329-38.
  25. Ardu S, Braut V, Gutemberg D, Krejci I, Dietschi D, Feilzer AJ. A long-term laboratory test on staining susceptibility of esthetic composite resin materials. *Quintessence Int.* 2010;41:695-702.
  26. Gregor L, Krejci I, Di Bella E, Feilzer AJ, Ardu S. Silorane, ormocer, methacrylate and compomer long-term staining susceptibility using  $\Delta E$  and  $\Delta E_{00}$  colour-difference formulas. *Odontology.* 2016;104:305-9.
  27. Chen S, Zhu J, Yu M, Jin C, Huang C. Effect of aging and bleaching on the color stability and surface roughness of a recently introduced single-shade composite resin. *J Dent.* 2024;143:104917.
  28. Ersöz B, Karaoğlanoğlu S, Oktay EA, Aydın N. Resistance of Single-shade Composites to Discoloration. *Oper Dent.* 2022;47:686-92.
  29. Gajewski VE, Pfeifer CS, Fróes-Salgado NR, Boaro LC, Braga RR. Monomers used in resin composites: degree of conversion, mechanical properties and water sorption/solubility. *Braz Dent J.* 2012;23:508-14.
  30. Gonder HY, Fidan M. Effect of different polymerization times on color change, translucency parameter, and surface hardness of bulk-fill resin composites. *Niger J Clin Pract.* 2022;25:1751-7.
  31. Yu B, Lee YK. Influence of color parameters of resin composites on their translucency. *Dent Mater.* 2008;24:1236-42.
  32. Arif R, Yilmaz B, Johnston WM. In vitro color stainability and relative translucency of CAD-CAM restorative materials used for laminate veneers and complete crowns. *J Prosthet Dent.* 2019;122:160-6.
  33. Miletic V, Jakovljevic N, Manojlovic D, Marjanovic J, Rosic AA, Dramicanin MD. Refractive indices of unfilled resin mixtures and cured composites related to color and translucency of conventional and low-shrinkage composites. *J Biomed Mater Res B Appl Biomater.* 2017;105:7-13.
  34. Azzopardi N, Moharamzadeh K, Wood DJ, Martin N, Van Noort R. Effect of resin matrix composition on the translucency of experimental dental composite resins. *Dent Mater.* 2009;25:1564-8.
  35. Ergucu Z, Turkun LS, Aladag A. Color stability of nanocomposites polished with one-step systems. *Oper Dent.* 2008;33:413-20.

## Retrospective Radiographic Evaluation of Implant Complications: CBCT-Based Study

Didem DUMANLI<sup>1\*</sup>  Çiğdem ŞEKER<sup>2</sup>  Gediz GEDUK<sup>3</sup> 

<sup>1</sup> Res. Ass., Retrospective Radiographic Evaluation of Implant Complications, Zonguldak Bülent Ecevit University, Faculty of Dentistry, Oral Maxillofacial Radiology, Zonguldak, Türkiye, didem.dumanli@hotmail.com

<sup>2</sup> Asst. Prof., Retrospective Radiographic Evaluation of Implant Complications, Zonguldak Bülent Ecevit University, Faculty of Dentistry, Oral Maxillofacial Radiology, Zonguldak, Türkiye, cgdmdmrhn@gmail.com

<sup>3</sup> Assoc. Prof., Retrospective Radiographic Evaluation of Implant Complications, Zonguldak Bülent Ecevit University, Faculty of Dentistry, Oral Maxillofacial Radiology, Zonguldak, Türkiye, gedizgeduk@gmail.com

### Article Info

#### Article History

Received: 23.06.2024

Accepted: 02.09.2024

Published: 15.10.2024

#### Keywords:

Implant,  
Complication,  
Cone beam computed  
tomography,  
Maxillary sinus.

### ABSTRACT

**Aim:** Dental implants are a popular treatment option for patients with one or more missing teeth. With the increase in dental implant treatments, the complications encountered have increased. Therefore, it is very important to plan the implant by evaluating the anatomy of the area where the implant will be placed in three dimensions with cone beam computed tomography (CBCT). The aim of this study is to evaluate the prevalence of implant complications seen in CBCT after implant applications.

**Material and Methods:** CBCT images of 500 patients obtained for different dental reasons were examined; among these, 300 dental implant images were evaluated retrospectively in terms of complications. The number, location and type of identified complications (perforation in the maxillary sinus, mandibular canal, cortical bone, nasal cavity, and mental canal; contact with the adjacent tooth root) were recorded. The data obtained were analyzed statistically using chi-square tests.

**Results:** At least one complication was detected in 65% of the 300 dental implants evaluated. A total of 272 complications (1.4 complications per implant) were observed in 195 dental implants with complications. The number of implants with complications per patient was found to be 3.9. The most observed complication was found to be vertical bone resorption around the implant (45%). Complications were most frequently detected in the maxillary posterior region (40%).

**Conclusion:** Three-dimensional CBCT evaluation of the area where the implant will be applied before and after treatment is very important to prevent possible complications.

## İmplant Komplasyonlarının Retrospektif Olarak Radyografik Değerlendirilmesi: KIBT Tabanlı Çalışma

### Makale Bilgisi

#### Makale Geçmişi

Geliş Tarihi: 23.06.2024

Kabul Tarihi: 02.09.2024

Yayın Tarihi: 15.10.2024

#### Anahtar Kelimeler:

İmplant,  
Komplikasyon,  
Konik ışınli bilgisayarlı  
tomografi,  
Maksiller sinus.

### ÖZET

**Amaç:** Dental implantlar, bir veya daha fazla diş eksikliği olan hastalar için popüler bir tedavi seçeneğidir. Dental implant tedavilerinin artmasıyla birlikte karşılaşılan komplikasyonlarda artmıştır. Bu yüzden implantın yerleştirileceği bölgenin anatomisini üç boyutlu olarak konik ışınli bilgisayarlı tomografi (KIBT) ile değerlendirerek implant planlaması yapmak çok önemlidir. Bu çalışmanın amacı, implant uygulamaları sonrası KIBT’da görülen implant komplikasyonlarının prevalansının değerlendirilmesidir.

**Gereç ve Yöntemler:** Farklı dental nedenlerden dolayı elde edilmiş 500 hastaya ait KIBT görüntüleri incelendi; bunların içinden 300 dental implant tespit edilen görüntüler komplikasyonlar açısından retrospektif olarak değerlendirildi. Belirlenen komplikasyonların sayısı, lokalizasyonu ve tipi (maksiller sinüs, mandibular kanal, kortikal kemik, nazal kavite, ve mental kanalda perforasyon; komşu diş kökü ile temas) kaydedildi. Elde edilen veriler ki-kare testleriyle istatistiksel olarak analiz edildi.

**Bulgular:** Değerlendirilen 300 dental implantın % 65’inde en az bir komplikasyon tespit edildi. Komplasyonlu 195 dental implantta toplam 272 komplikasyon (implant başına 1,4 komplikasyon) gözlemlendi. Hasta başına düşen komplasyonlu implant sayısı 3,9 olarak bulundu. En fazla gözlenen komplasyon implant çevresindeki vertikal kemik rezorpsiyonu (%45) olarak bulundu. En sık maksiller posterior bölgede (%40) komplasyon tespit edildi.

**Sonuç:** İmplantın uygulanacağı bölgenin KIBT ile üç boyutlu olarak tedavi öncesi ve sonrası değerlendirilmesi meydana gelebilecek komplasyonların önlenmesi açısından çok önemlidir.

**To cite this article:** Dumanlı D, Şeker Ç, Geduk G. Retrospective Radiographic Evaluation of Implant Complications: CBCT-Based Study. NEU Dent J. 2024;6(Special Issue):9-17. <https://doi.org/10.51122/neudentj.2024.110>

\*Corresponding Author: Didem DUMANLI, [didem.dumanli@hotmail.com](mailto:didem.dumanli@hotmail.com)



## **INTRODUCTION**

Nowadays, dental implants are a commonly favored treatment choice for patients with one or more missing teeth. Literature reports indicate that the survival rates of dental implants are exceedingly high.<sup>1,2</sup> However, the success rates are not as high as the survival rates. Implant survival is the presence of an implant in the relevant area after implant treatment.<sup>3</sup> Today, with the increase in dental implant treatments, the incidence of complications increases in direct proportion, affecting the implant's success. Survival and success regarding implants are different concepts. Implant success means the implant is healthy and fully functional in the mouth.<sup>3,4</sup>

Complications that may be encountered during and after implant treatment affect the success of the implant.<sup>5</sup> Before treatment, detailed evaluation of the anatomical structures and variations in the relevant region and an appropriate treatment plan are very important regarding complication.<sup>3,5,6</sup>

In implant treatment, buccal and lingual bone perforations may occur due to the thinness of the alveolar bone in the mandible anterior region. As a result, infection conditions such as osteomyelitis in the mandible and displacement of the implant into soft tissues outside the bone may occur.<sup>7</sup> In the mandibular posterior region, the mandibular canal and its contents may occur. There is a vascular nerve bundle. As a result of a perforation in the mandibular canal, hematoma, and edema may occur due to vascular damage, paraesthesia and hypoesthesia may occur in the soft tissues, teeth and bones in the relevant region due to damage to the mandibular nerve. Likewise, bleeding and paresthesia may occur as a result of perforation of the mental foramen in the mandibular premolar region.<sup>8</sup> Maxillary sinus perforation in the maxilla posterior region may cause sinus infection and nasal cavity floor perforation in the maxilla anterior region may cause nasal

cavity infection, and as a result of perforations in the relevant regions, the implant may cause adjacency in the maxillary sinus and nasal cavity. It can displace anatomical structures.<sup>5,9</sup>

To enhance the efficacy of implant treatments, the utilization of cone beam computed tomography (CBCT), which enables three-dimensional imaging is advocated during treatment planning. CBCT proves to be a valuable radiographic technique for assessing implant positioning errors, especially when patients exhibit clinical symptoms like pain and implant mobility, as it furnishes additional insights beyond two-dimensional images.<sup>10</sup> Additionally, it's imperative to recognize that technical errors occurring during dental implant procedures might be associated with complications that don't manifest immediate symptoms. Hence, evaluating implants in CBCT scans obtained for other purposes may facilitate early detection of these errors in the pre-symptomatic phase.<sup>10,11</sup>

Understanding the prevalence of various implant positioning errors and their most common locations is crucial in notifying dentists to the necessity of meticulous surgical planning in dental implant procedures.<sup>11</sup>

This study aims to assess the prevalence of implant placement complications identified via CBCT after implant procedures.

## **MATERIALS AND METHODS**

In this study, radiographic images of patients who applied to Zonguldak Bülent Ecevit University Faculty of Dentistry between 2023 and 2024 for various reasons and for whom CBCT was indicated were used. The CBCT images included in the study were obtained with a Veraviewepocs 3D R100/F40 (J Morita Mfg. Corp., Kyoto, Japan) tomography device using 90 kVp 5mA in 8x10 cm, 8x8 cm and 8x5 cm FOV areas.

Data from patients with syndromes or congenital anomalies, fractures in the jaw and

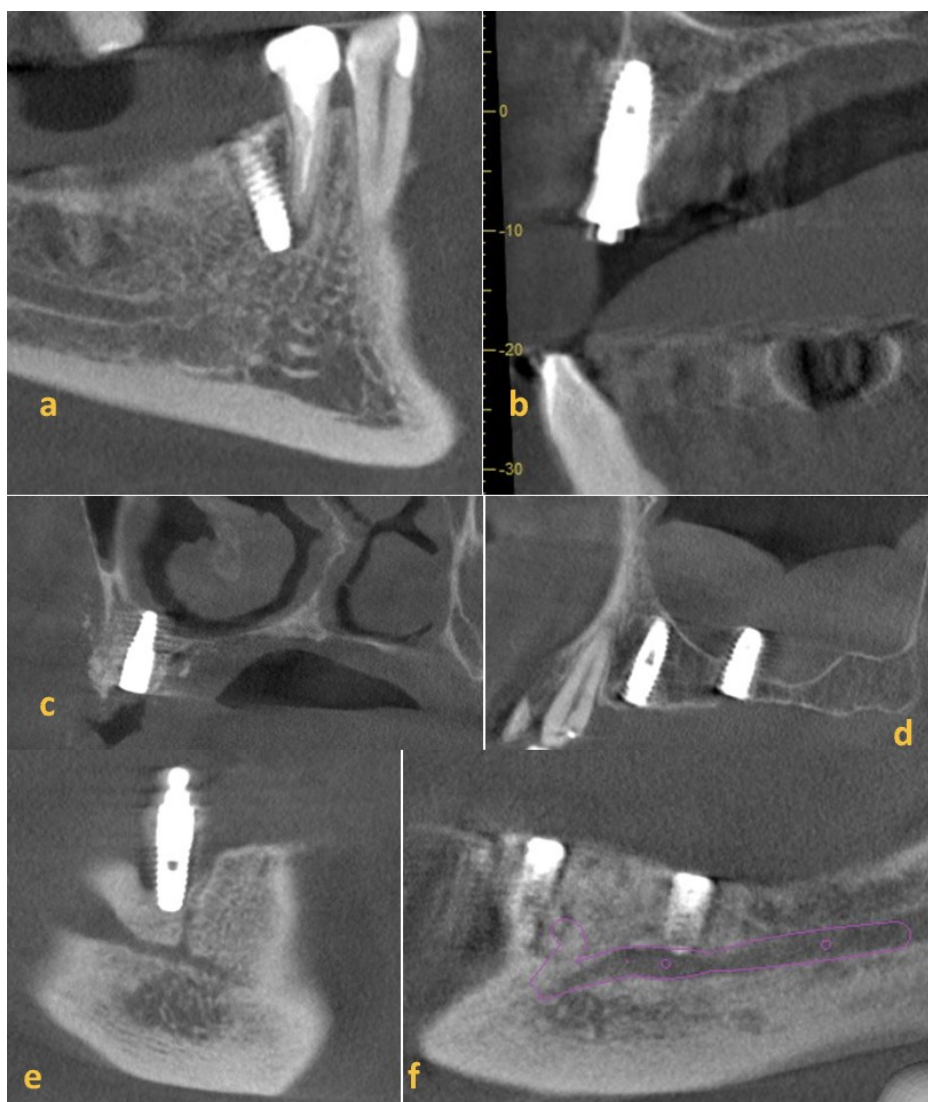


face, and data with artifacts that would prevent the evaluation of images were excluded from the study. Data collection and CBCT evaluations were performed by two oral and maxillofacial radiologists.

CBCT evaluations were performed simultaneously once by the radiologists by mutual agreement. Observation conditions were optimized by displaying all images on the same computer monitor. The viewing distance for the observers was kept at approximately 50 cm and the lights were dimmed during the examinations. 500 CBCT images were evaluated and CBCT images containing at least 1 dental implant were included in the study. A total of 300 CBCT images containing dental

implants from 50 patients, 21 female and 29 male, aged 19-78 were retrospectively evaluated for complications. The mean age of the patients was found to be 56.94 years.

The collected data were examined in terms of patient's gender, implant placement site, number of implants placed per person and complications per implant. Types of implant complications include; the maxillary sinus, nasal cavity, mandibular canal, mental canal and buccal or lingual/palatal bone perforations were evaluated in terms of adjacent tooth contact and vertical bone resorption (Figure 1). Implants with dehiscence and fenestration in buccal or lingual/palatal bones were considered as bone perforation.



**Figure 1:** Complication type; a: adjacent tooth contact, b: buccal bone perforation, c: nasal cavity perforation, d: maxillary sinus perforation, e: vertical bone resorption, f: mandibular canal perforation

### Statistical analysis

Statistical analysis was conducted using IBM Corp. Released 2013. IBM SPSS Statistics for Windows, Version 22.0. Armonk, NY: IBM Corp. Descriptive statistics and chi-square tests were employed for the statistical analysis of the data. According to the tests performed, cases where the p value was " $p < 0.05$ " were interpreted as there was a statistically significant difference and cases where " $p > 0.05$ " were interpreted as there was no statistically significant difference.

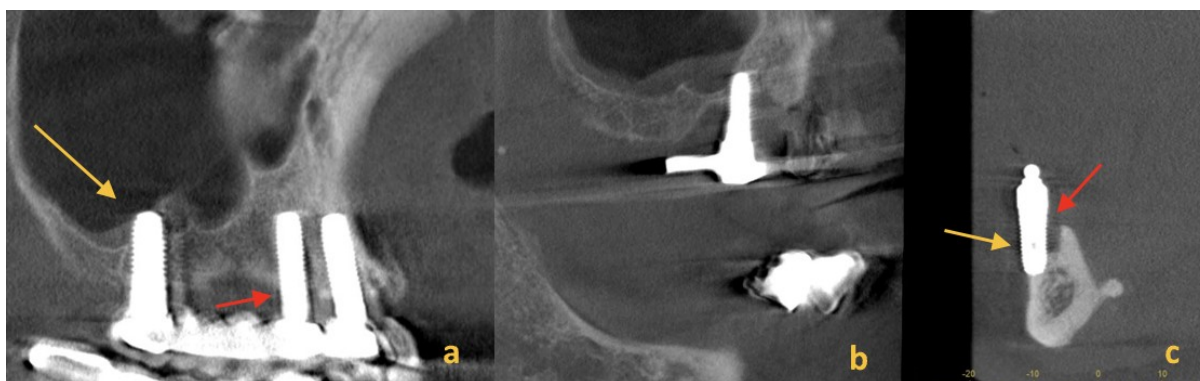### Ethical approval

The necessary ethical approval for this study was obtained from the Zonguldak Bülent Ecevit University Non-Interventional Clinical Research Ethics Committee (2023/04).

### RESULTS

Dental implants were detected in 300 of the 500 CBCT images evaluated. A total of 272 complications were observed in 195 dental implants with complications. In 65% of dental implant cases, at least one complication was detected. There were 1.4 complications per implant. The number of implants with complications per patient was found to be 3.9.

The most common complication observed was found to be vertical bone resorption around the implant (45%). This was followed by buccal bone perforation (24%), lingual bone perforation (23%) and maxillary sinus perforation (23%) (Figure 2). Other less frequent complications included palatal/lingual bone perforation (18%), nasal cavity perforation (3%), perforation of the mandibular canal (2%) and perforation of the mental canal (2%) (Table 1).



**Figure 2:** The most common types of complications; a: orange arrow: maxillary sinus perforation; red arrow: vertical bone resorption, b: maxillary sinus perforation from a different patient, c: orange arrow: buccal bone perforation; red arrow: vertical bone resorption.

**Table 1:** Numerical data of complication localizations

Complication localization	Percentage (%)	Number
Maxilla posterior	40%	76
Maxilla anterior	12%	24
Mandible posterior	30%	59
Mandible anterior	18%	36

Implant complications occurred most commonly in the maxillary posterior region (40%), followed by the mandibular posterior region (30%), mandibular anterior region (18%) and maxillary anterior region (12%) (Table 2). Upon evaluation of implant complications by gender, no significant difference was found between male and female (Table 3).

**Table 2:** Numerical data on types of complications

Complication type	Complication number	Complication percentage (%)
Maxillary sinus perforation	44	23
Nasal cavity perforation	6	3
Mandibular canal perforation	5	2
Buccal bone perforation	47	24
Palatinal/lingual bone perforation	34	18
Adjacent tooth contact	44	23
Mental canal perforation	4	2
Vertical bone resorption	88	45

**Table 3:** Distribution of complication types by gender

Complication type	Female		Male		Total		P value
	available	unavailable	available	unavailable	Female	Male	
Maxillary sinus perforation	11	10	11	18	21	29	0.829
Nasal cavity perforation	4	17	1	28	21	29	0.174
Mandibular canal perforation	2	19	3	26	21	29	0.924
Buccal bone perforation	13	8	11	18	21	29	0.333
Palatinal/lingual bone perforation	5	16	15	14	21	29	0.166
Adjacent tooth contact	8	13	19	10	21	29	0.116
Mental canal perforation	2	19	2	27	21	29	0.872
Vertical bone resorption	12	9	17	12	21	29	0.738

chi square test,  $p > 0.05$

## DISCUSSION

In the literature, numerous studies explore complications linked to dental implants. Typically, these complications include penetration into anatomical structures, perforation and angulation errors of dental implants within the bone.<sup>3,11</sup> In this study, vertical bone resorption was identified as the most prevalent implant complication. Vertical bone resorption can occur as a result of various situations such as placing the implant at the wrong angle, excessive and unbalanced occlusal loading, and poor oral hygiene of the patient.<sup>4,10,11</sup> Periimplantitis is observed in

patients with poor oral hygiene, leading to vertical bone loss occurs. Quiryen et al. reported that the frequency of periimplantitis increased in the long term and implant losses along with vertical bone loss.<sup>12</sup> The healing mechanisms are compromised in certain systemic conditions like diabetes and cardiovascular diseases.<sup>13,14</sup> Studies have shown that bone healing is acceptable in patients with controlled diabetes in contrast to those with uncontrolled diabetes.<sup>15,16</sup>

For the appropriate hard and soft tissue thickness to be formed between the implants and the adjacent teeth, there must be a distance

of 2 mm or at least one mm between the adjacent natural tooth and the implant.<sup>17</sup> If the bur is not used with the correct parallelism and angle during implant treatment, it may cause damage to adjacent teeth. Therefore, the anatomy of the adjacent teeth and the area, where the implant will be applied, should be carefully evaluated before the treatment. Adjacent teeth should be examined for root dilatation, malposition or anomalies.<sup>18</sup>

There should be a minimum distance of one millimeter between the implant and the buccal and lingual/palatal bone.<sup>6</sup> There is arteria palatinus major in the palatal part of the maxilla. It is an important artery and provides nutrition to the palatal part of the maxilla with its branches. There is also a nerve with the same name as the artery in the relevant region. Perforation of the implant in the palatal bone may cause damage to this artery and nerve, loss of sensation and severe bleeding. These complications are intraoperative and early implant complications and are very rare. These types of complications were not detected in this study.

There are submandibular and sublingual fossae on the lingual side of the mandible. These fossae contain important arteries, veins, nerves, submandibular and sublingual salivary glands.<sup>5,19</sup> As a result of perforation of the lingual bone, the implant may be displaced into these fossae and damage important anatomical structures in the relevant region.

It has been reported that if the perforation depth caused by the dental implant in the maxillary sinus is two mm or less, the sinus floor regenerates itself. If the maxillary sinus perforation cannot regenerate itself, the implant may migrate within the sinus. This situation can lead to sinusitis in the maxillary, ethmoid and sphenoid sinuses potentially causing meningitis in the middle skull base and orbital infections as it progresses to the orbit.<sup>20,21</sup> In 2024, a case of an implant displaced to the middle skull base in Turkey was reported in the literature.<sup>21</sup>

In studies assessing nerve damage resulting from perforation of the mental and mandibular canal, which are among the types of complications associated with implants, temporary and permanent damage rates vary between 6.5% to 36%.<sup>3,22,23</sup> In the studies, patients were followed at intervals such as 6 months, 1, 2, 3, and 4 years.<sup>22,23,24</sup> The prevalence of mental and mandibular canal perforation ranges between 4-7% in the literature.<sup>25</sup> In this study, the prevalence of mental and mandibular canal perforation was evaluated separately and both were found to be 2%. In studies evaluating mandibular canal perforation in the literature, the change in sensation varies between 10-15%.<sup>3,22,23</sup> When the topography of the maxilla and mandible is examined, the mandible anterior region consists largely of cortical bone, while the mandible posterior and maxilla anterior regions consist partly of cortical and partly of cancellous bone, while the maxilla anterior region consists largely of spongy bone. Implant success is higher in cortical bone than in cancellous bone. In this study, we found that there were fewer complications in the anterior region of the mandible compared to the posterior region of the maxilla, which supports this observation.<sup>6,26</sup>

A few studies are reporting nasal cavity perforation.<sup>27,28</sup> In this, it was also found at a low rate (3%). The nasal cavity floor, like the maxillary sinus floor, can repair itself at small perforation depths.<sup>7,27</sup> The data obtained in this study were found to be consistent with other similarly structured studies in the literature. Clark et al. and Pamukcu et al. also found the most common complication type to be vertical bone resorption and the area with the most complications to be the maxilla posterior region in both studies. McDermott et al. also found the most complications in the maxilla posterior region.<sup>3,5</sup>

Since this study is retrospective, it is not known whether any complications occurred due to the systemic conditions and oral hygiene of

the patients; it is unclear whether complicated implants caused any anatomical structure damage or infection, and these situations are among the limitations of the study. Another limitation of this study is the beam hardening artifact that occurs around the implant in CBCT. This artifact can be visualized as any bone loss or perforation around the implant. In order to minimize this situation, evaluations can be made by using some metal artifact reduction (MAR) algorithms and keeping the field of view (FOV) of the relevant region as small as possible. The material the implant is made of and the location of the implant in the jaw affect the amount of artifact. MAR is effective in reducing zirconia implant artifacts, while it fails to bar presence of titanium implant artifacts.<sup>29,30</sup>

The probability of perforation with a bone thickness of less than 1 mm is quite high. González-Martín et al. reported that the probability of detecting a bone wall of 0.5 mm and below is less than 20% and that the chance of detecting bone increases by 30.6% with each mm increase in bone thickness.<sup>31</sup> However, Corpos et al. reported that there are statistically significant correlations between radiographic images obtained with CBCT and histological sections and that the standard deviation of the defect amount is less than 0.5 mm in 50% of bone defects.<sup>32,33</sup>

## **CONCLUSION**

The number of dentists is increasing day by day in our country and in the world and dentists perform implant treatments without sufficient knowledge and experience. This situation increases the incidence of complications. As seen in this study, implant complication rates are high. The most common implant complication is vertical bone perforation, and more attention should be paid to vertical angulation and occlusal loading during implant applications. Complications were most frequently seen in the maxillary posterior region. A more careful evaluation of the relevant region with CBCT would be beneficial for physicians.

## **Ethical Approval**

The required ethical approval for this study was received by the Zonguldak Bülent Ecevit University Non-Interventional Clinical Research ethics committee (2023/04).

## **Financial Support**

The authors declare that this study received no financial support.

## **Conflict of Interest**

The authors deny any conflicts of interest related to this study.

## **Author Contributions**

Design: DD, Data collection or data entry: DD, ÇŞ, Analysis and interpretation: DD, GG, Literature review: ÇŞ, DD, Writing: DD, ÇŞ.

## **REFERENCES**

1. Balshi TJ, Wolfinger GJ, Stein BE, Balshi SF. A long-term retrospective analysis of survival rates of implants in the mandible. *Int J Oral Maxillofac Implants.* 2015;30:1348-54.
2. DeAngelis F, Papi P, Mencio F, Rosella D, DiCarlo S, Pompa G. Implant survival and success rates in patients with risk factors: results from a long-term retrospective study with a 10 to 18 years follow-up. *Eur Rev Med Pharmacol Sci.* 2017;21:433-7.
3. Pamukcu U, Ispir GN, Alkurt MT, Altunkaynak B, Peker İ. Retrospective evaluation of complications in dental implants using cone beam computed tomography. *Selcuk Dent J.* 2021;8:367-371.
4. Kohavi D, Azran G, Shapira C, Casap N. Retrospective clinical review of dental implants placed in a university training program. *J Oral Implantol.* 2004;30:23-9.
5. Clark D, Barbu H, Lorean A, Mijiritsky E, Levin L. Incidental findings of implant complications on postimplantation cbcts: a cross-sectional study. *Clin Implant Dent Relat Res.* 2017;19:776-782.
6. Misch K, Wang H-L. Implant surgery

- complications: etiology and treatment. *Implant Dent.* 2008;17:159-68.
7. Urvasızoğlu G, Turen T. Prevalence and treatment methods of intraoperative and early complications encountered in dental implant applications: a retrospective clinical study. *Curr Res Dent Sci.* 2019;29:259-67.
  8. Park SH, Wang HL. Implant reversible complications: classification and treatments. *Implant Dent.* 2005;14:211-20.
  9. Elhamruni LM, Marzook HA, Ahmed WM, Abdul-Rahman M. Experimental study on penetration of dental implants into the maxillary sinus at different depths. *Oral Maxillofac Surg.* 2016;20:281-7.
  10. White S, Pharoah's M. *Oral Radiology Principles and Interpretation.* 8th ed. St. Louis: Mosby; 2018. p. 325-515.
  11. Froum S. Implant complications: scope of the problem. In Froum S. *Dental implant complications.* New York: John Wiley & Sons; 2010. p. 2-6.
  12. Quirynen M, Abarca M, Assche VN, Nevins M, Steenberghe DV. Impact of supportive periodontal therapy and implant surface roughness on implant outcome in patients with a history of periodontitis. *J Clin Periodontol.* 2007;34:805-15.
  13. Moy PK, Medina D, Shetty V, Aghaloo TL. Dental implant failure rates and associated risk factors. *Int J Oral Maxillofac Implants.* 2005;20:569-77.
  14. Palma-Carrió C, Maestre-Ferrín L, Peñarrocha-Oltra D, Peñarrocha-Diago MA, Peñarrocha-Diago M. Risk factors associated with early failure of dental implants. A literature review *Med Oral Patol Oral Cir Bucal.* 2011;16:514-7.
  15. Balshi TJ, Wolfinger GJ. Dental implants in the diabetic patient: A retrospective study. *Implant Dent.* 1999;8:355-9.
  16. Javed F, Romanos GE. Review impact of diabetes mellitus and glycemic control on the osseointegration of dental implants: A Systematic Literature Review. *J Periodontol.* 2009; 80:1719-30.
  17. Zetu L, Wang HL. Management of interdental/inter-implant papilla. *J Clin Periodontol.* 2005;32:831-9.
  18. Kim SG. Implant-related damage to an adjacent tooth: a case report. *Implant Dent.* 2000;9:278-80.
  19. Balaguer-Marti JC, Penarrocha-Oltra D, Balaguer-Martinez J, Penar-rocha-Diago M. Immediate bleeding complications in dental implants: a systematic review. *Med Oral Patol Oral Cir Bucal.* 2015;20:e231-8.
  20. Felisati G, Lozza P, Chiapasco M, Borloni R. Endoscopic removal of an unusual foreign body in the sphenoid sinus: an oral implant. *Clin Oral Implants Res.* 2007;18:776-80.
  21. Ozmarasali AI, Kaplan DA, Eser P, Yilmazlar S. Dental implant misplacement into the anterior cranial fossae: a unique case and review of literature. *Neurochirurgie.* 2024;70:101533.
  22. Al-Sabbagh M, Okeson JP, Khalaf MW, Bhavsar I. Persistent pain and neurosensory disturbance after dental implant surgery: pathophysiology, etiology, and diagnosis. *Dent Clin North Am.* 2015;59:131-42.
  23. Politis C, Agbaje J, Van Hevele J, Nicolielo L, De Laat A, Lambrechts I, et al. Report of neuropathic pain after dental implant placement: a case series. *Int J Oral Maxillofac Implants.* 2017;32:439-44.
  24. Ribas BR, Nascimento HL, Freitas DQ, dos Anjos PA, dos Anjos ML, Perez DEC, et al. Positioning errors of dental implants and their associations with adjacent structures and anatomical variations: a CBCT-based study. *Imaging Sci Dent.* 2020;50:281-90.
  25. Juodzbalys G, Wang HL, Sabalys G. Injury of the inferior alveolar nerve during implant placement: a literature review. *J Oral Maxillofac Res.* 2011;2:e1.
  26. Peterson LJ, Ellis E, Hupp JR, Tucker MR. *Contemporary Oral and Maxillofacial Surgery.* 4th ed. St. Louis: Mosby; 2003. p. 310-313.

27. Wolff J, Karagozoglu KH, Bretschneider JH, Forouzanfar T, Schulten EA. Altered nasal airflow: an unusual complication following implant surgery in the anterior maxilla. *Int J Implant Dent.* 2016;2:6.
28. Greenstein G, Cavallaro J, Romanos G, Tarnow D. Clinical recommendations for avoiding and managing surgical complications associated with implant dentistry: a review. *J Periodontol.* 2008;79:1317-29.
29. Seghers D, Berkus T, Oelhafen M, Munro P, Star-Lack J. Comparison of state of the art interpolation-based metal artifact reduction (MAR) algorithms for cone beam computed tomography (CBCT). *Med Phys.* 2012;39:3628.
30. Mancini AX, Santos MU, Gaêta-Araujo H, Tirapelli C, Pauwels R., Oliveira-Santos C. Artefacts at different distances from titanium and zirconia implants in cone-beam computed tomography: effect of tube current and metal artefact reduction. *Clin Oral Investig.* 2021;25:5087-94.
31. González-Martín O, Oteo C, Ortega R, Alandez J, Sanz M, Veltri M. Evaluation of peri-implant buccal bone by computed tomography: an experimental study. *Clin Oral Implants Res.* 2016;27:950-5.
32. Fienitz T, Schwarz F, Ritter L, Dreiseidler T, Becker J, Rothamel D. Accuracy of cone beam computed tomography in assessing peri-implant bone defect regeneration: a histologically controlled study in dogs. *Clin Oral Implants Res.* 2012;23:882-7.
33. Hilgenfeld T, Juerchott A, Deisenhofer UK, Krisam J, Rammelsberg P, Heiland S, et al. Accuracy of cone-beam computed tomography, dental magnetic resonance imaging, and intraoral radiography for detecting peri-implant bone defects at single zirconia implants an in vitro study. *Clin Oral Implants Res.* 2018;29:922-30.

# The Effects of Different Restoration Materials on the Trueness of Intraoral Scanners

Mehmet GÖZEN<sup>1\*</sup>  Neslihan GÜNTEKİN<sup>2</sup>  Ceyda AKIN<sup>3</sup> 

<sup>1</sup> PhD student, Necmettin Erbakan University, Faculty of Dentistry, Department of Prosthodontics, Konya, Türkiye, mehmetgzen@gmail.com

<sup>2</sup> Asst. Prof., MD, Necmettin Erbakan University, Faculty of Dentistry, Department of Prosthodontics, Konya, Türkiye, neslihanvarolnv94@gmail.com

<sup>2</sup> Asst. Prof., PhD, Necmettin Erbakan University, Faculty of Dentistry, Department of Prosthodontics, Konya, Türkiye, ceydakin@hotmail.com

## Article Info

### Article History

Received: 17.06.2024

Accepted: 02.09.2024

Published: 15.10.2024

### Keywords:

Accuracy,  
Porcelain,  
Restoration,  
Scanner,  
Zirconia.

## ABSTRACT

**Aim:** This study aimed to assess how different restoration materials affect the trueness of intraoral scanners. **Materials and Methods:** Artificial teeth on a typodont model were prepared for crowns and fixed partial dentures (FPDs) using full metal, monolithic zirconia, and porcelain-fused-to-metal (PFM) materials. Each group underwent 10 scans with a Trios intraoral scanner, generating 60 STL files. A reference scanner created a master model using scanning spray to reduce reflection errors. The STL files were aligned with reverse engineering software for comparison and were analyzed in micrometers ( $\mu\text{m}$ ) using Root Mean Square (RMS) and Mean Distance measurements. The Levene test and two-way ANOVA with Post Hoc analysis were used for statistical evaluation.

**Results:** The RMS deviations for the FPDs were  $77.9 \pm 15.2 \mu\text{m}$  (full metal),  $84.6 \pm 6.9 \mu\text{m}$  (monolithic zirconia), and  $130 \pm 19.7 \mu\text{m}$  (PFM). For the crowns, the RMS values were  $76.9 \pm 6.5 \mu\text{m}$  (metal),  $71 \pm 8.2 \mu\text{m}$  (monolithic zirconia), and  $153 \pm 22.4 \mu\text{m}$  (PFM). The mean distance deviations for the FPDs were  $11.4 \pm 4.8 \mu\text{m}$  (metal),  $11.2 \pm 3.4 \mu\text{m}$  (monolithic zirconia), and  $18.3 \pm 2.6 \mu\text{m}$  (PFM). For the crowns, the mean distances were  $8.6 \pm 3.4 \mu\text{m}$  (metal),  $10.2 \pm 3 \mu\text{m}$  (monolithic zirconia), and  $24.7 \pm 3.3 \mu\text{m}$  (PFM). Significant differences were noted in the PFM groups.

**Conclusion:** Restoration materials notably affected intraoral scanner trueness, especially PFM restorations. The restoration length did not significantly affect the accuracy.

## Farklı Restorasyon Materyallerinin Ağız İçi Tarayıcı Doğruluğuna Etkisi

### Makale Bilgisi

### Makale Geçmişi

Geliş Tarihi: 17.06.2024

Kabul Tarihi: 02.09.2024

Yayın Tarihi: 15.10.2024

### Anahtar Kelimeler:

Doğruluk,  
Porselen,  
Restorasyon,  
Tarayıcı,  
Zirkonya.

### ÖZET

**Amaç:** Bu çalışma, farklı restorasyon malzemelerinin ağız içi tarayıcıların doğruluğunu nasıl etkilediğini değerlendirmiştir.

**Gereç ve Yöntemler:** Bir tipodont model üzerindeki yapay dişler, tam metal, monolitik zirkonya ve metal destekli porselen malzemeleri kullanılarak kron ve sabit bölümlü protez için prepare edildi. Her grup, Trios ağız içi tarayıcı ile on kez tarandı ve toplamda 60 STL dosyası oluşturuldu. Yansımayı azaltmak için tarama spreyi kullanılarak bir referans tarayıcı ile ana model oluşturuldu. STL dosyaları tersine mühendislik yazılımı ile hizalanarak karşılaştırıldı ve mikrometre ( $\mu\text{m}$ ) cinsinden Kök Ortalama Kare (RMS) ve Ortalama Mesafe ölçümleri ile analiz edildi. İstatistiksel değerlendirme için Levene testi ve iki yönlü ANOVA ile Post Hoc analizi kullanıldı.

**Bulgular:** Köprü restorasyonlar için RMS sapmaları metalde  $77,9 \pm 15,2 \mu\text{m}$ , monolitik zirkonyada  $84,6 \pm 6,9 \mu\text{m}$  ve porselende  $130 \pm 19,7 \mu\text{m}$  olarak bulundu. Kronlar için RMS değerleri tam metalde  $76,9 \pm 6,5 \mu\text{m}$ , monolitik zirkonyada  $71 \pm 8,2 \mu\text{m}$  ve porselende  $153 \pm 22,4 \mu\text{m}$  bulundu. Köprü restorasyonlar için Ortalama Mesafe sapmaları metalde  $11,4 \pm 4,8 \mu\text{m}$ , monolitik zirkonyada  $11,2 \pm 3,4 \mu\text{m}$  ve porselende  $18,3 \pm 2,6 \mu\text{m}$  olarak bulundu. Kronlar için Ortalama Mesafe değerleri metalde  $8,6 \pm 3,4 \mu\text{m}$ , monolitik zirkonyada  $10,2 \pm 3 \mu\text{m}$  ve porselende  $24,7 \pm 3,3 \mu\text{m}$  bulundu. Porselen gruplarında anlamlı farklılıklar gözlemlendi.

**Sonuç:** Restorasyon malzemeleri, özellikle metal destekli porselen restorasyonlarında ağız içi tarayıcıların doğruluğunu önemli ölçüde etkilemektedir. Restorasyon uzunluğu, doğruluk üzerinde önemli bir etki göstermemiştir.

**To cite this article:** Gözen M, Güntekin N, Akın C. The Effects of Different Restoration Materials on the Trueness of Intraoral Scanners. NEU Dent J. 2024;6(Special Issue):18-26. <https://doi.org/10.51122/neudentj.2024.111>

\*Corresponding Author: Mehmet GÖZEN, [mehmetgzen@gmail.com](mailto:mehmetgzen@gmail.com)





## **INTRODUCTION**

From the past to the present, various impression materials and impression techniques have been developed for use in the fabrication of dental prostheses. These materials facilitate the accurate transfer of hard and soft tissues from the patient's oral cavity to the laboratory setting. The accuracy and functionality of the restoration depend on the precise replication of the impression in these tissues. The impression must scan the intraoral tissues accurately to produce well-fitting restorations.<sup>1</sup>

The use of digital impressions, which have been increasingly prevalent in recent years, began in dentistry in the 1980s.<sup>2</sup> Digital impressions allow for simultaneous treatment planning, restoration fabrication, previewing of treatment stages, and visually presenting the anticipated treatment outcomes to the patient at the chairside.<sup>3</sup> The increasing practicality, speed, and accuracy of intraoral scanners have contributed to their widespread adoption.<sup>4</sup> However, the accuracy of evolving digital impression systems can vary depending on the intraoral fluids, scanning methods, and surface being scanned.<sup>5</sup>

Two factors influence impression accuracy: trueness and precision. Trueness refers to how closely the impression resembles the actual dimensions of the intraoral environment, while precision denotes the consistency between repeated impressions. High accuracy requires consistent and accurate digital impressions that reflect the intraoral environment.<sup>6</sup>

In the early stages of digital impressions, the use of titanium dioxide powder and similar materials before scanning reduced patient satisfaction. The interaction of the powder with saliva often necessitated reapplication, and excessive accumulation of the powder on the surface led to inaccurate measurements. These issues contributed to

the reluctance of dental professionals to adopt such methods.<sup>7</sup> The purpose of powder-based systems was to ensure that surfaces scanned in the oral environment possessed uniform color and opacity, thereby preventing errors caused by light reflections.<sup>8</sup>

The newly developed dust-free systems offer enhanced comfort for patients and ease of use for dentists.<sup>9</sup> The oral cavity contains restorations made from various materials, such as composite, amalgam, zirconia, and metal crowns, each of which exhibits different light transmission and reflection properties.<sup>10</sup> Intraoral scanners utilize light to capture the oral cavity environment. The Trios system is a scanner equipped with structured light imaging technology, confocal microscopy, and rapid optical scanning capabilities.<sup>11</sup> Confocal microscopy is an optical imaging technique that employs spatial filtering to eliminate light/brightness outside the focal plane, thereby enhancing contrast and generating 3D images.<sup>12</sup>

The properties of scanned surfaces, such as light reflection, refraction, and translucency, significantly influence the path followed by light from the scanner to the sensor.<sup>5</sup> This study aimed to investigate the effect of materials with different surface properties and lengths on the accuracy of teeth prepared using the Trios intraoral scanner. The null hypothesis of the study was that different materials did not affect the accuracy of the intraoral scanner.

## **MATERIAL AND METHODS**

To standardize the scans, a typodont model (Frasaco model, Frasaco, Tettngang, Germany) was divided into two groups: crowns and fixed partial dentures (FPDs). Each group was further divided into three subgroups for the production of restorations (Figure 1). For single crown restorations, the maxillary second molar was prepared. Using a desktop scanner, the following crown

restorations were produced: M1: Metal (Cr-Co), P1: Porcelain fused to metal (Ivoclar Vivadent), Z1: Monolithic zirconia (Aidite 3D Pro Zir). The second molar and second premolar teeth were prepared for the FPDs. The following FPD restorations were produced: M3: metal (Cr-Co); P3: Porcelain fused to metal (Ivoclar Vivadent); and Z3: monolithic zirconia (Aidite 3D Pro Zir). Porcelain crowns and FPDs were glazed, while zirconia and metal restorations

underwent mechanical polishing. The materials used are listed in Table 1.

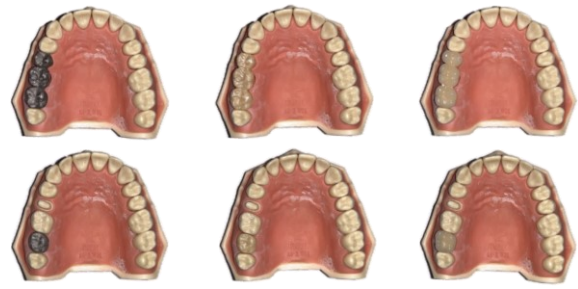

Figure 1: Prepared models with restorations

Table 1: Materials used in the study

Groups	Metal (M)		Monolithic Zirconia (Z)		Porcelain (P)	
Subgroups	Metal Crown (M1)	Metal FPD (M3)	Zirconia Crown (Z1)	Zirconia FPD (Z3)	Porcelain Crown (P1)	Porcelain FPD (P3)
Producer	-	-	Aidite 3D Pro Zir	Aidite 3D Pro Zir	Ivoclar Vivadent	Ivoclar Vivadent
Materials Description	Cr-Co	Cr-Co	Multilayer Monolithic	Multilayer Monolithic	Feldspathic	Feldspathic
Finishing Methods	Polishing	Polishing	Polishing	Polishing	Glazing	Glazing

The designed restorations were cemented into the model using polycarboxylate cement (Carbofine Polycarboxylate, Pentron, SPOFA Dental) to secure them in place. The prepared models were scanned using a reference scanner (SHINING 3D AutoScan-DS-MIX Dental 3D Scanner) to obtain the reference model.

Each group was scanned 10 times using a Trios 3 intraoral scanner system (3Shape, Copenhagen, Denmark), following the manufacturer's recommended scanning method to ensure standardization. All scans were performed by the same operator to maintain consistency. In total, 60 STL files were generated (Figure 2).

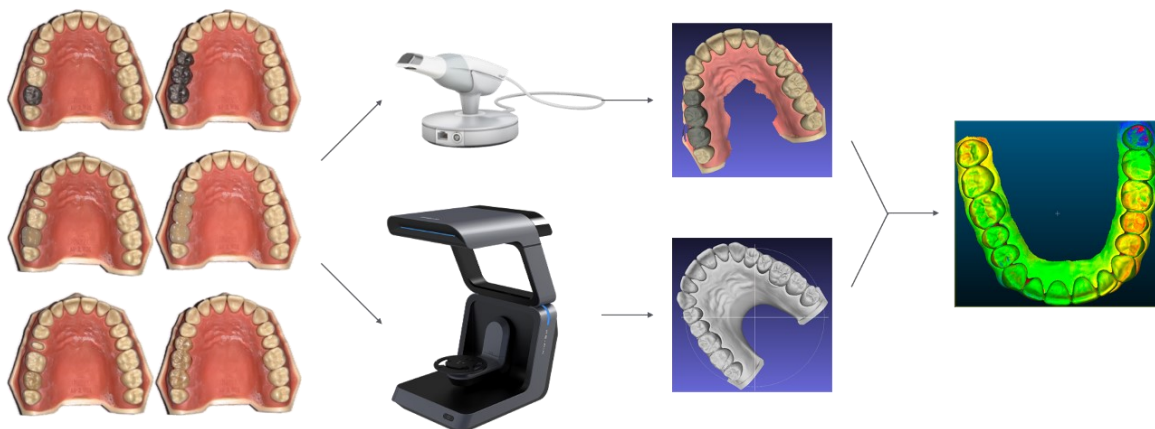

Figure 2: Scanning and analysis process

The obtained STL files were imported into reverse engineering software (CloudCompare v2.13.1 for Mac) and extraneous data points were removed to refine the model. To assess accuracy, the STL

data of the reference model were aligned with the STL data obtained from the intraoral scanner within each group using the best-fitting alignment, followed by a comparison (Figure 2).

The software uses the iterative closest point algorithm for optimal alignment. The color-coded images of the model indicate areas of deviation: blue areas denote negative or inward deviation, and red areas signify positive or outward deviation. The increasing intensity of the color was correlated with the magnitude of the deviation.

Accuracy was quantified as the root mean square (RMS) deviation. When comparing two scans, the squares of the differences in the x, y, and z axes of the points where deviation occurred were calculated. The sum of these squares was divided by the number of points, and the root mean square was determined as the square root of this value. In addition, the average differences between the aligned models were calculated.

### Statistical Analysis

The results were analyzed using a statistical program (IBM SPSS Statistics 29.0.1). Normality of the groups was assessed using the Shapiro-Wilk test, and homogeneity of variances was evaluated using the Levene test. Based on the results, a two-way ANOVA was conducted. The post hoc Tukey test was applied to evaluate the differences between groups.

## RESULTS

The results suggest that the findings of this study are highly intriguing. The presence of homogeneous variances and normally distributed data provides a robust foundation for statistical analysis. The two-way ANOVA revealed significant differences among the groups, with the post hoc Tukey test identifying significant differences between the porcelain group and the other groups. Additionally, it is noted that the length factor alone does not have a significant effect, whereas material does. The interaction between length and material is also significant, indicating that the effect of the material depends on the length. These findings underscore the significant impact of different materials and lengths used in dental restorations on their accuracy.

Tables 2 and 3 present the averages and standard deviations, expressed in micrometers ( $\mu\text{m}$ ), resulting from the examination of the accuracy of six different restorations using the RMS method and the distance difference method. A lower mean value indicates less deviation from the reference, which indicates higher accuracy. An examination of the RMS values revealed that the porcelain crown and porcelain FPD groups exhibited the lowest accuracy, with values of  $153 \pm 22.4 \mu\text{m}$  and  $130 \pm 19.7 \mu\text{m}$ , respectively. Similarly, when examining the distance difference, the same groups had the lowest accuracy values with values of  $24.7 \pm 3.3 \mu\text{m}$  and  $18.3 \pm 2.6 \mu\text{m}$ , respectively. Different lowercase letters indicate significant differences between groups ( $p < 0.05$ ). Table 4 illustrates the mean differences between the restoration groups according to the RMS method, and Table 5 shows the mean differences according to the distance difference method.

**Table 2:** Rms values

Material	Restoration	N	RMS ( $\mu\text{m}$ )	Standard Deviation ( $\mu\text{m}$ )
Metal	Crown	10	76.9 <sup>a</sup>	6.5
	FPD	10	77.9 <sup>a</sup>	15.2
Porcelain	Crown	10	153 <sup>b</sup>	22.4
	FPD	10	130 <sup>c</sup>	19.7
Zirconia	Crown	10	71 <sup>a</sup>	8.2
	FPD	10	84.6 <sup>a</sup>	6.9

( $p < 0.05$ , different lowercase letters exhibited significant differences. FPD: Fixed partial denture. Mean and standard deviation of the RMS values obtained from the analysis of the groups)

**Table 3:** Mean distances

Material	Restoration	N	RMS ( $\mu\text{m}$ )	Standard Deviation ( $\mu\text{m}$ )
Metal	Crown	10	8.6 <sup>a</sup>	3.4
	FPD	10	11.4 <sup>a</sup>	4.8
Porcelain	Crown	10	24.7 <sup>b</sup>	3.3
	FPD	10	18.3 <sup>c</sup>	2.6
Zirconia	Crown	10	10.2 <sup>a</sup>	3
	FPD	10	11.2 <sup>a</sup>	2.4

( $p < 0.05$ , different lowercase letters exhibited significant differences. FPD: Fixed partial denture. Mean and standard deviation of the distance differences obtained from the analysis of the groups)

**Table 4:** Comparison of RMS

Material		Mean Difference	P-Adj	Lower	Upper
M3	P3	0.053	P<0.001	0.0326	0.0733
M3	M1	-0.001	P>0.05	-0.0214	0.0194
M3	P1	0.0752	P<0.001	0.0548	0.0956
M3	Z1	-0.007	P>0.05	-0.0274	0.0134
M3	Z3	0.0067	P>0.05	-0.0137	0.027
P3	M1	-0.054	P<0.001	-0.0744	-0.0336
P3	P1	0.0222	P<0.05	0.0018	0.0426
P3	Z1	-0.06	P<0.001	-0.0803	-0.0396
P3	Z3	-0.0463	P<0.001	-0.0667	-0.0259
M1	P1	0.0762	P<0.001	0.0558	0.0966
M1	Z1	-0.006	P>0.05	-0.0264	0.0144
M1	Z3	0.0077	P>0.05	-0.0127	0.0281
P1	Z1	-0.0822	P<0.001	-0.1026	-0.0618
P1	Z3	-0.0685	P<0.001	-0.0889	-0.0481
Z1	Z3	0.0137	P>0.05	-0.0067	0.034

(M1: Metal crown, Z1: Zirconia crown, P1: Porcelain crown, M3: Metal fixed partial denture, Z3: Zirconia fixed partial denture, P3: Porcelain fixed partial denture. Mean difference, p-value, and upper and lower values obtained from the comparison of RMS between groups)

**Table 5:** Comparison of mean distances

Material		Mean Difference	P-Adj	Lower	Upper
M3	P3	0.0069	<0.05	0.0019	0.0118
M3	M1	-0.0028	>0.05	-0.0077	0.0021
M3	P1	0.0133	<0.001	0.0084	0.0183
M3	Z1	-0.0012	>0.05	-0.0062	0.0037
M3	Z3	-0.0002	>0.05	-0.0052	0.0047
P3	M1	-0.0097	<0.001	-0.0146	-0.0048
P3	P1	0.0064	<0.05	0.0015	0.0114
P3	Z1	-0.0081	<0.05	-0.013	-0.0032
P3	Z3	-0.0071	<0.05	-0.012	-0.0022
M1	P1	0.0161	<0.001	0.0112	0.0211
M1	Z1	0.0016	>0.05	-0.0033	0.0065
M1	Z3	0.0026	>0.05	-0.0024	0.0075
P1	Z1	-0.0145	<0.001	-0.0195	-0.0096
P1	Z3	-0.0135	<0.001	-0.0185	-0.0086
Z1	Z3	0.001	>0.05	-0.0039	0.0059

(M1: Metal crown, Z1: Zirconia crown, P1: Porcelain crown, M3: Metal fixed partial denture, Z3: Zirconia fixed partial denture, P3: Porcelain fixed partial denture. Mean difference, p-value, and upper and lower values obtained from the comparison of distance differences between groups)

In the two-way ANOVA, the p-value for the crown FPD factor was 0.53, indicating no significant difference between restoration lengths. The p-value for material factor was approximately <0.0001, indicating a

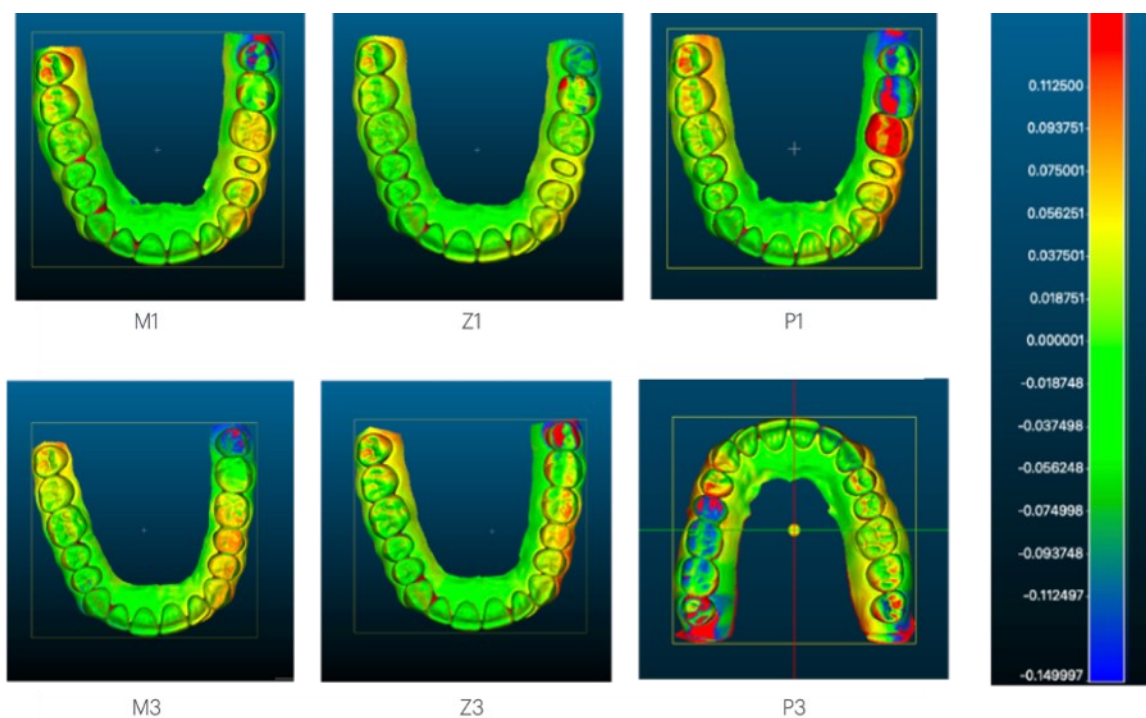
significant difference between the material types. The p-value for the interaction between restoration length and material factor was 0.002, suggesting a significant interaction between restoration length and material

factors. Thus, while restoration length alone is not a significant factor, it can influence the results depending on the material. Post hoc analysis revealed significant differences between the porcelain and other groups.

### Color Analysis

Figure 3 shows deviations resulting

from the overlay of metal crowns, porcelain crowns, zirconia crowns, metal FPD, porcelain FPD, and zirconia FPD on a color map. Red and blue colors indicate positive and negative deviations, respectively. While all groups exhibited deviations in the restoration area, the porcelain crown group exceeds the value of 150  $\mu\text{m}$ .



**Figure 3:** Color map obtained by overlaying STL data using reverse engineering software.

(M1: Metal crown, Z1: Zirconia crown, P1: Porcelain crown, M3: Metal fixed partial denture, Z3: Zirconia fixed partial denture, P3: Porcelain fixed partial denture. Red areas indicate negative deviations more than -150  $\mu\text{m}$ , blue areas indicate positive deviations greater than 150  $\mu\text{m}$ )

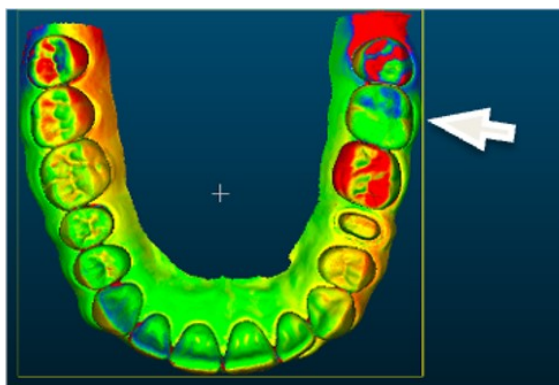
### DISCUSSION

This study aimed to examine the effects of different restoration materials and restoration lengths on digital measurement accuracy. With the increasing use of digital impressions, it is conceivable that traditional model usage can be eliminated.<sup>13</sup> However, several studies have reported that digital impressions do not exhibit as high accuracy as traditional impression materials, such as polyvinyl siloxane (PVS), particularly in full-arch scans, although this difference is relatively small.<sup>14</sup> Based on the results of the study, the null hypothesis positing no significant difference between different material types and restoration lengths was rejected.

The primary objective was to determine whether the accuracy of a dust-free intraoral scanner is contingent on surfaces with distinct light reflection properties and whether it can adequately scan different materials. The M and Z groups underwent mechanical polishing, whereas the P group underwent a glazing process. The augmented deviation observed in the P group is attributed to the heightened light reflection associated with glazed porcelain.

The absence of a significant difference between the M and Z groups, despite uniform material colors in the P and Z groups (A2), suggests that the scanner accuracy is primarily contingent on the optical characteristics of the material surface rather than the restoration color.

Optical systems generate digital images by capturing light emitted from surfaces. However, light reflection and scattering from surrounding objects, particularly from shiny surfaces, can generate significant reflections. For instance, a porcelain crown proximate to adjacent teeth may prompt the scanner to detect reflected light, leading to inaccurate results (Figure 4). Moreover, the reduced exposure of restoration to light during intraoral scanning, compared with intraoral scanning within the mouth, may contribute to reflections on the surface of the P group during model scanning under ambient light conditions.



**Figure 4:** Effects of porcelain crowns on adjacent teeth.

The increased deviation observed in the porcelain crown group compared with the porcelain FPD group may be explained by the uneven application of powder used to reduce reflections during scanning with the reference scanner. This warrants further investigation in future studies.

Surface deviation, particularly distal to the arch and adjacent to the restoration, suggests that reflections from adjacent teeth, due to their optical properties, may exert a greater influence on adjacent tooth scans than the restoration itself. (Figure 3)

In a study by Kurz at all., it was proposed that keeping the scanner head perpendicular to the surface can reduce the reflections associated with restorations. However, maintaining the scanner head consistently perpendicular during surface

scanning of teeth may not be feasible in practice.<sup>15</sup>

In another study conducted by Bocklet at all., the accuracy of dentin, amalgam, and composite materials was investigated using scans from a cadaver maxilla model. Similarly, reflections also occurred depending on the surface optical properties examined in this study.<sup>5</sup>

The following scanning, optical systems may encounter imaging errors during the image processing phase, potentially leading to misinterpretation of acquired data or modeling errors. The scanning method performed by Trios utilizing confocal microscopy with a light source may increase the susceptibility of surface optical properties. Future studies should explore different scanners utilizing various scanning methods with materials exhibiting diverse optical properties.<sup>2</sup>

One of the limitations of the study is its execution on a typodont model, which precludes the simulation of patient-related factors such as limited mouth opening, saliva, and blood. Additionally, typodont teeth lack properties comparable to those of natural tooth tissues. The repeated nearest point algorithm was preferred for overlaying scans, as in previous studies.<sup>16,17</sup> However, different superimposition algorithms are available, which could affect the results.<sup>17</sup>

## CONCLUSION

Within the limitations of the study, the following conclusions were drawn:

The accuracy of the scanner can be affected by reflections coming from the restorations.

Deviations occurring in groups other than the porcelain group is within clinically acceptable limits.

## Ethical Approval

This in-vitro study does not require ethics committee approval.

### Financial Support

The authors declare that this study received no financial support.

### Conflict of Interest

The authors deny any conflicts of interest related to this study.

### Author Contributions

Design: MG, NG, Data collection: MG, NG, Analysis and interpretation: NG, CA, Literature review: MG, CA, Writing: MG, NG.

### REFERENCES

1. Chandran DT, Jagger DC, Jagger RG, Barbour ME. Two- and three-dimensional accuracy of dental impression materials: Effects of storage time and moisture contamination. *Biomed Mater Eng.* 2010;20:243-9.
2. Ahlholm P, Sipilä K, Vallittu P, Jakonen M, Kotiranta U. Digital versus conventional impressions in fixed prosthodontics: A review. *J Prosthodont.* 2018;27:35-41.
3. Strub JR, Rekow ED, Witkowski S. Computer-aided design and fabrication of dental restorations: Current systems and future possibilities. *J Am Dent Assoc.* 2006;137:1289-96.
4. Andriessen FS, Rijkens DR, Van Der Meer WJ, Wismeijer DW. Applicability and accuracy of an intraoral scanner for scanning multiple implants in edentulous mandibles: A pilot study. *J Prosthet Dent.* 2014;111:186-94.
5. Bocklet C, Renne W, Mennito A, Bacro T, Latham J, Evans Z, et al. Effect of scan substrates on accuracy of 7 intraoral digital impression systems using human maxilla model. *Orthod Craniofac Res.* 2019;22:168-74.
6. ISO 5725-1. Accuracy (trueness and precision) of measurement methods and results - Part 1: General principles and definitions. 2023.
7. Meyer BJ, Mörmann WH, Lutz F. Optimization of the powder application in the Cerec method with environment-friendly propellant systems. *Schweiz Monatsschr Zahnmed.* 1990;100:1462-8.
8. Kim SY, Kim MJ, Han JS, Yeo IS, Lim YJ, Kwon HB. Accuracy of dies captured by an intraoral digital impression system using parallel confocal imaging. *Int J Prosthodont.* 2013;26:161-3.
9. Wiedhahn K, Schenk O, Fritzsche G. Cerec Omnicam - Intraoralscan 2.0. *Int J Comput Dent.* 2012;15:199-205.
10. Ahmad I. Three-dimensional shade analysis: perspectives of color-Part I. *Pract Periodontics Aesthet Dent.* 1999;11:789-96.
11. Mangano FG, Hauschild U, Veronesi G, Imburgia M, Mangano C, Admakin O. Trueness and precision of 5 intraoral scanners in the impressions of single and multiple implants: a comparative in vitro study. *BMC Oral Health.* 2019;19:101.
12. Paddock SW. Principles and practices of laser scanning confocal microscopy. *Mol Biotechnol.* 2000;16:127-49.
13. Ender A, Mehl A. In-vitro evaluation of the accuracy of conventional and digital methods of obtaining full-arch dental impressions. *Quintessence Int.* 2015;46:9-17.
14. Ender A, Mehl A. Accuracy of complete-arch dental impressions: A new method of measuring trueness and precision. *J Prosthet Dent.* 2013;109:121-8.
15. Kurz M, Attin T, Mehl A. Influence of material surface on the scanning error

- of a powder-free 3D measuring system. *Clin Oral Investig.* 2015;19:2035-43.
16. Flügge T, van der Meer WJ, Gonzalez BG, Vach K, Wismeijer D, Wang P. The accuracy of different dental impression techniques for implant-supported dental prostheses: A systematic review and meta-analysis. *Clin Oral Implants Res.* 2018;29:374-92.
  17. Di Fiore A, Meneghello R, Graiff L, Savio G, Vigolo P, Monaco C, et al. Full arch digital scanning systems performances for implant-supported fixed dental prostheses: a comparative study of 8 intraoral scanners. *J Prosthodont Res.* 2019;63:396-403.
  18. Schimmel M, Akino N, Srinivasan M, Wittneben JG, Yilmaz B, Abou-Ayash S. Accuracy of intraoral scanning in completely and partially edentulous maxillary and mandibular jaws: an in vitro analysis. *Clin Oral Investig.* 2021;25:1839-47.



# Assessment of the Radiopacity of Different Fissure Sealants Compared to Dental Hard Tissues

Peris CELIKEL<sup>1\*</sup>  Aybike BAS<sup>2</sup>  Fatih SENGUL<sup>3</sup>  Sera DERELIOGLU SIMSEK<sup>4</sup> 

<sup>1</sup> Asst. Prof., Ataturk University Faculty of Dentistry Department of Pediatric Dentistry, Erzurum, Türkiye, celikelperis@gmail.com

<sup>2</sup> Asst. Prof., Ataturk University Faculty of Dentistry Department of Pediatric Dentistry, Erzurum, Türkiye, aybkbas@gmail.com

<sup>3</sup> Assoc. Prof., Ataturk University Faculty of Dentistry Department of Pediatric Dentistry, Erzurum, Türkiye, fatihsg@gmail.com

<sup>4</sup> Prof., Ataturk University Faculty of Dentistry Department of Pediatric Dentistry, Erzurum, Türkiye, simseksera@gmail.com

## Article Info

### Article History

Received: 23.06.2024

Accepted: 03.09.2024

Published: 15.10.2024

### Keywords:

Aluminum Step Wedge,  
Digital Dental Radiography,  
Fissure Sealant,  
Radiopacity.

## ABSTRACT

**Aim:** The radiopacity of dental materials is crucial for assessing the radiographic success of restorations and can significantly influence clinicians' choice of materials. The objective of our study is to compare the radiopacity of five fissure sealants with that of compomer, composite, glass ionomer filling, and dental hard tissues using digital imaging techniques.

**Material and Method:** Five different fissure sealants (Fuji Triage, BeautiSealant, Grandio Seal, Heliaseal F Plus, Embrace Wetbond), compomer (Compoglass F), composite (Solare X), and glass ionomer filling (Equa Forte) materials were prepared as 5 samples each in disk form with a thickness of 2 mm. As controls, sections of primary and permanent teeth with a thickness of 2 mm, along with an aluminum step wedge were utilized. The mean gray values of the samples were measured using Image J software, and the equivalent aluminum thickness was subsequently determined. Statistics analysis using Kruskal-Wallis test at  $p<0.05$ .

**Results:** The equivalent aluminum thicknesses related to the radiopacity of fissure sealants are ranked as follows: Fuji Triage ( $5.2\pm 0.2$ ) > Grandio Seal ( $3.9\pm 0.2$ ) = permanent tooth enamel ( $3.7\pm 0.2$ ) = Embrace Wetbond ( $3.6\pm 0.6$ ) = primary tooth enamel ( $3.6\pm 0.3$ ) = BeautiSealant ( $2.1\pm 0.3$ ) > Heliaseal F Plus ( $1.1\pm 0$ ) ( $p<0.05$ ). The radiopacity equivalent aluminum thicknesses of restorative materials are ranked as follows: Compoglass F ( $7.3\pm 0.4$ ) > Solare X ( $4.7\pm 0.3$ ) = Equa Forte ( $4.4\pm 0.4$ ) = permanent tooth enamel ( $3.7\pm 0.2$ ) = primary tooth enamel ( $3.6\pm 0.3$ ) ( $p<0.05$ ).

**Conclusion:** Materials like Fuji Triage and Compoglass F exhibit high radiopacity values, which can significantly aid clinical monitoring and restoration success.

## Farklı Fissür Örtücülerin Diş Sert Dokularına Kıyasla Radyoapasitelerinin Değerlendirmesi

### Makale Bilgisi

#### Makale Geçmişi

Geliş Tarihi: 23.06.2024

Kabul Tarihi: 03.09.2024

Yayın Tarihi: 15.10.2024

#### Anahtar Kelimeler:

Alüminyum kademeli kama,  
Dental dijital radyografi,  
Fissür örtücü,  
Radyoapasite.

### ÖZET

**Amaç:** Dental materyallerin radyoapasitesi yapılan restorasyonların radyografik başarısının belirlenmesinde rol oynamakta ve hekimlerin malzeme seçimini etkileyebilmektedir. Çalışmamızın amacı beş farklı fissür örtücünün kompozit, kompozit, cam iyonomer dolgu ve diş sert dokularına göre radyoapasitesinin dijital tekniklerle karşılaştırılmasıdır.

**Materyal ve Metod:** Beş farklı fissür örtücü (Fuji Triage, BeautiSealant, Grandio Seal, Heliaseal F Plus, Embrace Wetbond), kompozit (Compoglass F), kompozit (Solare X) ve cam iyonomer dolgu (Equa Forte) materyallerinden 2 mm kalınlığında 5'er adet disk şeklinde örnekler hazırlandı. Kontrol olarak 2 mm kalınlığındaki süt ve daimi diş kesitleri ve alüminyum kademeli kama kullanıldı. Örneklerin ortalama gri değerleri Image J yazılımı kullanılarak ölçüldü ve eşdeğer alüminyum kalınlığı belirlendi. Veriler Kruskal-Wallis testi kullanılarak analiz edildi ( $p<0,05$ ).

**Bulgular:** Fissür örtücülerin radyoapasitesine ait eşdeğer alüminyum kalınlıkları Fuji Triage ( $5,2\pm 0,2$ ) > Grandio Seal ( $3,9\pm 0,2$ ) = daimi diş minesi ( $3,7\pm 0,2$ ) = Embrace Wetbond ( $3,6\pm 0,6$ ) = süt dişi minesi ( $3,6\pm 0,3$ ) = BeautiSealant ( $2,1\pm 0,3$ ) > Heliaseal F Plus ( $1,1\pm 0$ ) şeklinde sıralanmışlardır ( $p<0,05$ ). Restoratif materyal radyoapasitesine ait eşdeğer alüminyum kalınlıkları ise Compoglass F ( $7,3\pm 0,4$ ) > Solare X ( $4,7\pm 0,3$ ) = Equa Forte ( $4,4\pm 0,4$ ) = daimi diş minesi ( $3,7\pm 0,2$ ) = süt dişi minesi ( $3,6\pm 0,3$ ) şeklinde sıralanmıştır ( $p<0,05$ ).

**Sonuç:** Fuji Triage ve Compoglass F gibi materyaller yüksek radyoapasite değerleri sergilemekte olup, bu özellikleri klinik takip ve restorasyon başarısında önemlidir.

**To cite this article:** Celikel P, Bas A, Sengul F, Derelioglu-Simsek S. Assessment of the Radiopacity of Different Fissure Sealants Compared to Dental Hard Tissues. NEU Dent J. 2024;6(Special Issue):27-35.  
<https://doi.org/10.51122/neudentj.2024.112>

\*Corresponding Author: Peris CELIKEL, [celikelperis@gmail.com](mailto:celikelperis@gmail.com)



This article is licensed under a Creative Commons Attribution-NonCommercial 4.0 International License (CC BY-NC 4.0)

## **INTRODUCTION**

Preventive dentistry practices have become increasingly important today. These practices encompass various treatments and procedures aimed at maintaining dental health and preventing oral health problems. One of the preventive dentistry procedures frequently applied in clinical routines is fissure sealant application. This procedure is designed to protect potential decay-prone areas on the occlusal surfaces of teeth.<sup>1,2</sup> There are various types of fissure sealants available on the market, categorized by their composition: glass ionomer cement-based, resin-based, polyacid-modified composite resin-based, ormocer-based, giomer-based, and glass carbomer-based.<sup>3</sup> An ideal fissure sealant should hermetically seal pits and fissures, be easy to apply, remain in place for a long time after application, possess thermal and mechanical properties similar to those of enamel, and exhibit appropriate radiopacity.<sup>4</sup>

Appropriate radiopacity is crucial for the long-term follow-up of restorative materials used in dentistry and the success of restorations.<sup>5</sup> Due to the proper radiopacity of dental materials, secondary caries, marginal discrepancies, and faulty proximal contacts between restorations and enamel or dentin can be accurately and easily diagnosed radiographically.<sup>6,7</sup> Materials with either low or excessively high radiopacity can lead to misdiagnosis. For instance, materials with high radiopacity may obscure caries beneath restorations on radiographs.<sup>8</sup> Therefore, the radiopacity level of dental restorative materials should be within a range that allows for clear differentiation from the restored tooth structure.<sup>9</sup>

Secondary caries is one of the primary reasons for replacing restorations.<sup>10</sup> To identify secondary caries beneath restorations radiographically, dental restorative materials must exhibit optimal radiopacity.<sup>11</sup> Therefore, the radiopacity of these materials is a crucial for dentists in preventing failures during postoperative follow-up. Additionally, if dental

materials are inadvertently aspirated or swallowed during clinical procedures, their radiopacity becomes essential for accurately locating them.<sup>12</sup>

The radiopacity of dental materials is assessed by comparing their optical density values or equivalent aluminum thickness (measured in millimeters) with those of enamel, dentin, and known aluminum thickness using a reference calibration curve on digital radiographs.<sup>13,14</sup> According to ISO 4049:2019, dental restorative materials designed for use in the crown of a tooth should exhibit a radiopacity equal to or greater than that of aluminum (Al), which is reported to be similar to the radiopacity of dentin when both are of comparable thickness ( $\geq 98\%$  purity).<sup>15</sup>

The literature contains numerous studies exploring the radiopacity values of various restorative materials.<sup>10,11,16</sup> However, to the best of our knowledge, there are no studies that specifically investigate the radiopacity of the fissure sealants utilized in our research. Based on this, our study aimed to compare the radiopacities of fissure sealants, which are frequently used in preventive applications in pediatric dentistry, with those of dental hard tissues and other restorative materials commonly used in clinical practice, utilizing digital techniques compared to dental hard tissues and other restorative materials used in the clinical routine with the digital technique. The null hypothesis of this study posits that there is no significant difference in the radiopacity values of the materials used, measured in terms of aluminum thickness (mm).

## **MATERIAL AND METHODS**

The protocol for this study was approved by the Ethics Committee of Atatürk University Medical Faculty in accordance with the Helsinki Declaration (Approval Number: 29 March 2024-2/30). The materials tested in this study were presented in Table 1. Five different fissure sealants were used: Fuji Triage (GC, Tokyo, Japan), BeautiSealant (Shofu, Tokyo,

Japan), Grandio Seal (Voco, Cuxhaven, Germany), Helioseal F Plus (Ivoclar Vivadent, Schaan, Liechtenstein), Embrace Wetbond (Pulpdent, Watertown, USA). Additionally, a compomer (Compoglass F (Ivoclar Vivadent, Schaan, Liechtenstein)), composite (Solare X (GC, SouthEast Asia)) and glass ionomer filling (Equa Forte (GC, America)) materials were also used in the study.

**Table 1.** Type, composition and manufacturers of the materials used in the study

Material	Type	Composition	Manufacturer
<b>Fuji Triage</b>	Fissur Sealant	Fluoro aluminium silicate glass, polyacrylic acid, polybasic carboxylic acid.	GC (Tokyo, Japan)
<b>BeautiSealant</b>	Fissur Sealant	UDMA, TEGDMA, surface pre-reacted glass-ionomer filled fluoroboroaluminum silicate glass, micro silica	Shofu (Tokyo, Japan)
<b>Grandio Seal</b>	Fissur Sealant	70% inorganic fillers in a methacrylate matrix (Bis-GMA, TEGDMA).	Voco (Cuxhaven, Germany)
<b>Helioseal F Plus</b>	Fissur Sealant	Dimethacrylate	Ivoclar Vivadent, (Schaan, Liechtenstein)
<b>Embrace Wetbond</b>	Fissur Sealant	Acrylate ester monomers in two-part, glass-filled	Pulpdent (Watertown, USA)
<b>Compoglass F</b>	Compo mer	Aluminium fluorosilicate glass and ytterbium trifluoride	Ivoclar Vivadent, (Schaan, Liechtenstein)
<b>Solare X</b>	Compos ite	Glass fillers, lanthanoid fluoride nanoparticles	GC (SouthEast Asia)
<b>Equa Forte</b>	Glass-ionome r filling	Fluoro-alumino-silicate glass, polyacrylic acid, pigment	GC (America)

The cylindrical teflon molds used in the study for the restorative materials were 2 mm in height with an inner diameter of 8 mm. The manufacturer's instructions were followed to fabricate five specimens of each material. To prevent the formation of an oxygen inhibition layer, Mylar strips were placed on both sides of the specimens after the materials were poured into the molds. Subsequently, the two surfaces of the specimens were polymerized for 20 seconds using an LED light source (Valo Cordless, Ultradent, USA). The samples were then immersed in deionized water and incubated for 24 hours at 37°C.

Using an Isomet Low-Speed Saw 1000 (Buehler, Lake Bluff, IL, USA), sections of a caries-free human third molar removed for orthodontic purposes and a caries-free human third molar nearing natural exfoliation were cut into 2 mm thick sections to obtain enamel and dentin samples as control specimens. The tooth samples were stored in distilled water until they were radiographically evaluated. A digital caliper (Absolute Digimatic; Mitutoyo, Japan) was used to measure the thickness of all specimens, including tooth slices and enamel. To compare the radiopacity of the materials, a reference was employed: a pure aluminum step wedge with incremental thickness in each layer. Specifically, a 100 mm long, 10 mm wide step wedge made of 99.5% pure aluminum was used, starting at 1 mm thickness and increasing by 1 mm increments.

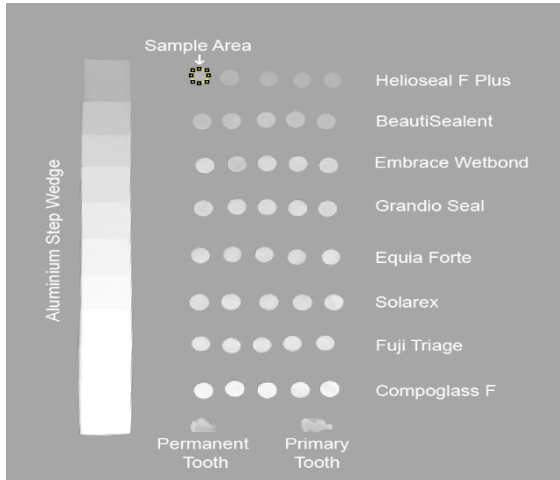
### Radiographic procedure

After all specimens were fixed on a cardboard, radiographs were taken using the lateral cephalometric film of a panoramic radiography device (Planmeca ProMax, Finland) (76 kV, 16 mA, 0.4 s).

### Measurement of radiopacity value

Using Image J software (National Institutes of Health, Maryland, USA), the mean gray values (MGV) of dentin, enamel, and disc-shaped restorative materials, as well as aluminum stepped wedge, were measured from

digital radiography. Five samples of each material were measured, and their mean gray values were averaged (Figure 1). The optical density values (ODV) ranging from 0 to 255 were measured using the software's Intensity Measurement tool. All measurements were conducted by the same individual (FS).



**Figure 1.** Radiographic images of 2 mm thick tooth sections, dental restorative materials, and aluminum step wedge.

Based on the optical gray density (OGD) readings, the radiopacity values of all investigated materials were converted to millimeter aluminum equivalent (mm Al). To do this, the radiopacity value was determined on the radiograph at each step of the aluminum step wedge, and the mm Al data were acquired by applying the subsequent calculation.<sup>17</sup>

$$\frac{X \times 0.5}{Y} + mm$$

*Al below materials mean gray value.*

X = Mean gray value of the material–mean gray value of the step-wedge increment immediately below the material’s mean gray value.

Y = Mean gray value of the step-wedge increment immediately above the material’s mean gray value–mean gray value of the step-wedge increment immediately below the material’s mean gray value.

0.5 = Increment thickness of the step-wedge

### Statistical analysis

Prism 9 (GraphPad Software, LLC, USD) was used for statistical analysis. The Kruskal-Wallis test and Dunn's multiple comparison test were applied in the statistical study. A significance level of  $p < 0.05$  was used to determine statistical significance.

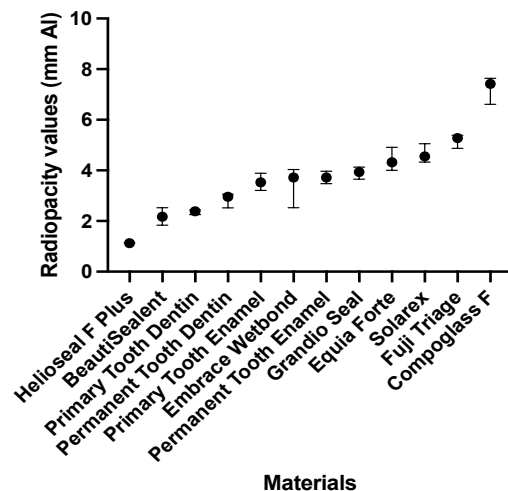
### RESULTS

The mean and standard deviations of the radiopacity values of different dental restorative material, enamel, as well as enamel and dentin samples in terms of aluminum thickness (mm) were presented in Table 2 and Figure 2.

**Table 2.** Radiopacity values (mean ± standard deviation) of the dental restorative materials used in the study

Group	Mean and SD
Helioseal F Plus	1.1±0 <sup>a</sup>
BeautiSealant	2.1±0.3 <sup>ab</sup>
Primary tooth dentin	2.4±0.1 <sup>ab</sup>
Permanent Tooth Dentin	2.9±0.2 <sup>abc</sup>
Primary Tooth Enamel	3.6±0.3 <sup>bcd</sup>
Embrace Wetbond	3.6±0.6 <sup>bcd</sup>
Permanent Tooth Enamel	3.7±0.2 <sup>bcd</sup>
Grandio Seal	3.9±0.2 <sup>cde</sup>
Equia Forte	4.4±0.4 <sup>def</sup>
Solarex	4.7±0.3 <sup>def</sup>
Fuji Triage	5.2±0.2 <sup>ef</sup>
Compoglass F	7.3±0.4 <sup>f</sup>

SD.: Standart deviation, \*The difference between the materials with different letters in the same column is statistically significant ( $p < 0.05$ ).



**Figure 2.** Graph of radiopacity values of materials in terms of aluminum thickness (mm)

The radiopacity values of the materials from largest to smallest are as follows: Compoglass F ( $7.3 \pm 0.4$  mm Al), Fuji Triage ( $5.2 \pm 0.2$  mm Al), Solare X ( $4.7 \pm 0.3$  mm Al), Equia Forte ( $4.4 \pm 0.4$  mm Al), Embrace Wetbond ( $3.6 \pm 0.6$  mm Al), BeautiSealant ( $2.1 \pm 0.3$  mm Al), and Helioseal F Plus ( $1.1 \pm 0$  mm Al).

Compoglass F and Fuji Triage materials exhibited higher radiopacity values than permanent and primary enamel and dentin ( $p < 0.05$ ). Helioseal F Plus material had lower radiopacity values than primary and permanent tooth enamel ( $p < 0.05$ ).

## **DISCUSSION**

The radiopacity of dental restorative materials is a crucial property that affects their ability to resist X-rays and their visibility on radiographs. Ensuring sufficient contrast between the restorative material and enamel/dentin is essential for clinical applications, such as identifying improper proximal contours, mismatched marginal edges, and detecting secondary caries.<sup>18,19</sup> Therefore, to ensure proper treatment and clinical follow-up, it is important that restorative materials have appropriate radiopacity, and the radiopacity of all materials used in clinical practice should be thoroughly evaluated.<sup>15</sup>

Based on this information, our study evaluated the radiopacities of different fissure sealants. The results revealed that when comparing the equivalent aluminum thicknesses representing the radiopacity of the fissure sealants, Fuji Triage exhibited higher radiopacity, Grandio Seal, Embrace Wetbond and BeautiSealant demonstrated similar radiopacity. In contrast, Helioseal F Plus showed lower radiopacity compared to both permanent and primary tooth enamel. Therefore, the null hypothesis was rejected. To our knowledge, this study is the first in the literature to compare the radiopacity of various fissure sealants using digital techniques.

It is recommended that the radiopacity of dental restorative materials be compared with pure aluminum and should have similar or greater radiopacity than pure aluminum or dentin of the same thickness because According to ISO 4049 standards, the radiopacity of pure aluminum (99.5%) closely approximates that of human dental dentin.<sup>20,21</sup> Several studies have indicated that to effectively identify secondary caries and defective restorations beneath restorative materials, the radiopacity of these materials should be at least as high as that of enamel tissue.<sup>6,22</sup> The present study, we found that the radiopacity of all materials, except for Helioseal F Plus, was comparable to that of primary and permanent tooth enamel. Based on these findings, it can be concluded that with the exception of Helioseal F Plus, the materials evaluated in our study allow for the radiographic detection of secondary caries and faulty restorations beneath the restorations with the exception of Helioseal F Plus, the materials evaluated in our study allow for the radiographic detection of secondary caries and faulty restorations beneath the restorations.

It has been reported that the level of radiopacity in dental restorative materials is crucial and should be determined according to the specific restorative purpose for which the material is intended.<sup>9,23</sup> Based on this, various dental materials commonly used in the clinical practice, such as composite, glass ionomer fillings, base materials and root canal materials, exhibit different radiopacity values. In a study by Kuter et al.,<sup>24</sup> which evaluated the radiopacity of restorative materials used in pediatric dentistry (including composite, compomer, and glass ionomer cement), it was reported that the posterior composite material had the highest radiopacity values. In another study conducted by Pekkan et al.,<sup>16</sup> it was reported that glass ionomer cements have low radiopacity and should therefore be used with caution in restorative procedures. In our study, the radiopacity of fissure sealants and various

restorative materials was evaluated in comparison to enamel and dentin. In the present study, Solare X and Equia Forte exhibited higher radiopacity than dentin, while Fuji Triage and Compoglass showed higher radiopacity than both enamel and dentin. It was also reported that Solare composite had higher radiopacity than dentin, consistent with our results.<sup>25</sup> Additionally, similar studies in the literature report that Equia Forte and Compoglass materials have higher radiopacity than enamel and dentin.<sup>26-29</sup>

It has been reported that glass particles increase the radiopacity of dental materials.<sup>30</sup> This can be explained by the fact that among the materials in our investigation, glass-containing compounds showed the highest radiopacity. Specifically, Compoglass F and Fuji Triage, both of which contain glass, were observed to have the highest radiopacity values among the materials we investigated. Additionally, fissure sealants such as Grandio Seal, Embrace Wetbond, and BeautiSealant exhibit moderate radiopacity due to the relatively small amount of glass fillers they contain within their resin matrices compared to composite materials. On the other hand, the low radiopacity of the Helioseal F Plus fissure sealant may be attributed to its dimethacrylate-based resin structure, which lacks additional radiopaque filler materials.<sup>31</sup>

Upon reviewing the literature, it has been reported that various factors influence the radiopacity of dental restorative materials.<sup>16</sup> These factors include the X-ray beam angle, the distance from the film source, the type of aluminum step wedge, the thickness of the material, its chemical composition, and particle size.<sup>32-34</sup> The difference in radiopacity observed among the materials in our study are likely attributable to variations in their chemical composition.

In this study, a digital radiography system, which provides reliable quantitative data analysis, was used to determine the

radiopacity values of the materials.<sup>18</sup> Digital systems offer several advantages over traditional methods, including reduced radiation exposure for both the operator and the patient, instant imaging, and the ability to automatically save images to a computer without the need for chemical processing. They reduce radiation exposure for both the operator and the patient, provide instant imaging, and automatically save images to a computer without the need for chemical processing. Additionally, compared to conventional films, digital systems provide higher resolution and a broader range of imaging options, which facilitating easier interpretation of the images. The most significant advantage of digital systems is their ability to standardize repeat radiographic images.<sup>35-37</sup> In digital radiographs, the smallest component of the digital image is pixels. The radiopacity of a material can be assessed by measuring the gray values at specific pixel coordinates using software, which assigns values on a scale from 0 to 255.<sup>38</sup> ImageJ software was utilized to quantitatively measure the radiopacity of the fissure sealant and other samples examined in our study.

In dental treatments, complications such as the accidental swallowing or, worse, the aspiration of hand tools or restorative materials can occur. Therefore, using materials without appropriate radiopacity in dental treatments can pose a safety risk if the material is aspirated during the procedure. The ability of radiopacity to track and localize dental components within soft tissues during traumatic events can be life-saving. This highlights the importance of the radiopacity of materials used in such rare clinical scenarios.

The limitation of this study is the lack of investigation into the effects of moisture and temperature in the oral environment. Factors such as oral fluids, adjacent dental structures, and soft tissues can influence the radiopacity of materials. Further research incorporating simulations of oral conditions and aging processes is necessary.

## CONCLUSION

The findings of this study highlight the importance of considering the radiopacity properties of fissure sealants and filling materials used in clinical applications. Within the limitations of this study, the compomer material Compoglass F showed the highest radiopacity value, whereas the fissure sealant Helioseal F Plus exhibited the lowest radiopacity value. In particular, Fuji Triage and Compoglass F stand out with their high radiopacity, which is thought to allow easier radiographic detection of secondary caries and restoration errors. The use of materials with insufficient radiopacity may lead to missed diagnoses of caries and restoration errors. Therefore, it is crucial for dentists to consider radiopacity when selecting materials.

## CONFLICT OF INTEREST

The authors declare no conflict of interest.

## DATA AVAILABILITY

The datasets are available from the corresponding author on reasonable request.

## Ethical Approval

The protocol for this study was approved by the Ethics Committee of Atatürk University Medical Faculty in accordance with the Helsinki Declaration (Approval Number: 29 March 2024-2/30).

## Financial Support

The authors declare that this study received no financial support.

## Conflict of Interest

The authors deny any conflicts of interest related to this study.

## Author Contributions

Design: PC, AB, Data collection or data entry: FS, SDS, Analysis and interpretation: PC, FS, Literature search: PC, SDS, Writing: PC, AB.

## REFERENCES

1. Akar M, Alkis M. An Overview of Pit And Fissure Sealants 2023, in Preventive Dentistry. J Dent Fac Usak Univ.2:36-40.
2. Simonsen RJ. Pit and fissure sealant: review of the literature. Pediatric dent. 2002;24:393-414.
3. Unlugenc E, Bolgul B. Current Fissure Sealants - Literature Review. J Dent Fac Atatürk Uni. 2020;30:507-18.
4. Pinkham JR, Casamassimo PS, Henry W, McTigue DJ, Nowak AJ. Pediatric dentistry: infancy through adolescence: 4 th ed. China: Saunders; 1994. 547-50 p.
5. Gul P, Caglayan F, Akgul N, Akgul HM. Comparison of radiopacity of different composite resins. J Conserv Dent. 2017;20:17-20.
6. Yaylaci A, Karaarslan ES, Hatirli H. Evaluation of the radiopacity of restorative materials with different structures and thicknesses using a digital radiography system. Imaging Sci Dent. 2021;51:261-9.
7. Garoushi S, Vallittu P, Lassila L. Mechanical properties and radiopacity of flowable fiber-reinforced composite. Dent Mater J. 2019;38:196-202.
8. Martinez-Rus F, Garcia AM, de Aza AH, Pradies G. Radiopacity of zirconia-based all-ceramic crown systems. Int J Prosthodont. 2011;24:144-6.
9. Pekkan G, Pekkan K, Hatipoglu MG, Tuna SH. Comparative radiopacity of ceramics and metals with human and bovine dental tissues. J Prosthet Dent. 2011;106:109-17.
10. Kopuz D, Ercin O. The radiographic evaluation of 11 different resin composites. Odontology. 2024;112:428-34.
11. Dukic W. Radiopacity of Composite Luting Cements Using a Digital Technique. J Prosthodont. 2019;28:E450-E9.
12. Vyas A, Shah S, Patel N, Yagnik K, Yagnik K. Comparing radiopacity of nanohybrid composite and Giomers: an

- in vitro study. *University Journal Of Dental Sciences*. 2022;8.
13. Watts DC, McCabe JF. Aluminium radiopacity standards for dentistry: an international survey. *J Dent*. 1999;27:73-8.
  14. Chan DCN, Titus HW, Chung KH, Dixon H, Wellinghoff ST, Rawls HR. Radiopacity of tantalum oxide nanoparticle filled resins. *Dent Mater*. 1999;15:219-22.
  15. Atala MH, Atala N, Yegin E, Bayrak S. Comparison of radiopacity of current restorative CAD/CAM blocks with digital radiography. *J Esthet Restor Dent*. 2019;31:88-92.
  16. Pekkan G. Radiopacity of dental materials: An overview. *AJDR*. 2016;8:8.
  17. Lachowski KM, Botta SB, Lascala CA, Matosl AB, Sobral MAP. Study of the radio-opacity of base and liner dental materials using a digital radiography system. *Dentomaxillofac Radiol*. 2013;42:20120153.
  18. Hitij T, Fidler A. Radiopacity of dental restorative materials. *Clin Oral Investig*. 2013;17:1167-77.
  19. Espelid I, Tveit AB, Erickson RL, Keck SC, Glasspoole EA. Radiopacity of Restorations and Detection of Secondary Caries. *Dent Mater*. 1991;7:114-7.
  20. Cook WD. An investigation of the radiopacity of composite restorative materials. *Aust Dent J*. 1981;26:105-12.
  21. Lowe RA. OMNICHROMA: One Composite That Covers All Shades for an Anterior Tooth. *Compend Contin Educ Dent*. 2019;40:8-10.
  22. Scotti N, Alovizi C, Comba A, Ventura G, Pasqualini D, Grignolo F, et al. Evaluation of Composite Adaptation to Pulpal Chamber Floor Using Optical Coherence Tomography. *J Endod*. 2016;42:160-3.
  23. Akerboom HB, Kreulen CM, van Amerongen WE, Mol A. Radiopacity of posterior composite resins, composite resin luting cements, and glass ionomer lining cements. *J Prosthet Dent*. 1993;70:351-5.
  24. Kuter B, Uzel I. Comparative radiopacity of pediatric dental restorative materials. *Balk J Dent Med*. 2022;26:47-51.
  25. Tsuge T, Kawashima S, Honda K, Koizumi H, Matsumura H, Hisamatsu N. Radiopacity of anterior and posterior restorative composites. *Int Chin J Dent*. 2008;8:49-52.
  26. Bouschlicher M, Cobb D, Boyer D. Radiopacity of compomers, flowable and conventional resin composites for posterior restorations. *Oper Dent*. 1999;24:20-5.
  27. Attar N, Tam LE, McComb D. Flow, strength, stiffness and radiopacity of flowable resin composites. *J Can Dent Assoc*. 2003;69:516-21.
  28. Balci M, Turkun L, Boyacıoğlu H, Guneri P, Ergucu Z. Radiopacity of posterior restorative materials: a comparative in vitro study. *Oper Dent*. 2023;48:337-46.
  29. Karadas M, Köse TE, Atıcı MG. Comparison of Radiopacity of Dentin Replacement Materials. *J Dent Mater Tech*. 2020;9:195-202.
  30. Prevost AP, Forest D, Tanguay R, Degrandmont P. Radiopacity of Glass Ionomer Dental Materials. *Oral Surg Oral Med Oral Pathol Oral Radiol Endod*. 1990;70:231-5.
  31. Azarpazhooh A, Main PA. Is there a risk of harm or toxicity in the placement of pit and fissure sealant materials? A systematic review. *J Can Dent Assoc*. 2008;74:179-83.
  32. Elmowafy OM, Brown JW, McComb D. Radiopacity of Direct Ceramic Inlay Restoratives. *J Dent*. 1991;19:366-8.
  33. Tanomaru-Filho M, Jorge EG, Tanomaru JMG, Gonçalves M. Evaluation of the radiopacity of calcium hydroxide- and glass-ionomer-based root canal sealers. *Int Endod J*. 2008;41:50-3.
  34. Turgut MD, Attar N, Önen A. Radiopacity of direct esthetic restorative materials. *Oper Dent*. 2003;28:508-14.



35. Nomoto R, Mishima A, Kobayashi K, McCabe JF, Darvell BW, Watts DC, et al. Quantitative determination of radiopacity: Equivalence of digital and film X-ray systems. *Dent Mater.* 2008;24:141-7.
36. Abreu M, Mol A, Ludlow JB. Performance of RVGui sensor and Kodak Ektaspeed Plus film for proximal caries detection. *Oral Surg Oral Med Oral Pathol Oral Radiol Endod.* 2001;91:381-5.
37. Hintze H, Wenzel A. Influence of the validation method on diagnostic accuracy for caries. A comparison of six digital and two conventional radiographic systems. *Dentomaxillofac Rad.* 2002;31:44-9.
38. Gu S, Rasimick BJ, Deutsch AS, Musikant BL. Radiopacity of dental materials using a digital X-ray system. *Dent Mater.* 2006;22:765-70.

# Effects of Operator Experience and Scanning Distance on Intraoral Scanner Accuracy

Taygun SEZER<sup>1</sup>  Aybüke BAHADIR SEZER<sup>2\*</sup> 

<sup>1</sup> Lecturer, Department of Prosthodontics, Faculty of Dentistry, Erciyes University, Kayseri, Türkiye. [taygunsezer@erciyes.edu.tr](mailto:taygunsezer@erciyes.edu.tr)

<sup>2</sup> Asst. Prof. Dr., Department of Pediatric Dentistry, Faculty of Dentistry, Nuh Naci Yazgan University, Kayseri, Türkiye, [bahadiraybuke@gmail.com](mailto:bahadiraybuke@gmail.com)

## Article Info

### Article History

Received: 25.06.2024

Accepted: 03.09.2024

Published: 15.10.2024

### Keywords:

Intraoral scanner,  
Experience,  
Accuracy,  
Trueness,  
Precision.

## ABSTRACT

**Aim:** This study aimed to evaluate the effect of operator experience and scanning distance on the accuracy of the intraoral scanner in terms of trueness and precision.

**Material and Methods:** Reference data were obtained by scanning a partially edentulous gypsum model with implant analogs in regions 15, 16, 26, and 27 using a desktop scanner. Two expert dentists, one experienced and one inexperienced, performed test scans using the Trios 5 scanner. All data were transferred to analysis software. The scan bodies in the test scans were superimposed with the reference scan bodies for trueness measurement using a best-fit algorithm, calculating the deviation between the datasets. Precision measurement involves aligning the test scan data with each other using the same method. The effect of operator experience and scanning distance on scanner accuracy was evaluated using independent-sample t-tests.

**Results:** Full-arch scans exhibited higher trueness and precision deviations than partial-arch scans. For partial-arch scans by the experienced operator, the mean trueness deviation was 7.45µm, compared to 55.56µm for full-arch scans (p<0.001). Inexperienced operator results were 7.60µm and 58.90µm, respectively (p<0.001). Operator experience had no significant effect on trueness. For partial-arch scans performed by the experienced operator, the mean precision deviation was 2.73µm, compared to 33.87µm for full-arch scans (p<0.001). Inexperienced operator results were 3.36µm and 39.79µm, respectively (p<0.001). Operator experience significantly affected precision in partial-arch scans (p=0.044) but not in full-arch scans (p=0.563).

**Conclusion:** Scanner accuracy decreased with increasing scanning distance. The effect of operator experience on scanner accuracy was insignificant.

## Operatör Tecrübesi ve Tarama Mesafesinin Ağız İçi Tarayıcı Hassasiyetine Etkisi

### Makale Bilgisi

#### Makale Geçmiş

Geliş Tarihi: 25.06.2024

Kabul Tarihi: 03.09.2024

Yayın Tarihi: 15.10.2024

### Anahtar Kelimeler:

Ağız içi tarayıcı,  
Tecrübe,  
Hassasiyet,  
Doğruluk,  
Kesinlik

### ÖZET

**Amaç:** Bu çalışmanın amacı, operatör tecrübesinin ve tarama mesafesinin ağız içi tarayıcı hassasiyetine etkisini doğruluk ve kesinlik açısından değerlendirmektir.

**Gereç ve Yöntemler:** 15, 16, 26 ve 27 numaralı bölgelerinde implant analogu bulunan kısmi dişsiz alçı modelin masaüstü tarayıcı ile taramasıyla referans veriler elde edildi. Test taramaları, ağız içi tarayıcı kullanma deneyimi olan ve olmayan iki uzman diş hekimi tarafından Trios 5 tarayıcı kullanılarak gerçekleştirildi. Bütün veriler analiz yazılımına aktarıldı. Doğruluk ölçümü için test taramalarındaki tarama gövdeleri referans tarama gövdeleriyle "best-fit" algoritması kullanılarak karşılaştırıldı ve iki veri seti arasındaki sapma hesaplandı. Kesinlik ölçümü, aynı prosedür kullanılarak test tarama verilerinin birbiri ile karşılaştırılması ile gerçekleştirildi. Operatör tecrübesi ve tarama mesafesinin tarayıcı hassasiyetine etkisi bağımsız-örnekler t-testi ile değerlendirildi.

**Bulgular:** Tam ark taramalar kısmi ark taramalardan daha fazla doğruluk ve kesinlik sapması gösterdi. Tecrübeli operatör tarafından gerçekleştirilen kısmi ark taramalarında ortalama doğruluk sapması 7,45µm iken tam ark taramalarında 55,56µm bulundu (p<0,001). Tecrübesiz operatör taramalarında bu değerler sırası ile 7,60µm ve 58,90µm idi (p<0,001). Operatör tecrübesinin doğruluk sapması üzerine etkisi anlamlı değildi. Tecrübeli operatör tarafından gerçekleştirilen kısmi ark taramalarında ortalama kesinlik sapması 2,73µm iken tam ark taramalarında 33,87µm bulundu (p<0,001). Tecrübesiz operatör taramalarında bu değerler sırası ile 3,36µm ve 39,79µm idi (p<0,001). Operatör tecrübesi, kısmi ark taramalarında hassasiyeti önemli ölçüde etkiledi (p=0,044), ancak tam ark taramalarında etkilemedi (p=0,563).

**Sonuç:** Tarama mesafesi arttıkça tarayıcı hassasiyeti azaldı. Operatör tecrübesinin tarayıcı hassasiyete etkisi anlamlı değildi.

**To cite this article:** Sezer, T. & Bahadır-Sezer, A. Assessment of the Radiopacity of Different Fissure Sealants Compared to Dental Hard Tissues. NEU Dent J. 2024;6(Special Issue):36-44. <https://doi.org/10.51122/neudentj.2024.113>

\*Corresponding Author: Aybüke BAHADIR SEZER, [bahadiraybuke@gmail.com](mailto:bahadiraybuke@gmail.com)



## **INTRODUCTION**

Intraoral scanners have become an essential part of digital technologies in dentistry. These devices offer numerous advantages such as faster and more comfortable impressions than traditional methods, real-time scanning and visualization, virtual image management, convenient archiving, and quick and effective communication with patients and technicians.<sup>1,2</sup> However, the accuracy of intraoral scanners can be influenced by a variety of factors such as scanning distance and operator experience.<sup>3-6</sup> High precision impressions are required for the passive fit and long-term success of prostheses. Therefore, it is crucial to understand the factors affecting impression accuracy and minimize their effects.

According to ISO 5725-1, accuracy encompasses both trueness and precision. Trueness refers to how close the measurement is to the actual dimensions of the object, while precision relates to the consistency of the device when scanning the same object multiple times.<sup>7</sup> In situations with limited scanning distance, intraoral scanners typically provide accuracy that meets clinical standards.<sup>8-10</sup> However, as the scanning distance increases, the accuracy of intraoral scanners becomes questionable. Current studies seem to agree that the accuracy of scanners decreases with increasing scanning distance.<sup>9-18</sup> This is attributed to stitching errors while creating three-dimensional images. Intraoral scanners create 3D images step by step by overlaying the images obtained during scanning. Stitching errors can occur during the merging of two images, and as the scanning distance increases, these errors accumulate, resulting in more significant overall errors.<sup>4,9</sup> Additionally, the lack of landmarks in edentulous areas and the similarity in the shapes of implant scan bodies pose greater

challenges during image merging.<sup>18,19</sup> Furthermore, the learning curve and operator experience are also reported to be factors that can affect the accuracy of digital scanning.<sup>12,13,16,20-22</sup> However, some studies have reported that operator experience does not affect the accuracy of intraoral scanners.<sup>15,23</sup>

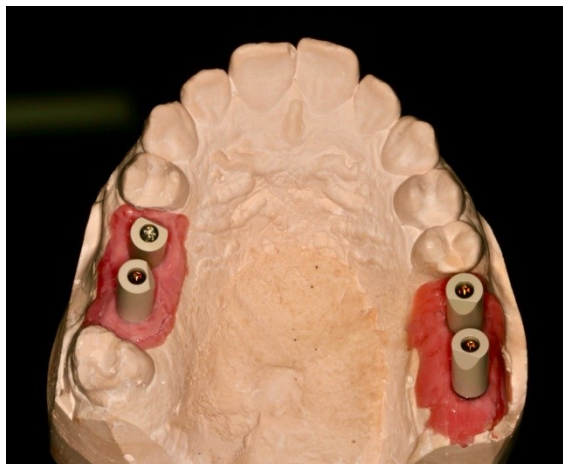
With advancements in dentistry, the use of digital technologies is increasing daily. In parallel, intraoral scanner technology is rapidly developing and evolving. These developments require studies testing the accuracy of different intraoral scanners for different clinical scenarios. This *in vitro* study aims to evaluate the effect of operator experience and scanning distance on the accuracy of intraoral scanners. The null hypotheses of the study were that the accuracy of intraoral scanners will not be affected by (1) operator experience and (2) scanning distance.

## **MATERIAL AND METHODS**

### **Study Design**

In this study, the effect of operator experience (experienced and inexperienced) on the accuracy of intraoral scanners was evaluated at two different scanning distances (half arch and full arch). A partial edentulous plaster model with four implant analogs (Implant Analogue, Institut Straumann AG, Basel, Switzerland) in the regions of teeth numbered 15, 16, 26, and 27 was used as the master model (Figure 1). Scan bodies (CARES Mono scanbody, Straumann) were screwed onto the implant analogs in the master model. To obtain reference scan data, the master model was scanned with a desktop scanner with an accuracy of 0.4  $\mu\text{m}$  (Vinyl High Resolution, Smartoptics, Oslo, Norway). Two specialist dentists performed test scans, one with and one without intraoral scanner experience, using the Trios 5 version 22.1.6 (3Shape, Copenhagen, Denmark)

intraoral scanner. Each segment in the test scans (partial arch and full arch) was compared with the corresponding reference scan (trueness assessment) and among themselves (precision assessment).



**Figure 1:** Master model

### **Obtaining Digital Impressions with Intraoral Scanners**

Before the test scans of each group, the intraoral scanner was calibrated. Test scans were performed by an operator (T.S) with more than five years of experience with intraoral scanners and an operator (A.B.S) without prior experience using intraoral scanners. Each operator performed five scans before the test scans to avoid training bias.<sup>16</sup> Then, each operator conducted 12 scans for the test scans. A new case was created for each test scan by selecting implant and tooth information on the case creation page. Scans were performed in intraoral scanning mode. The AI Scanning feature was activated, which intelligently separates teeth and surrounding gums from unwanted surfaces like the tongue, fingers, and mouth mirror and automatically removes them from the scan. All scans started from the left posterior scan body and proceeded continuously until reaching the opposite end. The occlusal-palatal-buccal scanning technique recommended by the manufacturer was used for scanning in tooth regions, while the zigzag technique described in previous studies was used for implant

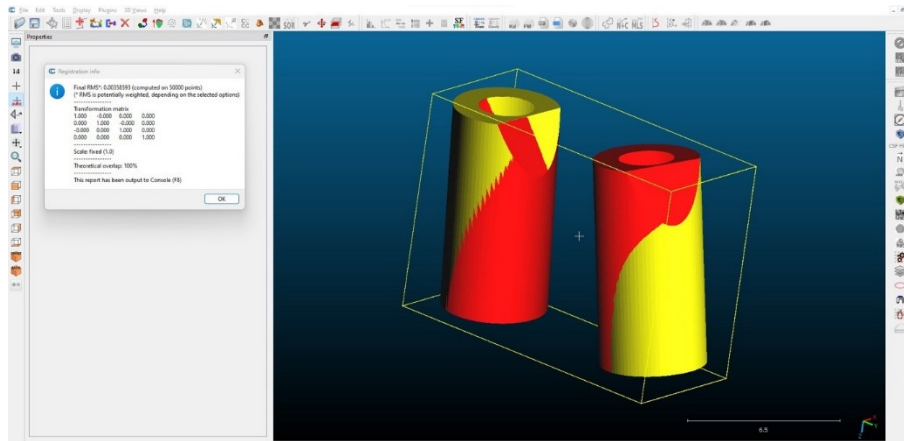
regions.<sup>24</sup> A standard 5-minute waiting period was applied between two scans to prevent fatigue-related errors and allow the scanner to cool down.

### **Calculation of Trueness and Precision Deviations**

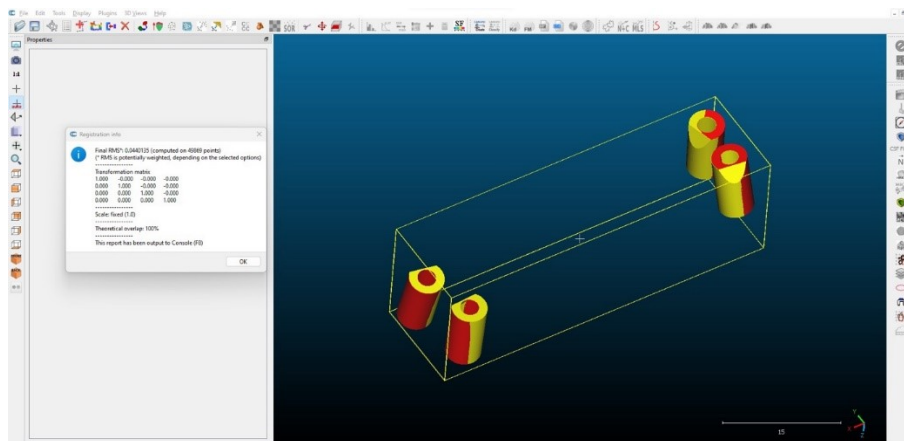
All scan data were transferred to a computer-aided design program (Exocad dental DB 3.1, Align Technology, Darmstadt, Germany) in standard tessellation language (STL) format. The scan bodies in the scan data were superimposed with the original scan bodies in the digital library. The superimposed original scan bodies were exported in two segments to evaluate the effect of scanning distance on accuracy. For the partial arch, the scan bodies of numbers 26 and 27 were selected and exported, while for the full arch, the scan bodies of numbers 15, 16, 26, and 27 were selected and exported. As stated in previous studies, this method allowed for removing irrelevant parts of the model and acquiring original scan bodies with flawless surfaces for analysis.<sup>8,16</sup> These data were then transferred to three-dimensional (3D) analysis software (CloudCompare version 2.13, CloudCompare.org). For the trueness deviation measurement, the scan bodies of each segment in the test scans (partial arch or full arch) were superimposed with the corresponding reference scan bodies using a "best-fit" alignment algorithm. This algorithm calculated the 3D deviation between the superimposed data sets as the root mean square (RMS) error.<sup>14,15,21</sup> Additionally, the software generated a color mapping of the 3D deviation for each measurement (Figure 2). The precision deviation measurement was performed using the same procedure. Unlike trueness deviation, the test scan data within each group were superimposed with each other, not with the reference scan data, to calculate the 3D deviations.<sup>8,9,16</sup> Thus, 12 measurements were

performed for each group in the trueness assessment, while 66 measurements were

performed for each group in the precision assessment.



**Figure 2A:** Colorimetric map of superimposed scan bodies of partial arch scans and calculation of 3D deviation between the two data sets.



**Figure 2B:** Colorimetric map of superimposed scan bodies of full arch scans and calculation of 3D deviation between two data sets.

### Outcomes and Power Analysis

The outcomes of this study were trueness and precision deviations. The sample size was determined considering both outcomes. When considering the effect of scanning distance on scanner accuracy, power analysis results with effect sizes of  $d=0.842$  (precision) and  $d=1.908$  (trueness),  $\alpha=0.05$ , and  $\text{power}=0.90$  indicated that a total of 17 scans for precision and a total of 6 scans for trueness are required.<sup>16</sup> When considering the effect of operator experience on scanner accuracy, power analysis results with effect sizes of  $d=1.218$  (precision) and  $d=0.740$  (trueness),  $\alpha=0.05$ , and  $\text{power}=0.90$  indicated that a total of 10 scans for precision and a total

of 22 scans for trueness are required.<sup>16</sup> Therefore, 12 scans per group were deemed appropriate based on the G-power calculation results.

### Statistical Analysis

Data were analyzed using SPSS software version 22.0 (IBM Corp.). The normality of the data was assessed using the Shapiro-Wilk test. To examine statistically significant differences in operator experience and scanning distance, an independent-sample t-test was used if the data were normally distributed, and the Mann-Whitney U test was used if the data were not normally distributed. The significance level was determined as  $p<0.05$ .

## RESULTS

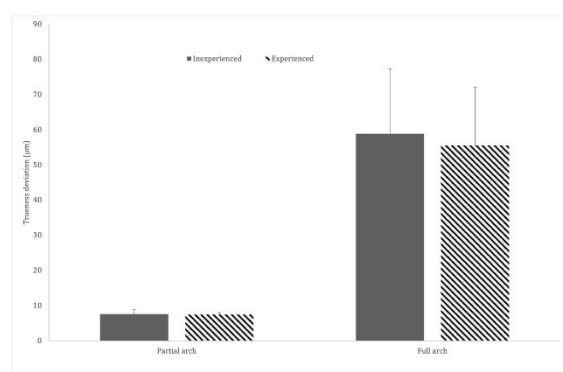
Full arc scans performed by both experienced and inexperienced operators showed statistically higher trueness deviation and precision deviation compared to partial arc scans (Figures 3 and Figure 4). Table 1 presents the mean and standard deviation values for trueness assessment, as well as the results of independent samples t-tests for experience

comparison and scan distance comparison. In partial arc scans performed by experienced operators, the mean trueness deviation was  $7.45 \pm 0.60 \mu\text{m}$ , while in full arc scans, it was  $55.56 \pm 16.56 \mu\text{m}$  ( $p < 0.001$ ). For inexperienced operators, these values were  $7.60 \pm 1.36 \mu\text{m}$  and  $58.90 \pm 18.51 \mu\text{m}$ , respectively ( $p < 0.001$ ). Operator experience did not significantly affect trueness deviation in partial and full arc scans (Table 1).

**Table 1:** 3D trueness deviations in partial and full arch scans ( $\mu\text{m}$ )

	Inexperienced	Experienced	Test Statistics*	P
Partial arch	$7.60 \pm 1.36$	$7.45 \pm 0.60$	0.342	0.737
Full arch	$58.90 \pm 18.51$	$55.56 \pm 16.56$	0.465	0.646
Test Statistics*	-9.577	-10.061		
P	<0.001	<0.001		

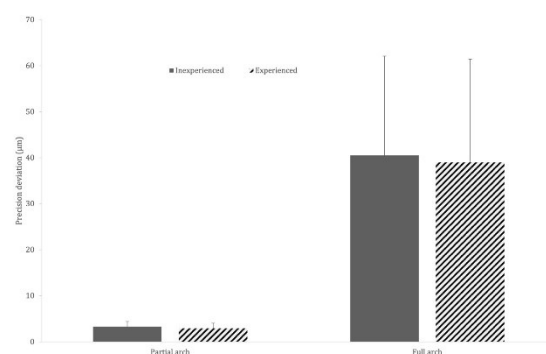
\*Independent samples t-test; Mean  $\pm$  standard deviation.



**Figure 3:** Trueness deviations in partial and full arch scans performed by experienced and inexperienced operators.

Table 2 presents the median and minimum-maximum values for precision assessment, along with the results of Mann-Whitney U tests for experience comparison and scan distance comparison. In partial arc scans performed by experienced operators, the mean precision deviation was  $2.97 \pm 1.10 \mu\text{m}$ , while

in full arc scans, it was  $39.03 \pm 22.44 \mu\text{m}$  ( $p < 0.001$ ). For inexperienced operators, these values were  $3.33 \pm 1.11 \mu\text{m}$  and  $40.51 \pm 21.60 \mu\text{m}$ , respectively ( $p < 0.001$ ). Operator experience had a significant effect on precision deviation in partial arc scans ( $p = 0.044$ ) but not in full arc scans ( $p = 0.563$ ) (Table 2).



**Figure 4:** Precision deviations in partial and full arch scans performed by experienced and inexperienced operators.

**Table 2:** 3D precision deviations in partial and full arch scans ( $\mu\text{m}$ )

	Inexperienced	Experienced	Test Statistics*	P
Partial arch	3.36 (0.98 – 5.87)	2.73 (0.99 – 5.5)	1735.50	0.044
Full arch	39.79 (11.25 – 99.68)	33.87 (10.25 – 90.66)	2051.00	0.563
Test Statistics*	4356.00	4356.00		
P	<0.001	<0.001		

\*Mann-Whitney U test; Median (min-max)

## DISCUSSION

This study evaluated the effects of operator experience and scanning distance on the accuracy of the intraoral scanner in terms of trueness and precision. The key findings revealed that operator experience had a statistically significant effect on the precision of the intraoral scanners in partial arc scans but not in full arc scans. Additionally, operator experience did not have a statistically significant impact on the trueness of the intraoral scanner. These results have crucial implications for dental professionals, as they partially reject the first null hypothesis and entirely reject the second null hypothesis, indicating a significant difference in both the trueness and precision of the intraoral scanners between partial arc scans and full arc scans.

Previous studies have revealed that many factors can affect the accuracy of intraoral scanners. These factors can be described as the type of intraoral scanner, lighting conditions, scanning patterns, modification techniques, scan body systems, implant positions, the distance between implants, the number of implants, scanning distance, and operator experience.<sup>8-18,20-22,24-29</sup> The technology of intraoral scanners is rapidly evolving to minimize the impact of these factors and to obtain highly accurate digital impressions. In parallel with these developments, it is clinically significant to investigate the scanning accuracy of newly developed systems and present updated results. In this study, one of the most recent versions of intraoral scanner systems, the Trios 5, was used. When evaluating the results of studies investigating the accuracy of intraoral scanners, the reference scanner used should also be considered. In studies, a coordinate measuring machine, an industrial scanner, or a desktop scanner can be used as a reference scanner.<sup>9-11,16-18,24</sup> This study used a high-accuracy desktop scanner as the reference scanner, similar to other studies.<sup>9,11,16,24</sup>

The findings of this study showed that full arc scans performed by both experienced and inexperienced operators had statistically higher trueness deviation and precision deviations than partial arc scans. These results support previous studies on different clinical scenarios using various intraoral scanners, indicating that the scanner's accuracy decreases as the scanning distance increases, regardless of the scanner or clinical scenario type.<sup>9-18</sup> The results of this study revealed that trueness and precision deviations in full arc scans were approximately 8 to 13 times higher than those in partial arc scans. Therefore, in cases where the bilateral posterior region will be restored with an implant or tooth-supported restoration, as in this study, performing separate digital scans of the right and left sides without crossing the midline and saving them as individual files may enable the creation of restorations with higher accuracy.

Intraoral scanners are devices used in clinical workflows by dentists, dental hygienists, and dental students, and are gaining more prominence in clinical practice over time.<sup>12,13,15,16,20-23</sup> In this context, investigating the effect of operator experience on the accuracy of intraoral scanners is important both for predicting clinical outcomes and providing insights to professionals using these devices for the first time. Previous studies have reported varying results on the impact of experience on the accuracy of intraoral scanners. Some studies indicate that experienced operators achieve more accurate digital impressions than inexperienced operators, while others find no significant difference between experienced and inexperienced operator groups.<sup>13,15,16,20-23</sup>

This study found that operator experience did not significantly affect trueness deviation in partial and full arch scans. Additionally, the precision deviation was the same between experienced and inexperienced operators in full arch scans. In partial arch scans, the scans performed by experienced operators showed

statistically less precision deviation. However, since this difference was less than 1  $\mu\text{m}$ , it was not clinically significant. Andriessen et al., a clinically acceptable distance deviation between two implants is reported to be 100  $\mu\text{m}$ , a threshold widely accepted in many studies.<sup>11,19,22</sup> The trueness and precision deviations in scans performed by both experienced and inexperienced operators in this study were below the reported acceptable limit. These results indicate that even inexperienced operators, after a short learning curve, can obtain accurate digital measurements using intraoral scanners. It should be noted that the learning curve is individual-dependent, and the operator without intraoral scanner experience in this study was a highly clinically experienced specialist dentist.

The main limitation of this study is that it was conducted under in vitro conditions. Digital impressions made under in vivo conditions can be affected by numerous factors, including saliva, patient movements, and the unique characteristics of oral tissues. Because our study was conducted under controlled conditions without these variables, the results may not fully represent actual clinical conditions. Another study limitation is the assessment of intraoral scanner accuracy for limited clinical scenarios. More in vitro and in vivo studies will be needed to understand better how intraoral scanners perform in different situations. This emphasizes the importance of ongoing research to improve the accuracy and reliability of intraoral scanners continually.

## **CONCLUSION**

Within the limitations of this study, the following conclusions were reached:

1. Full arch scans showed significantly higher trueness and precision deviations than partial arch scans.
2. No significant difference was found between scans performed by experienced and inexperienced operators.

## **Ethical Approval**

This in-vitro study does not require ethics committee approval.

## **Financial Support**

The authors declare that this study received no financial support.

## **Conflict of Interest**

The authors deny any conflicts of interest related to this study.

## **Author Contributions**

Design: MG, NG, Data collection: MG, NG, Analysis and interpretation: NG, CA, Literature review: MG, CA, Writing: MG, NG.

## **REFERENCES**



1. Floriani F, Lopes GC, Cabrera A, Duarte W, Zoidis P, Oliveira D et al. Linear accuracy of intraoral scanners for full-arch impressions of implant-supported prostheses: A systematic review and meta-analysis. *Eur J Dent.* 2023;17:964-73.
2. Ul Huq M, Abdullah J, Farook T, Jamayet N, Marya A. A current update on the use of intraoral scanners in dentistry—a review of literature. *Int J Clin Dent.* 2022;15:503-19.
3. Revilla-León M, Lanis A, Yilmaz B, Kois JC, Gallucci GO. Intraoral digital implant scans: Parameters to improve accuracy. *J Prosthodont.* 2023;32:150-64.
4. Zhang YJ, Shi JY, Qian SJ, Qiao SC, Lai HC. Accuracy of full-arch digital implant impressions taken using intraoral scanners and related variables: A systematic review. *Int J Oral Implantol.* 2021;14:157-79.
5. Wulfman C, Naveau A, Rignon-Bret C. Digital scanning for complete-arch implant-supported restorations: A systematic review. *J Prosthet Dent.* 2020;124:161-7.
6. Carneiro Pereira AL, Souza Curinga MR, Melo Segundo HV, da Fonte Porto Carreiro A. Factors that influence the



- accuracy of intraoral scanning of total edentulous arches rehabilitated with multiple implants: A systematic review. *J Prosthet Dent.* 2023;129:855-62.
7. Ender A, Mehl A. Accuracy of complete-arch dental impressions: A new method of measuring trueness and precision. *J Prosthet Dent.* 2013;109:121-8.
  8. Mangano FG, Hauschild U, Veronesi G, Imburgia M, Mangano C, Admakin O. Trueness and precision of 5 intraoral scanners in the impressions of single and multiple implants: A comparative in vitro study. *BMC Oral Health.* 2019;19:1-14.
  9. Miyoshi K, Tanaka S, Yokoyama S, Sanda M, Baba K. Effects of different types of intraoral scanners and scanning ranges on the precision of digital implant impressions in edentulous maxilla: An in vitro study. *Clin Oral Implants Res.* 2020;31:74-83.
  10. Alpkılıç DŞ, Değer Sİ. In vitro comparison of the accuracy of conventional impression and four intraoral scanners in four different implant impression scenarios. *Int J Oral Maxillofac Implants.* 2022;37:39-48.
  11. Lyu M, Di P, Lin Y, Jiang X. Accuracy of impressions for multiple implants: A comparative study of digital and conventional techniques. *J Prosthet Dent.* 2022;128:1017-23.
  12. Gimenez-Gonzalez B, Hassan B, Ozcan M, Pradies G. An in vitro study of factors influencing the performance of digital intraoral impressions operating on active wavefront sampling technology with multiple implants in the edentulous maxilla. *J Prosthodont.* 2017;26:650-5.
  13. Ciocca L, Meneghello R, Monaco C, Savio G, Scheda L, Gatto MR, et al. In vitro assessment of the accuracy of digital impressions prepared using a single system for full-arch restorations on implants. *Int J Comput Assist Radiol Surg.* 2018;13:1097-108.
  14. Chochlidakis K, Papaspyridakos P, Tsigarida A, Romeo D, Chen YW, Natto Z, et al. Digital versus conventional full-arch implant impressions: a prospective study on 16 edentulous maxillae. *J Prosthodont.* 2020;29:281-6.
  15. Canullo L, Colombo M, Menini M, Sorge P, Pesce P. Trueness of intraoral scanners considering operator experience and three different implant scenarios: a preliminary report. *Int J Prosthodont.* 2021;34:250-3.
  16. Resende CCD, Barbosa TAQ, Moura GF, do Nascimento Tavares L, Rizzante FAP, George FM, et al. Influence of operator experience, scanner type, and scan size on 3D scans. *J Prosthet Dent.* 2021;125:294-9.
  17. Chen Y, Zhai Z, Watanabe S, Nakano T, Ishigaki S. Understanding the effect of scan spans on the accuracy of intraoral and desktop scanners. *J Dent.* 2022;124:104220.
  18. Denneulin T, Rignon-Bret C, Ravalec G, Tapie L, Bouter D, Wulfman C. Accuracy of complete-arch implant digital scans: effect of scanning protocol, number of implants, and scan body splinting. *Int J Prosthodont.* 2023;36:219-27.
  19. Andriessen FS, Rijkens DR, Van Der Meer WJ, Wismeijer DW. Applicability and accuracy of an intraoral scanner for scanning multiple implants in edentulous mandibles: A pilot study. *J Prosthet Dent.* 2014;111:186-94.
  20. Giménez B, Özcan M, Martínez-Rus F, Pradies G. Accuracy of a digital impression system based on active wavefront sampling technology for implants considering operator experience, implant angulation, and depth. *Clin Implant Dent Relat Res.* 2015;17:e54-e64.
  21. Lim JH, Park JM, Kim M, Heo SJ, Myung JY. Comparison of digital intraoral scanner reproducibility and image trueness considering repetitive experience. *J Prosthet Dent.* 2018;119:225-32.
  22. Revell G, Simon B, Mennito A, Evans ZP, Renne W, Ludlow M, et al. Evaluation of complete-arch implant scanning with 5 different intraoral scanners in terms of trueness and operator experience. *J Prosthet Dent.*

- 2022;128:632-8.
23. Giuliadori G, Rappelli G, Aquilanti L. Intraoral scans of full dental arches: an in vitro measurement study of the accuracy of different intraoral scanners. *Int J Environ Res Public Health*. 2023;20:4776.
  24. Li Z, Huang R, Wu X, Chen Z, Huang B, Chen Z. Effect of scan pattern on the accuracy of complete-arch digital implant impressions with two intraoral scanners. *Int J Oral Maxillofac Implants*. 2022;37:731-9.
  25. Revilla-León M, Subramanian SG, Att W, Dent M, Krishnamurthy VR. Analysis of different illuminance of the room lighting condition on the accuracy (trueness and precision) of an intraoral scanner. *J Prosthodont*. 2021;30:157-62.
  26. Huang R, Liu Y, Huang B, Zhang C, Chen Z, Li Z. Improved scanning accuracy with newly designed scan bodies: An in vitro study comparing digital versus conventional impression techniques for complete-arch implant rehabilitation. *Clin Oral Implants Res*. 2020;31:625-33.
  27. Paspaspyridakos P, Gallucci GO, Chen CJ, Hanssen S, Naert I, Vandenberghe B. Digital versus conventional implant impressions for edentulous patients: accuracy outcomes. *Clin Oral Implants Res*. 2016;27:465-72.
  28. Zhang YJ, Qiao SC, Qian SJ, Zhang CN, Shi JY, Lai HC. Influence of different factors on the accuracy of digital impressions of multiple implants: an in vitro study. *Int J Oral Maxillofac Implants*. 2021;36:442-9.
  29. Thanasrisuebwong P, Kulchotirat T, Anunmana C. Effects of inter-implant distance on the accuracy of intraoral scanner: An in vitro study. *J Adv Prosthodont*. 2021;13:107-16.
  30. Tan MY, Hui Xin Yee S, Wong KM, Tan YH, Tan KBC. Comparison of three-dimensional accuracy of digital and conventional implant impressions: effect of interimplant distance in an edentulous arch. *Int J Oral Maxillofac Implants*. 2019;34:366-80.

# The Effect of Patient-Specific Variables on the Need for Dental Treatment Under General Anesthesia in Children: A Retrospective Study

Büşra MUSLU DİNÇ<sup>1\*</sup>  Funda ARUN<sup>2</sup> 

<sup>1</sup> Asst. Prof., Selçuk University Faculty of Dentistry Department of Pediatric Dentistry, Konya, Türkiye, dt.busramuslu@gmail.com

<sup>2</sup> Asst. Prof., Selçuk University Faculty of Dentistry Department of Pediatric Dentistry, Division of Anesthesia, Konya, Türkiye, fundaran@gmail.com

## Article Info

### Article History

Received: 29.06.2024

Accepted: 03.09.2024

Published: 15.10.2024

### Keywords:

Pediatric dentistry,  
General anesthesia,  
Duration of anesthesia.

## ABSTRACT

**Aim:** For pediatric dentists, meeting the dental treatment needs of young children is often a challenge. Behavioral management techniques may be ineffective in underage children or children with special needs. Therefore, general anesthesia (GA) is required for dental rehabilitation of uncooperative children.

The aim of this study was to examine the patient population treated under General Anesthesia (GA) in terms of age, gender, ASA Score (American Society of Anesthesiologists Physical Status Classification System), duration of anesthesia, duration of operation and the presence of systemic diseases of the patients.

**Material and Methods:** In this study, 238 patients aged 2-15 years who underwent dental treatment in the General Anesthesia Operating Room of Selçuk University Faculty of Dentistry were included. Patients were divided into 2 groups according to indications for general anesthesia. Medical health status and ASA scores were analysed. Patients were also evaluated according to age, gender, duration of anesthesia and duration of dental treatment.

**Results:** According to results, the mean age (years) and weight (kg) of the patients were 5.4 and 19.7, respectively. The gender distribution of the patients was 125 female (52.55%) and 113 male (47.5%). The number of ASA I patients was 213 (89.6%) and ASA II patients was 25 (10.5%). In terms of duration of anesthesia, 24 patients were treated in less than 60 minutes (min), 132 patients in 60-120 min and 82 patients in 120-180 min.

**Conclusion:** Dental treatment operating rooms with inpatient services can serve more different patient groups.

## Hastaya Özgü Değişkenlerin Çocuklarda Genel Anestezi Altında Diş Tedavisi İhtiyacına Etkisi: Retrospektif Çalışma

### Makale Bilgisi

### Makale Geçmişi

Geliş Tarihi: 29.06.2024

Kabul Tarihi: 03.09.2024

Yayın Tarihi: 15.10.2024

### Anahtar Kelimeler:

Çocuk diş hekimliği,  
Genel anestezi,  
Anestezi Süresi.

### ÖZET

**Amaç:** Çocuk diş hekimleri için küçük çocukların diş tedavi ihtiyaçlarını karşılamak genellikle zorlu bir süreçtir. Davranış yönlendirme teknikleri, küçük yaşlardaki çocuklar veya özel gereksinimli çocuklarda etkisiz olabilmektedir. Bu nedenle, iş birliği yapmayan çocukların diş tedavileri için genel anestezi (GA) gerekmektedir. Bu çalışmanın amacı, GA altında tedavi edilen hasta grubunu yaş, cinsiyet, ASA Skoru (Amerikan Anesteziyologlar Derneği Fiziksel Durum Sınıflandırma Sistemi), anestezi süresi, operasyon süresi ve hastaların sistemik hastalıklarının varlığı açısından incelemektir.

**Gereç ve Yöntemler:** Bu çalışmaya, Selçuk Üniversitesi Diş Hekimliği Fakültesi Genel Anestezi Ameliyathanesi'nde diş tedavisi yapılan 2-15 yaş arası 238 hasta dahil edilmiştir. Hastalar, genel anestezi endikasyonlarına göre 2 gruba ayrılmıştır. Hastaların tıbbi sağlık durumu ve ASA skorları analiz edilmiştir. Ayrıca, hastalar yaş, cinsiyet, anestezi süresi ve diş tedavi süresi açısından da değerlendirilmiştir.

**Bulgular:** Sonuçlara göre, hastaların ortalama yaşı (yıl) 5,4 ve ortalama ağırlığı (kg) 19,7 olarak belirlenmiştir. Hastaların cinsiyet dağılımı 125 kadın (%52,55) ve 113 erkek (%47,5) şeklindedir. ASA I grubundaki hasta sayısı 213 (%89,6), ASA II grubundaki hasta sayısı ise 25 (%10,5) olarak kaydedilmiştir. Anestezi süresi açısından bakıldığında, 24 hasta 60 dakikadan kısa, 132 hasta 60-120 dakika ve 82 hasta 120-180 dakika aralığında tedavi edilmiştir.

**Sonuç:** Bu çalışmanın sonuçlarına göre, hastaların çoğunlukla ASA I sınıfında yer almasının, ameliyathane biriminde günlük genel anestezi hizmeti sunulmasından kaynaklandığı düşünülmektedir. Yataklı servisi bulunan diş tedavisi ameliyathanelerinin ise daha geniş bir hasta grubuna hizmet verebileceği öngörülmektedir.

**To cite this article:** Muslu Dinç B, Arun F. The Effect of Patient-Specific Variables on the Need for Dental Treatment Under General Anesthesia in Children: A Retrospective Study. NEU Dent J. 2024;6(Special Issue):45-50.

<https://doi.org/10.51122/neudentj.2024.114>

\*Corresponding Author: Büşra MUSLU DİNÇ, dt.busramuslu@gmail.com



## INTRODUCTION

Oral and dental diseases are among the health problems that are quite common worldwide. In fact, dental caries are described as one of the most common chronic diseases of childhood, and its prevalence has been reported to increase in children aged 2-5 years in recent times. Dental caries cause functional problems in children, such as chewing and speech disorders, and psychological problems, such as hesitation to smile and speak, negatively affecting the quality of life.<sup>1,2</sup>

The negative effects of dental caries are not limited to quality of life and oral symptoms. Dental caries in the primary dentition may be associated with malnutrition.<sup>3</sup> Children with severe Early Childhood Caries (ECC) have been reported to have poorer diets than those without. Most of these problems that adversely affect health can be prevented or treated at an early stage.<sup>4</sup>

The American Association of Paediatric Dentistry (AAPD) has reported that the treatment of orofacial diseases is medically necessary to prevent pain and infection, to restore the functionality and form of the teeth, and to correct facial profile disorders and dysfunction.<sup>5</sup>

Pediatric dentists should be able to accurately assess the child's reaction to dental treatment according to the level of development and behaviour. Some of the reasons for a child's non-compliance with treatment include general or situational anxieties, inadequate preparation for the appointment, fears during the dental appointment, previous unpleasant dental/medical experience, pain and parental factors.<sup>6</sup> Children under the age of 6 and those with systemic diseases and/or disabilities can be challenging for pediatric dentists to treat in a clinical setting. In these cases, non-pharmacological behavioral management techniques are prioritized whenever possible.<sup>7</sup> Behavioural management techniques ensure that most children receive dental treatment with minimal fear and discomfort in a clinical setting. However, when these methods are

ineffective, the option of 'general anesthesia', one of the advanced behavioural management techniques, is considered.

In pediatric dentistry, many factors affect GA indication. Factors influencing the decision between GA and conventional dental treatment include the quality and amount of treatment needed, the child's age, and the child's level of cooperation.<sup>8</sup>

According to the "Behavior Guidance Guide for Pediatric Patients in Dentistry" published by AAPD, the purposes of choosing GA in dentistry include:

- Assisting in treating patients who are at risk mentally, physically, or medically: GA is used to manage and treat children with significant health concerns or disabilities that make traditional dental procedures challenging.

- Relieving anxiety: It helps in alleviating anxiety and fear associated with dental visits, especially in young children or those with prior negative experiences.

- Reducing unwanted behaviors and reactions to dental treatment: GA minimizes disruptive behaviors and reactions that complicate dental procedures, ensuring a smoother treatment process.

- Providing safe, efficient, and effective dental care: It allows dental professionals to deliver high-quality care in a controlled environment, ensuring the safety and comfort of the child.

- Eliminating the patient's response to pain: GA effectively manages and eliminates pain responses, ensuring that the child remains comfortable throughout the procedure.<sup>9</sup>

These objectives underline the importance of general anesthesia in facilitating comprehensive dental care for pediatric patients who might otherwise face significant challenges during dental treatments.

The concept of dental treatment under general anesthesia is the administration of GA to the patient by a team under the responsibility

of an anesthesiologist for various dental procedures.<sup>10</sup> Surgical procedures such as restorative treatments, placed stainless steel crowns, tooth extraction, pulpal treatments (pulpotomy or root canal treatment), as well as labial or lingual frenectomies, odontoma or other benign tumor surgeries of oral soft tissues, removal of cystic lesions, dental auto transplantations, exposure of unerupted teeth with orthodontic approach, are also performed under GA. In addition, minor procedures such as impression, removable or occlusal appliances, and periodontal splints can also be performed under general anesthesia.<sup>10,11</sup> In a study reporting an increase in the frequency of dental GA in children over the last 10 years, it was noted that there was a rise, particularly in the use of stainless-steel crowns and extraction of deciduous teeth.<sup>12</sup>

The aim of this retrospective study is to examine the general medical health status and demographic properties of our patient population, which is treated under GA in our clinic, and other factors related to the necessity of dental treatment under GA.

### MATERIALS AND METHODS

Ethical approval for the study was obtained from the Non-Interventional Clinical Research Ethics Committee of Selçuk University, with the decision numbered 2024/09. This study included 238 patients who had previously visited the Pediatric Dentistry Clinic but could not be treated in a clinical setting and who underwent dental treatment under general anesthesia at the General Anesthesia Operating Room of Selçuk University Faculty of Dentistry between

January 1, 2023, and January 1, 2024. The age range of the patients was 2-15 years. The indications for general anesthesia were examined and the patients were divided into 2 groups as healthy/noncooperative patients and patients with mental/physical disability or systemic disease. ASA scores were examined that given to the patients who were evaluated preoperatively by an anesthesiologist. Patients were also evaluated according to age, gender, duration of anesthesia and duration of dental treatment.

### Statistical Analysis

Statistical analysis of the study was carried out using IBM SPSS Statistics 21. Shapiro-Wilk test was used to verify the suitability of continuous variables for normal distribution. A statistician evaluated the demographic data in frequency, percentage, mean, and standard deviation (SD). Student t-test and ANOVA were used to test the significance of differences between groups in continuous variables, Pearson's chi-square test was used to test the significance of differences between groups with categorical data and  $p < 0.05$  was considered as statistically significant.

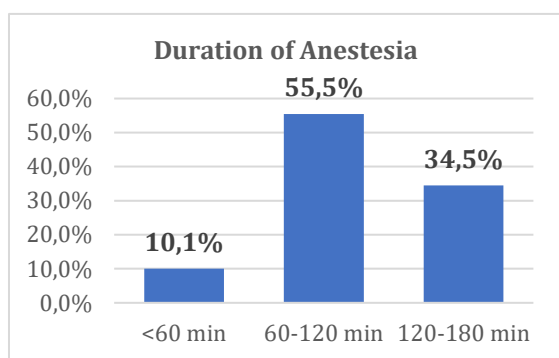
### RESULTS

According to the data obtained, the mean age of the patients was 5.4 ( $\pm 1.8$ ) years, and the mean weight was 19.7 ( $\pm 5.9$ ) kg. The gender distribution of the patients was 125 female (52.55%) and 113 male (47.5%). Most patients were ASA I (89%), while the remainder were ASA II (11%). Demographic data of patients are presented in Table 1.

**Table 1:** Demographic data of patients (n=238)

SA Status	Number of Patients (n)	ASA II Status		Sex	
		Physical	Mental	Male	Female
ASA I	217			99	118
ASA II	21	Cardiovascular		4	
		Asthma		4	2
		Endocrine			2
		Hematologic			1
			Autism	3	1
			Mental Retardation	2	
			Epilepsy	1	1

The indication for general anesthesia in all ASA I patients was difficulty in cooperation, whereas in all ASA II patients, it was a systemic disease or special need. In terms of duration of anesthesia, 24 patients were treated in less than 60 minutes (min), 132 patients in 60-120 min, and 82 patients in 120-180 min. (Figure 1) Mean and standard deviation (SD) of the age and weight of patients by the duration of anesthesia and distribution according to anesthesia duration and ASA are shown in Tables 2 and 3.



**Figure 1:** Duration of anesthesia

**Table 2:** Mean and SD age and weight of patients by the duration of anesthesia

Duration of Anesthesia	Age (years)	Weight (kg)
<60 min	6.0 ( $\pm$ 1.7)	23.5 ( $\pm$ 5.7)
60-120 min	5.4 ( $\pm$ 1.6)	19.2 ( $\pm$ 4.6)
120-180 min	5.1 ( $\pm$ 2.0)	19.4 ( $\pm$ 7.5)

**Table 3:** Patient distribution according to anesthesia duration and ASA status

ASA Status	Duration of Anesthesia		
	<60 min	60-120 min	120-180 min
ASA I (%)	9.66	49.58	30.25
ASA II (%)	0.42	5.88	4.20
Total (%)	10.1	55.5	34.5

## DISCUSSION

Dental treatment under GA benefits pediatric patients who require extensive treatment and whose desired results cannot be achieved using local anesthesia and behavioral management. Another population group suitable for this type of treatment is certain physically or mentally disabled patients, often characterized by poor oral hygiene, soft and

cariogenic diets, periodontal disease, and polypharmacy.<sup>13</sup> This study examined the overall medical and demographic characteristics of the patient population receiving dental treatment under GA in our pedodontics clinic, as well as other factors related to the need for this treatment.

According to our results, the mean age of the patients was 5.4 ( $\pm$ 1.8) years, with 89% classified as ASA I and 11% as ASA II ( $p < 0.01$ ). Since most of the patients were noncooperative children, the ASA I rate was found to be high. In patients classified as ASA II, asthma, congenital heart disease and autism were frequently accompanying systemic diseases.

A survey conducted at the pediatric dental clinic of a Korean university hospital found that the most prevalent age group receiving dental treatment under general anesthesia was 5-8 years old (124 patients, 47.1%). The primary reason for administering anesthesia was dental anxiety or phobia.<sup>14</sup> In another study, the patient population consisted of 98 children. Over half of the sample population were males ( $n = 61$ , 62.2%), and 37 patients were females (37.8%). Patients' ages ranged from 1 to 15 years, with a mean age distribution of 5.4 years and a SD of  $\pm$ 2.8 years.<sup>15</sup> Our results are like those of these studies, which also observed a prevalent age group but differed in gender distribution in pediatric dental patients undergoing treatment under general anesthesia. The mean age of the patients was 5.4 ( $\pm$ 1.8) years, and the female population ( $n=125$ ) was larger than the male population ( $n=113$ ) in this study.

In a study evaluating the duration of GA in pediatric dentistry, the mean duration of anesthesia was reported to be  $97.48 \pm 10$  min in children under 3 years of age,  $101 \pm 36$  min in children aged 3-6 years, and  $105 \pm 33$  hours in children older than 6 years.<sup>16</sup> In another study, the average time under GA was  $132.7 \pm 77.6$  min, and the mean duration of treatment was

101.9 ± 71.2 min.<sup>14</sup> In this study, 24 patients were treated in less than 60 min, 132 patients in 60-120 min, and 82 patients in 120-180 min.

According to a 2019 study, patients receiving dental general anesthesia were most commonly those with intellectual disabilities, congenital heart disease, and epilepsy.<sup>17</sup> The study sample consisted of 26 (26.5%) ASA II patients and 72 (73.5%) healthy children in another study from the literature.<sup>15</sup> In this study, non-cooperative patients (ASA I) constituted the majority. At the same time, asthma, autism, and congenital heart disease were the most common systemic diseases in the ASA II group of patients, respectively. Most patients classified as ASA I were linked to our clinical acceptance of only day-case patients.

### **CONCLUSION**

Dental treatment under GA is crucial for preventing the distress of multiple visits for pediatric patients with adaptation difficulties or special needs. According to this study's results, most patients were in ASA I class because GA service was provided daily in the operating room unit. Inpatient facilities must provide dental treatment under general anesthesia for higher-risk patient groups from an anesthetic perspective.

### **Ethical Approval**

Ethical approval for the study was obtained from the Non-Interventional Clinical Research Ethics Committee of Selçuk University, with the decision numbered 2024/09.

### **Financial Support**

The authors declare that this study received no financial support.

### **Conflict of Interest**

The authors deny any conflicts of interest related to this study.

### **Author Contributions**

Design: BMD, FA, Data collection or data entry: FA, Analysis and interpretation: BMD, FA, Literature review: BMD, FA, Writing: BMD.

### **REFERENCES**

1. Pitts NB, Zero DT, Marsh PD, Ekstrand K, Weintraub JA, Ramos-Gomez F, et al. Dental caries. *Nat. Rev. Dis. Primers.* 2017;3:1-16.
2. Bönecker M, Abanto J, Tello G, Oliveira LB. Impact of dental caries on preschool children's quality of life: an update. *Braz. Oral Res.* 2012;26:103-7.
3. Psoter WJ, Reid BC, Katz RV. Malnutrition and dental caries: a review of the literature. *Caries Res.* 2005;39:441-7.
4. Schroth RJ, Levi J, Kliwer E, Friel J, Moffatt ME. Association between iron status, iron deficiency anaemia, and severe early childhood caries: a case-control study. *BMC Pediatr.* 2013;13:1-7.
5. Dhar V, Gosnell E, Jayaraman J, Law C, Majstorović M, Marghalani AA, et al. Nonpharmacological Behavior Guidance for the Pediatric Dental Patient. *Pediatr Dent.* 2023;45:385-410.
6. Dharmani CKK. Management of children with special health care needs (SHCN) in the dental office. *JMS.* 2018;32:1-6.
7. Townsend JA, Wells MH. Behavior guidance of the pediatric dental patient. *Pediatr Dent: Elsevier;* 2019. p. 352-70. e2.
8. Albadri S, Lee S, Lee G, Llewelyn R, Blinkhorn A, Mackie I. The use of general anaesthesia for the extraction of children's teeth. Results from two UK dental hospitals. *European Archives of Pediatr Dent.* 2006;1:112-7.
9. Dentistry AAoP. Behavior guidance for the pediatric dental patient. *The Reference Manual of Pediatric Dentistry Chicago, Ill: American Academy of Pediatr Dent.* 2020:292-310.
10. Savanheimo N, Sundberg SA, Virtanen JI, Vehkalahti MM. Dental care and treatments provided under general anaesthesia in the Helsinki Public Dental Service. *BMC Oral Health.* 2012;12:1-8.

11. Yi Y, Lee J, Yi H, Asher S, Feldman L, Rivas-Morello C, et al. Variables affecting general anesthesia time for pediatric dental cases. *Pediatr Dent*. 2015;37:508-12.
12. Chen Y-P, Hsieh C-Y, Hsu W-T, Wu F-Y, Shih W-Y. A 10-year trend of dental treatments under general anesthesia of children in Taipei Veterans General Hospital. *Journal of the J Chin Med Assoc*. 2017;80:262-8.
13. Escribano Hernández A, Hernández Corral T, Ruiz Martín E, Porteros Sánchez JA. Results of a dental care protocol for mentally handicapped patients set in a primary health care area in Spain. *Med Oral Patol Oral Cir Bucal*. 2007;12:E492-5.
14. Shin B, Yoo S, Kim J, Kim S, Kim J. A survey of dental treatment under general anesthesia in a Korean university hospital pediatric dental clinic. *J Dent Anesth Pain Med*. 2016;16:203-8.
15. Abdo M, Al Halabi M, Hussein I, Salami A, Khamis AH, Kowash M. Characteristics of Pediatric Dental Treatment Provided under General Anesthesia in Dubai, United Arab Emirates: A Retrospective Analysis. *I Int J Dent*. 2022;2022:9900775.
16. Campbell RL, Shetty NS, Shetty KS, Pope HL, Campbell JR. Pediatric dental surgery under general anesthesia: uncooperative children. *Anesth Prog*. 2018;65:225-30.
17. Akpınar H. Genel anestezi altında dental tedavi yapılan olguların değerlendirilmesi. *Cukurova Med J*. 2019;44:341-6.



# Investigation of Fracture Strength and SEM Images of Different CAD-CAM Materials Applied to Two Different Inlay Cavities

Rahime Zeynep ERDEM<sup>1\*</sup>  Kevser KARAKAYA<sup>2</sup> 

<sup>1</sup> Asst. Prof., Department of Restorative dentistry, Faculty of Dentistry, Afyonkarahisar Health Sciences University, Afyonkarahisar, Türkiye, zeynepguvendi@hotmail.com

<sup>2</sup> Asst. Prof., Department of Prosthodontics dentistry, Faculty of Dentistry, Afyonkarahisar Health Sciences University, Afyonkarahisar, Türkiye, kevserkarakaya91@gmail.com

## Article Info

### Article History

Received: 30.06.2024

Accepted: 04.09.2024

Published: 15.10.2024

### Keywords:

Cad-Cam,  
Inlay,  
Fracture,  
Zirconia-reinforced lithium silicat,  
Sem anaynes.

## ABSTRACT

**Introduction:** This study aims to determine and compare the fracture strength and failure modes of zirconia-reinforced lithium silicate glass ceramics (ZLS) and yttria-stabilized zirconia-based ceramic MOD and MO inlay restorations.

**Materials and Methods:** Stumps representing the maxillary second premolar were prepared using HyperDent software and CAD/CAM milling units. Thirty-two epoxy resin die models were obtained, with 16 samples in each group. Subsequently, restorations were fabricated using Vita Suprinity (VITA Zahnfabrik, Bad Sackingen, Germany) and IPS e.max ZirCAD CAD/CAM (Ivoclar et all., Liechtenstein) blocks to restore the inlay cavities. The specimens were subjected to aging and then tested for fracture using a universal testing machine. The resulting fractures were classified. Data normality was assessed using the Shapiro-Wilk test, and homogeneity of variances was evaluated using the Levene test. The interaction between restorative material type and cavity surface was tested using two-way ANOVA.

**Results:** The fracture strength of IPS e.max ZirCAD material (mean value: 723.18±57.51) is higher than that of Vita Suprinity ZLS material (689.86±113.61), but this difference is not statistically significant (F=3.46, p=0.073). The group with 3-surface cavities in the tooth material (768.00±60.60) has significantly different fracture strength compared to the group with 2-surface cavities (645.037±71.20) (F=47.18, p<0.001).

**Conclusions:** Having a 3-surface cavity may further enhance the fracture resistance of inlay restorations, and this difference is statistically significant. There is no significant difference in fracture strength among restorative materials.

## İki Farklı İnley Kavitesine Uygulanan Farklı CAD-CAM Materyallerinin Kırılma Dayanımı Ve SEM Görüntülerinin İncelenmesi

### Makale Bilgisi

#### Makale Geçmiş

Geliş Tarihi: 30.06.2024

Kabul Tarihi: 04.09.2024

Yayın Tarihi: 15.10.2024

#### Anahtar Kelimeler:

Cad-Cam,  
Inley,  
Kırılma,  
Zirkonyayla güçlendirilmiş lityum disilikat,  
Sem Analizi.

### ÖZET

**Amaç:** Zirkonya lityum-disilikat cam-seramik ve itriyumla stabilize edilmiş zirkonya bazlı seramik MOD ve MO inlay restorasyonların kırılma mukavemetini ve başarısızlık modlarını belirlemek ve karşılaştırmaktır.

**Materyal-Metod:** Örneklerin elde edileceği maksillar 2. premolar dişini temsil eden güdükler, CAD/CAM freze ünitesinde hyperdent yazılım kullanılarak hazırlandı. Her bir grup için 16 adet olacak şekilde toplam 32 adet epoksi rezinden die model elde edildi. Daha sonra inley kavitelelerini restore etmek için Vita Suprinity (VITA Zahnfabrik, BadSackingen, Germany) ve IPS e.max ZirCAD CAD/CAM (Ivoclar Vivadent Schaan Liechtenstein) bloklardan freze işlemi ile restorasyonlar üretildi. Örnekler yaşlandırma işleminden sonra universal bir test cihazı ile kırılma testine tabi tutuldu. Sonra oluşan kırıklar sınıflandırıldı. Verilerin normal dağılımı Shapiro-wilk testi ile değerlendirildi. Varyansların homojenliği Levene testi ile değerlendirildi. Restoratif materyal türü ve kavite yüzey etkileşimi two way Anova ile test edildi.

**Bulgular:** IPS e.max ZirCAD materyalin kırılma mukavemeti ortalama değeri (723,18±57,51), Vita Suprinity ZLS materyelinden (689,86±113,61) yüksektir ancak istatistiksel olarak anlamlı değildir (F=3,46, p= 0,073). 3 yüzeyli kaviteye sahip diş materyal grubu (768,00±60,60), 2 yüzeyli kaviteye sahip olan gruptan (645,037±71,20) önemli derecede farklı kırılma mukavemetine sahiptir (F=4718, p<0,001).

**Sonuç:** Kavitenin 3 yüzeyli olması, inley restorasyonunun kırılma direncini daha da artırabilir, ve bu istatistiksel olarak anlamlıdır. Restoratif materyaller arasında kırılma mukavemeti yönünden önemli bir fark yoktur.

**To cite this article:** Erdem RZ, Karakaya K. Investigation of Fracture Strength and SEM Images of Different CAD-CAM Materials Applied to Two Different Inlay Cavities. NEU Dent J. 2024;6(Special Issue):51-9. <https://doi.org/10.51122/neudentj.2024.115>

\*Corresponding Author: Rahime Zeynep ERDEM, [zeynepguvendi@hotmail.com](mailto:zeynepguvendi@hotmail.com)



## **INTRODUCTION**

Ceramic materials were first used in dentistry in the late 1700s. The concept of full ceramic restorations was pioneered by Land in 1889.<sup>1</sup> Ceramics exhibit superior properties to other materials, including excellent thermal insulation, biocompatibility, inertness, and exceptional aesthetics.<sup>2</sup> Composite restorations offer reduced polymerization shrinkage, minimal microleakage, and decreased postoperative sensitivity. However, ceramics are prone to fracture due to their structural characteristics in oral conditions.<sup>3</sup> Another disadvantage is that ceramic materials require indirect application, leading to more prolonged clinical procedures than direct restorations.

Dental CAD/CAM (Computer-Aided Design/Computer-Aided Manufacturing) systems streamline the fabrication of dental restorations. These systems allow for single-session restorations in the dental office. Specifically, CAD/CAM technology produces ceramic blocks that are more homogeneous and have fewer defects or cracks compared to ceramics processed in dental laboratories.<sup>3</sup> Indirect inlays, made from gold, composite resin, or ceramic materials, are commonly used to treat posterior teeth with significant substance loss. Ceramic inlays from these materials are preferred due to their long-term color stability, chemical resistance, fluorescence, high compressive strength, wear resistance, and biocompatibility. However, the leading cause of failure in ceramic inlay/onlay restorations remains marginal discrepancies and cohesive fractures.<sup>4</sup>

Materials used in CAD/CAM systems include feldspathic ceramics, leucite-reinforced glass ceramics, lithium disilicate-reinforced glass ceramics, oxide ceramics, glass-infiltrated oxide ceramics, sintered oxide ceramics, nanoceramics, hybrid ceramics, zirconia-reinforced lithium disilicate ceramics, composites, and metals. Restorations made with

CAD/CAM have shown clinical success due to technological advancements in CAD/CAM systems.<sup>5</sup> Recently developed, CAD/CAM compatible materials like zirconia-reinforced lithium silicate glass ceramics (ZLS) combine the advantages of zirconia and glass ceramics, offering high mechanical strength, good marginal fit, and excellent aesthetics due to properties such as translucency, opalescence, and fluorescence.<sup>6</sup> The transformation of zirconia from tetragonal to monoclinic phase prevents crack propagation, leading to a 4.5% volume expansion, thus stopping crack advancement.<sup>7</sup> All these features reduce the brittleness and increase the durability of ZLS compared to lithium disilicate ceramics without zirconia.<sup>8</sup>

IPS e.max ZirCAD, produced by Ivoclar, is a Y-TZP block designed for CAD/CAM technology use. The restoration design is processed 20% larger than standard dimensions to accommodate sintering shrinkage.<sup>9</sup>

This *in vitro* study aims to determine and compare the fracture strength and failure modes of zirconia lithium disilicate glass-ceramic and yttria-stabilized zirconia-based ceramic MOD and MO inlay restorations. The tested hypotheses were as follows: 1) The type of restoration material does not affect the fracture resistance of the tooth-restoration complex, and 2) Different cavity designs do not affect the fracture resistance of the tooth-restoration complex; 3) There is no interaction between the type of restoration material and different cavity designs on fracture strength.

## **MATERIALS AND METHODS**

The necessary ethical approval for this study was received by the Afyonkarahisar Health Sciences University Non-Pharmaceutical and Medical Device Ethics Committee (approval date: 07.04.2023, protocol number: 2023/4). To ensure standardization, stumps representing maxillary

second premolar teeth were prepared using CAD/CAM milling units with Hyperdent software.

### Restorative Procedures

The die dimensions were mesiodistal width of 6 mm, buccolingual width of 8 mm, and crown length of 7.5 mm. The inlay cavity was prepared with a depth of 1.5 mm from the deepest point (fissure, the anatomical area between tooth cusps) to the cavity floor (the largest horizontal area between the shoulders). The proximal surface dimensions in the buccolingual direction were 4 mm. The shortest isthmus distance in the buccolingual direction on the occlusal surface was 4 mm. The shoulder width was 1.5 mm, and the shoulder depth was 1.5 mm from the cavity floor. The cavity surface angle from the cavity floor to the occlusal surface was 6°. The samples were divided into mesio-occlusal (MO) and mesio-occlusal-distal (MOD) cavities. 32 epoxy resin die models (16 for each group) were prepared. Subsequently, restorations were milled from Vita Suprinity and IPS e.max ZirCAD CAD/CAM blocks to restore the inlay cavities. The fabricated restorations were cemented onto epoxy resin dies using resin cement. Four different groups were obtained (n=32), as shown in Figure 1.

#### 1. IPS e.max ZirCAD (E group)

- 1a.MO ( mesio-okluzal) IPS e.max ZirCAD (emo)
- 1b.MOD (mesio-okluzal-distal) IPS e.max ZirCAD (e mod)

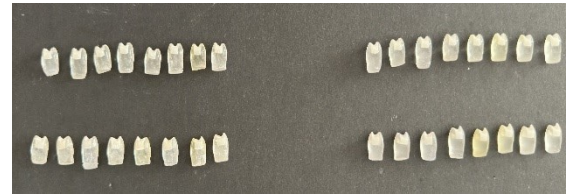#### 2. Vita Suprinity ZLS (V group)

- 2a.MO ( mesio-okluzal) Vita Suprinity ZLS (vmo)
- 2b.MOD (mesio-okluzal-distal) Vita Suprinity ZLS (vmod)

**Figure 1:** Study design

The inner surface of ceramic inlays was treated with hydrofluoric acid for 20 seconds using a brush. Next, they were rinsed with water for 60 seconds and dried with air for 20 seconds. Silane agent was then applied to the hydrofluoric acid-treated ceramic inlay surfaces using a brush, creating a thin layer, and air-dried

for 3-5 seconds. Materials are shown in table 1. After each inlay's surface treatment, they were cemented with RubySE CEM (Inci Dental, Türkiye) using resin cement on an epoxy resin die. The inlays' buccal, lingual, distal, and mesial surfaces were polymerized by exposing them to 20 seconds of light from an LED device, and the cementation process was completed for 32 samples (Figure 2). The samples were then embedded in acrylic resin (Figure 3).



**Figure 2:** Samples with cementation completed



**Figure 3:** Sample embedded in acrylic resin


### Fracture load test

The specimens were soaked in distilled water at 37°C for 24 hours to simulate temperature changes that could occur in the oral environment. The samples were then subjected to a thermal cycling process between 5°C and 55°C, with 10-second intervals and 20 seconds of exposure at 5000 cycles (MTE-101; Moddental, Ankara, Türkiye).

**Tablo 1:** Materials used in this study

Name	Type	Manufacturer
IPS e.max ZirCAD	4 mol% yttrium stabilized zirconia (4Y-PSZ)	Ivoclar Vivadent (Schaan, Liechtenstein)
Vita Suprinity	zirkonya lityum-disilikat	VITA Zahnfabrik, BadSackingen, Germany
Porcelain Etch & Silane		Ultradent
RubySE CEM		İncidental/ İstanbul,

		Türkiye
--	--	---------



**Figure 4:** An image before the fracture

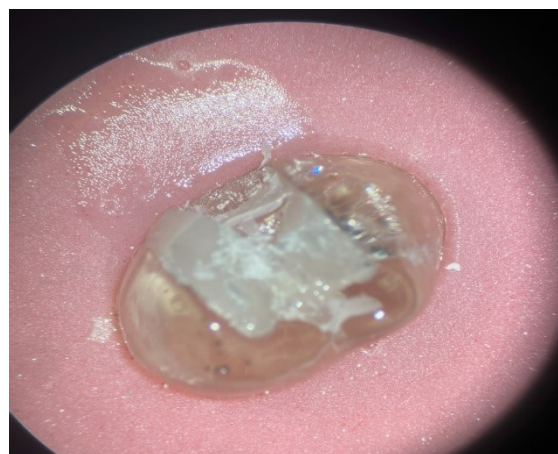
Before the fracture test, the specimens were fixed in self-polymerizing acrylic resin. A 5 mm diameter stainless steel ball located on the upper part of the universal testing machine was placed perpendicular to the crowns occlusal surface (Figure 4). The crowns occlusal surfaces were loaded with a 1 mm/min loading rate until fracture occurred (Moddental, Ankara, Türkiye). The force values at fracture were recorded in Newtons (N).

#### **Fracture mode and microstructure analysis**

In the study, the specimens subjected to the fracture resistance test were examined under a microscope (Zumax Oms1950 Basic, Zumax Medical, China) at 19x magnification to determine the fracture types after completing the test (Figure 5). The evaluation of fracture types was based on Burke's classification.<sup>10</sup> According to this classification, the fracture types were recorded according to the following criteria:

- Tip I: Minimal breaks or cracks in the crown,
- Tip II: Fracture of less than half of the crown,
- Type III: Crown fracture along the midline or fracture or displacement to the end of the crown,
- Tip IV: Fracture of more than half of the crown,
- Tip V: It indicates that catastrophic fractures are

seen when the crown breaks.



**Figure 5:** Examination of broken samples under a microscope

After the fracture process, SEM (LEO 1430 VP) analysis was performed on a specific sample from each group for detailed examination. Before SEM examination, the surfaces of the fractured samples were coated with a thin layer using a carbon sputter coater (BAL-TEC SCD 005 Sputter Coater). The fractured surfaces were evaluated at magnifications of x50, x100, x150, and x250 (Figure 6).

#### **Statistical analysis**

Statistical analysis was performed using IBM SPSS Statistics for Windows, Version 25.0 (IBM Corp., Armonk, NY, USA). The normal distribution of the data was assessed using the Shapiro-Wilk test. The homogeneity of variances was evaluated using the Levene test. The interaction between the type of restorative material and cavity surface was tested using a two-way ANOVA. P-values less than 0.05 were considered statistically significant.

#### **RESULTS**

The groups' data exhibited a normal distribution according to the Shapiro-Wilk test ( $p > 0.05$ ). Variance homogeneity was confirmed using the Levene test ( $p = 0.299$ ). The analysis results related to fracture resistance of the test groups are presented in Tables 2 and 3.




Figure 6: SEM image after fracture of 1 sample from VMO, VMOD, EMO, EMOD groups (Fracture line-epoxy model and resin cement images)

Table 2: Two-way analysis of variance

Source	Sum of squares	df	Mean square	F	P value
Intercept	15973541.12	1	15973541.12	6229.60	<0.001
Material group	8881.11	1	8881.11	3.46	0.073
Cavity group	120970.51	1	120970.51	47.18	<0.001
Material *Cavity	50474.59	1	50474.59	19.68	<0.001

Table 3: Means and standart deviations of groups

	Two surface		Three surface		Total		P value
	n	Mean±std	n	Mean±std	n	Mean±std	
IPS emax ZIRCAD	8	701.41±51.35	8	744.95±58.05	16	723.18±57.52	0.073
VITA SUPRINITY ZLS	8	588.66±31.06	8	791.06±57.32	16	689.86±113.61	
Total	16	645.04±71.21	16	768.01±60.60			

One-way analysis of variance

According to the analysis, the average fracture strength of the material in Group 1 (IPS e.max ZirCAD) (723.18±57.51) is higher than that of Group 2 (Vita Suprinity ZLS) (689.86±113.61). However, this difference is not statistically significant (F=3.46, p=0.073).

The dental material group with three-surface cavities (768.00±60.60) significantly differs in fracture strength from the group

with two-surface cavities (645.037±71.20) (F =47.18, p<0.001).

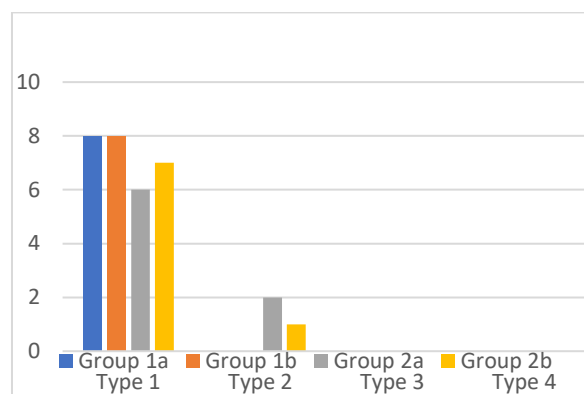
The two-way ANOVA results indicate that the interaction between restorative material type and cavity significantly affects fracture strength (F=19.68, p<0.001) (Table 2).

The highest average fracture resistance is observed in Group 2b (Vita Suprinity ZLS-MOD) (791.06±57.31), while the lowest

fracture resistance is found in Group 2a (Vita Suprinity ZLS-MO) ( $588.66 \pm 31.05$ ) (Table 3).

All samples exhibited repairable fractures in Group 1a (emo) and Group 1b (emod). However, in Group 2a (vmo), two samples showed irreparable fractures, whereas in Group 2b (vmod), one sample had an irreparable fracture (Table 4).

**Table 4:** Fracture type



## DISCUSSION

Using tooth-colored inlays as a restorative method offers several advantages, including high aesthetic value, good marginal fit, reduced tooth structure loss, and the preservation of more healthy dental tissue. Furthermore, advancements in CAD/CAM systems have made the clinical placement process of inlays more efficient and practical, significantly enhancing restoration quality and reducing patient visit duration. Therefore, this study aims to determine and compare the fracture strength and failure modes of lithium disilicate glass-ceramic and yttrium-stabilized zirconia-based ceramic MOD and MO inlay restorations.

Clinical research often requires five years or more. Due to high costs, researchers are often limited to a small sample population, and results may be incomplete due to variability within the patient population. When natural teeth are used, achieving standardization is challenging due to differences in size, mineralization percentage, anatomical configuration, variations in pulp size across different age stages, and internal

cracks in each tooth. Additionally, several parameters, such as the storage process of extracted teeth and the conditions under which selected teeth are extracted, can influence study outcomes when natural teeth are employed.<sup>11</sup> To obtain results closer to clinical conditions while investigating the fracture resistance of ceramics, the die material's elastic modulus needs to resemble that of natural teeth. Scherrer and de Rijk<sup>12</sup> reported that as the die material's elastic modulus increases, all-ceramic restorations' fracture strength also increases. Therefore, this study was conducted *in vitro* using models made from epoxy resin, which closely approximates the elastic modulus of natural teeth.

The existing literature has no consensus on the required fracture resistance for premolars with MO and MOD inlay restorations to ensure long-term success. Dental restorations routinely experience masticatory forces. The average forces applied during chewing range from 11 N to 150 N. In the anterior region, this value can reach up to 200 N, while in the posterior region, it can go up to 350 N. In cases of parafunctional habits, forces of up to 1000 N have been reported. Therefore, restorations in the posterior region must withstand these forces.<sup>13</sup> Our study found that the fracture resistance values of the tested restorations exceeded physiological masticatory forces. According to our results, the highest fracture strength was observed in Group 2b.

Keshvad and colleagues<sup>14</sup> compared the fracture resistance of 15 premolars restored with inlays made from leucite-reinforced ceramic IPS Empress CAD (Ivoclar et al.). They measured the maximum load at the moment of fracture as  $1050 \pm 763$  N.

Liu et al.<sup>15</sup> conducted an experiment using yttrium-stabilized zirconia-based ceramic to restore 16 molar teeth (divided into two groups: one with proximal boxes and one without). They reported a maximum load of  $1799.78 \pm 338.88$  N, with the group having

proximal boxes reporting  $2004.89 \pm 183.59$  N (n=8) at the point of fracture.

In a study conducted by Şener-Yamaner et al.,<sup>16</sup> they compared the average fracture resistance of 20 premolars restored with lithium disilicate ceramic inlays (IPS e.max CAD, Ivoclar Vivadent, Schaan, Liechtenstein). The lithium disilicate ceramic inlays group exhibited an average fracture resistance of  $2007 \pm 29.5$  N, while the intact teeth group showed  $2594 \pm 35.52$  N.

Soares et al.<sup>17</sup> reported that when subjected to a static load of 1675 N, the samples had an average survival rate of 93%.

Yoon et al.<sup>18</sup> tested small premolars with lithium disilicate ceramic inlays. After aging the specimens, they obtained an average load of  $661.85 \pm 302.95$  N using a universal testing machine, consistent with the results from Yoon et al.'s study. This study's findings differ from those of other studies, and we attribute this discrepancy to the use of small premolars.<sup>14-17</sup>

Al-Akhali et al.<sup>19</sup> found that polymer-based occlusal veneers significantly reduced the ultimate fracture strength due to thermomechanical fatigue. However, this reduction was not observed in lithium disilicate glass ceramics. According to Barakat et al.<sup>20</sup>, Vita Suprinity restorations exhibited statistically insignificant but higher average fracture resistance than E-max restorations. These observations highlight the significant role of zirconia particles in the crystallization process and the effects of added zirconia on fracture durability.<sup>21</sup> Similarly, this study showed no statistically significant difference in fracture resistance between the "ZLS VITA Suprinity PC" material and the "IPS e.max ZirCAD" material.

A 3D finite element analysis study demonstrated that the only cavity design is more effective in preserving tooth structure than the inlay design for adhesive-bonded lithium disilicate ceramic restorations.<sup>22</sup> Inlays with inappropriate distribution and high-stress levels

may render these restorations more prone to fracture and leakage.<sup>23</sup> In this study, three-surface cavities exhibited significantly higher fracture resistance than two-surface cavities. This could be because three-surface cavities allow for a more balanced distribution of forces. Consequently, stress on the restoration is more homogeneously distributed, leading to increased fracture resistance. In a study, they evaluated the stress distribution on models prepared in the remaining tooth tissue and observed that preserving the remaining tooth tissue increased the stress on the restoration while decreasing it on the tooth tissues.<sup>24</sup>

On the other hand, MOD caries are caries in which there is more tooth tissue loss than MO caries. The more tooth tissue loss, the more permanent the possibility of a tooth fracture. It should also be kept in mind that fractures in the tooth are more important than fractures in the restorative material.

In addition to fracture resistance, analyzing failure modes in samples was crucial for predicting restored teeth' clinical performance and prognosis. Some studies have indicated that restorations created without damaging the underlying tooth structure and cohesive fractures involving the cement layer are common.<sup>25,26</sup> Our study's results align with these observations.

However, this study has certain limitations. Firstly, the continuous vertical load must represent clinical applications more precisely. Furthermore, real-life masticatory cycles involve complex forces that subject ceramics to different axes (vertical and lateral). Cyclic loading may more accurately simulate fatigue failures observed in clinical practice. Clinical loading varies due to repeated exposure to minor forces, which can impact tooth restorations and lead to failure. One of the significant limitations of our study is that the specimens used were represented by alternative materials instead of natural teeth this limitation should be considered.

## CONCLUSION

1. A three-surface cavity design may further enhance the fracture resistance of inlay restorations, and this finding is statistically significant.
2. There is no significant difference in fracture strength among restorative materials.
3. Nearly all restorations achieved repairable failures.

## Ethical Approval

The necessary ethical approval for this study was received by the Afyonkarahisar Health Sciences University Non-Pharmaceutical and Medical Device Ethics Committee (Decision no: 2023/4).

## Financial Support

For this study, the financial support was taken from Afyonkarahisar Health Sciences University - Scientific Research Projects Coordination Unit. (Project No: 23. Genel.010)

## Conflict of Interest

The authors deny any conflicts of interest related to this study.

## Author Contributions

Design: RZE, KK, Data collection or data entry: RZM, KK, Analysis and interpretation: RZM, Literature review: RZM, KK, Writing: RZM.

## REFERENCES

1. Kelly JR, Nishimura I, Campbell SD. Ceramics in dentistry: historical roots and current perspectives. *J Prosthet Dent.* 1996;75:18-32.
2. Höland W, Beall G. Principles of designing glass-ceramic formation. *Glass-Ceramic Technology*, 2nd ed. Wiley: Hoboken, NJ, USA. 2012:39-72.
3. Turkaslan S, Bagis B, Akan E, Mutluay M, Vallittu P. Fracture strengths of chair-side-generated veneers cemented with glass fibers. *Niger J Clin Pract.* 2015;18:240-6.
4. Mörmann WH, Stawarczyk B, Ender A, et al. Wear characteristics of current aesthetic dental restorative CAD/CAM materials: two-body wear, gloss retention, roughness and Martens hardness. *J Mech Behav Biomed Mater.* 2013;20:113-25.
5. Giordano R. Materials for chairside CAD/CAM-produced restorations. *J Am Dent Assoc.* 2006;137:14s-21s.
6. Springall GAC, Yin L. Response of pre-crystallized CAD/CAM zirconia-reinforced lithium silicate glass ceramic to cyclic nanoindentation. *J Mech Behav Biomed Mater.* 2019;92:58-70.
7. Denry I, Kelly JR. Emerging ceramic-based materials for dentistry. *J Dent Res.* 2014;93:1235-42.
8. Springall GAC, Yin L. Nano-scale mechanical behavior of pre-crystallized CAD/CAM zirconia-reinforced lithium silicate glass ceramic. *J Mech Behav Biomed Mater.* 2018;82:35-44.
9. Ivoclar Vivadent AJLIV. Scientific documentation IPS e. max® Press. 2005.
10. Burke FJ. The effect of variations in bonding procedure on fracture resistance of dentin-bonded all-ceramic crowns. *Quintessence Int.* 1995;26:293-300.
11. Burke FJ. Maximising the fracture resistance of dentine-bonded all-ceramic crowns. *J Dent.* 1999;27:169-73.
12. Scherrer SS, de Rijk WG. The fracture resistance of all-ceramic crowns on supporting structures with different elastic moduli. *Int J Prosthodont.* 1993;6:462-7.
13. Yilmaz H, Aydin C, Gul BE. Flexural strength and fracture toughness of dental core ceramics. *J Prosthet Dent.* 2007;98:120-8.
14. Keshvad A, Hooshmand T, Asefzadeh F, et al. Marginal gap, internal fit, and fracture load of leucite-reinforced ceramic inlays fabricated by CEREC inLab and hot-pressed techniques. *J Prosthodont.* 2011;20:535-40.



15. Liu X, Fok A, Li H. Influence of restorative material and proximal cavity design on the fracture resistance of MOD inlay restoration. *Dent Mater.* 2014;30:327-33.
16. Sener-Yamaner ID, Sertgöz A, Toz-Akalin T, Özcan M. Effect of material and fabrication technique on marginal fit and fracture resistance of adhesively luted inlays made of CAD/CAM ceramics and hybrid materials. *Journal of Adhesion Science.* 2017;31:55-70.
17. Soares LM, Razaghy M, Magne P. Optimization of large MOD restorations: Composite resin inlays vs. short fiber-reinforced direct restorations. *Dent Mater.* 2018;34:587-97.
18. Yoon HI, Sohn PJ, Jin S, Elani H, Lee SJ. Fracture Resistance of CAD/CAM-Fabricated Lithium Disilicate MOD Inlays and Onlays with Various Cavity Preparation Designs. *J Prosthodont.* 2019;28:e524-e29.
19. Al-Akhali M, Kern M, Elsayed A, Samran A, Chaar MS. Influence of thermomechanical fatigue on the fracture strength of CAD-CAM-fabricated occlusal veneers. *J Prosthet Dent.* 2019;121:644-50.
20. Barakat O, Mohammed N. Effect Of Different Base Materials On The Micro Leakage And Fracture Resistance Of Recent Ceramic Inlay Restorations. 2019;65 (4-October (Fixed Prosthodontics, Dental Materials, Conservative Dentistry & Endodontics)):3805-16.
21. Willard A, Gabriel Chu TM. The science and application of IPS e.Max dental ceramic. *Kaohsiung J Med Sci.* 2018;34:238-42.
22. Yamanel K, Caglar A, Gülsahi K, Ozden UA. Effects of different ceramic and composite materials on stress distribution in inlay and onlay cavities: 3-D finite element analysis. *Dent Mater J.* 2009;28:661-70.
23. Dejak B, Mlotkowski A. A comparison of mVM stress of inlays, onlays and endocrowns made from various materials and their bonding with molars in a computer simulation of mastication - FEA. *Dent Mater.* 2020;36:854-64.
24. Tribst JPM, Dal Piva AMO, Madruga CFL, et al. Endocrown restorations: Influence of dental remnant and restorative material on stress distribution. *Dent Mater.* 2018;34:1466-73.
25. Ioannidis A, Mühlemann S, Özcan M, et al. Ultra-thin occlusal veneers bonded to enamel and made of ceramic or hybrid materials exhibit load-bearing capacities not different from conventional restorations. *J Mech Behav Biomed Mater.* 2019;90:433-40.
26. Maeder M, Pasic P, Ender A, et al. Load-bearing capacities of ultra-thin occlusal veneers bonded to dentin. *J Mech Behav Biomed Mater.* 2019;95:165-71.

# Marginal Bone Loss and Clinical Evaluation of Angled Implants: A Retrospective Study

Beyza ÖZTAŞ<sup>1\*</sup>  Doğan İlğaz KAYA<sup>2</sup> 

<sup>1</sup> Res. Ass., Karamanoglu Mehmetbey University, Ahmet Kelesoglu Faculty of Dentistry, Maxillofacial Surgery, Karaman, Türkiye, beyzadonmez@kmu.edu.tr

<sup>2</sup> Ass. Prof., Karamanoglu Mehmetbey University, Ahmet Kelesoglu Faculty of Dentistry, Maxillofacial Surgery, Karaman, Türkiye, doganilgaz@kmu.edu.tr

## Article Info

### Article History

Received: 30.06.2024

Accepted: 04.09.2024

Published: 15.10.2024

### Keywords:

Angled implant,  
Dental implant,  
Marginal bone loss.

## ABSTRACT

**Aim:** The volume of the edentulous crest and its proximity to critical anatomical structures are important limiting factors for implant surgery. Surgical procedures with complications can be avoided by placing angled implants. The aim of this clinical study was to evaluate marginal bone loss and the complications of angled implants.

**Materials and Methods:** Fifty-eight dental implants were examined in 32 patients (16 females, 16 males) with cone beam computed tomography (CBCT) images from patients with angled implants and complete edentation. The marginal bone loss in angled implants that were functional for 15 to 30 months was evaluated according to factors such as implant angle, connection type, opposing arch restoration type and planning of superstructure restoration. Marginal bone loss measurements were recorded from CBCT sections.

**Results:** It was determined that 3.44% of the implants placed had an inclination of less than 15°, 75.86% had an inclination between 15° and 30° and 20.68% had an inclination of more than 30°. While there was no marginal bone loss on the mesial and distal surfaces, the average marginal bone loss was 0.66 on the buccal surfaces and 0.93 in the lingual region. Only one of the implants examined failed. No pain or infection was observed in any of the implants examined.

**Conclusion:** According to the results of this retrospective clinical study, further clinical studies with larger sample sizes are needed to evaluate angled implants supported by full arch fixed prostheses as a predictable and valid treatment method in the prosthetic rehabilitation of edentulous jaws.

## Açılı Yerleştirilmiş İmplantların Marjinal Kemik Kaybı ve Klinik İncelenmesi: Retrospektif Çalışma

### Makale Bilgisi

#### Makale Geçmişi

Geliş Tarihi: 30.06.2024

Kabul Tarihi: 04.09.2024

Yayın Tarihi: 15.10.2024

#### Anahtar Kelimeler:

Açılı implant,  
Dental implant,  
Marjinal kemik kaybı.

### ÖZET

**Amaç:** Dişsiz kretin hacmi ve kritik anatomik yapılara komşuluğu, implant cerrahisinin önemli limitleyicilerdendir. Açılı implantlar yerleştirilerek komplikasyonlara sahip cerrahi işlemlerden kaçınılabilmektedir. Bu klinik çalışmanın amacı açılı yerleştirilmiş implantların marjinal kemik kaybını ve komplikasyonları değerlendirmektir.

**Gereç ve Yöntem:** Açılı implant yerleştirilmiş hastalardan konik ışınli bilgisayarlı tomografi (KİBT) görüntüleri bulunan, tam dişsizliğe sahip 32 hastada (16 kadın-16 erkek), 58 dental implant incelenmiştir. 15 ila 30 aylık süre boyunca fonksiyonda olan açılı implantlarda meydana gelen marjinal kemik kaybının implant açısı, bağlantı tipi, karşıt ark restorasyon tipi ve üst yapı restorasyonunun planlanması gibi faktörlere göre değerlendirilmesi yapılmıştır. Marjinal kemik kaybı ölçümü KİBT'tan alınan kesitlerden kaydedildi.

**Bulgular:** Yerleştirilen implantların %3,44'u 15° den daha az eğimli, % 75,86'ı 15° - 30° eğimleri arasında, %20,68'i 30° den fazla eğimde olduğu belirlenmiştir. Mesial ve distal yüzeylerde marjinal kemik kaybı yokken bukkal yüzeylerde ortalama 0,66 lingual bölgede 0,93'dür. İncelenen implantların sadece bir tanesinde başarısızlık gözlenmiştir. İncelenen hiçbir implantta ağrı, enfeksiyon gözlenmedi.

**Sonuç:** Bu retrospektif klinik çalışmanın sonuçlarına göre, tam dişsiz çenelerin protetik rehabilitasyonunda, tam ark sabit protezlerle desteklenen açılı implantların öngörülebilir ve geçerli bir tedavi yöntemi olarak değerlendirilebilmesi için daha büyük örneklem büyüklüğüne sahip ileri klinik çalışmalara ihtiyaç vardır.

**To cite this article:** Öztaş B, Kaya DI. Marginal Bone Loss and Clinical Evaluation of Angled Implants: A Retrospective Study. NEU Dent J. 2024;6(Special Issue):60-9. <https://doi.org/10.51122/neudentj.2024.116>

\*Corresponding Author: Beyza ÖZTAŞ, [beyzadonmez@kmu.edu.tr](mailto:beyzadonmez@kmu.edu.tr)



## **INTRODUCTION**

The use of implant-supported prostheses is increasing because they offer a permanent, successful and safe treatment option for patients with total and partial edentulism.<sup>1</sup> During implant placement, the treatment option is determined by looking at the quantity and quality of the alveolar crest. In cases with advanced resorption, maxillary sinus pneumatization, the presence of a nasal cavity adjacent to the implant placement sites, and proximity of the lower alveolar crest are characteristics of standard dental implant placement.<sup>2,3</sup> According to the original Brånemark System, implants should be placed at a parallel angle.<sup>4</sup> As stated in this system, patients with resorbed crests require long distal cantilever prostheses and bone augmentation to provide acceptable chewing capacity in the molar region with standard implant placement. However, cantilever extensions longer than 15 mm are known to be associated with increased implant failure rates.<sup>5</sup> Various treatment options, such as inferior alveolar nerve transposition and bone grafting techniques, can be used to avoid this problem.<sup>6,7</sup> These techniques have shown successful results in the long term. However, they cause various biological and technical disadvantages, such as morbidity at the graft recipient site, post-procedural discomfort, increased treatment time and difficulty of surgical procedure.<sup>8</sup>

Researchers have attempted to find suitable alternatives to the procedures described above to avoid the additional surgical procedures and complications that would be required to place standard straight implants in atrophic jaws.<sup>9</sup> In 1993, Dr Paulo Malo developed the "All-on-Four" concept, in which two parallel implants are placed on premaxilla and two implants are placed in the molar region at an angle of 35-40 degrees.<sup>10</sup> Angling the implants allows longer implants to be placed in the molar region. In addition,

placing the implants in this way increases the contact surface of the implants and leads to successful results in implant stability. The coronal parts of the implants are shifted more distally and the distance between the two implants increases compared to straight implants. As a result, the cantilever length of prosthetic restorations is reduced or may even disappear completely. This results in a more uniform and balanced force distribution in the anterior-posterior direction.<sup>11</sup> Although researchers and clinicians have reported that angled implants have been used with varying success over time, the efficacy and suitability of angled implants, particularly for the treatment of patients with severely resorbed alveolar bones, is still a matter of debate.<sup>2,8</sup> The purpose of this study was to evaluate the marginal bone loss level and clinical success of angled dental implants placed in edentulous areas. This study was designed according to the hypothesis that angulated implants used in edentulous jaws would have minimal marginal bone loss and a low complication rate.

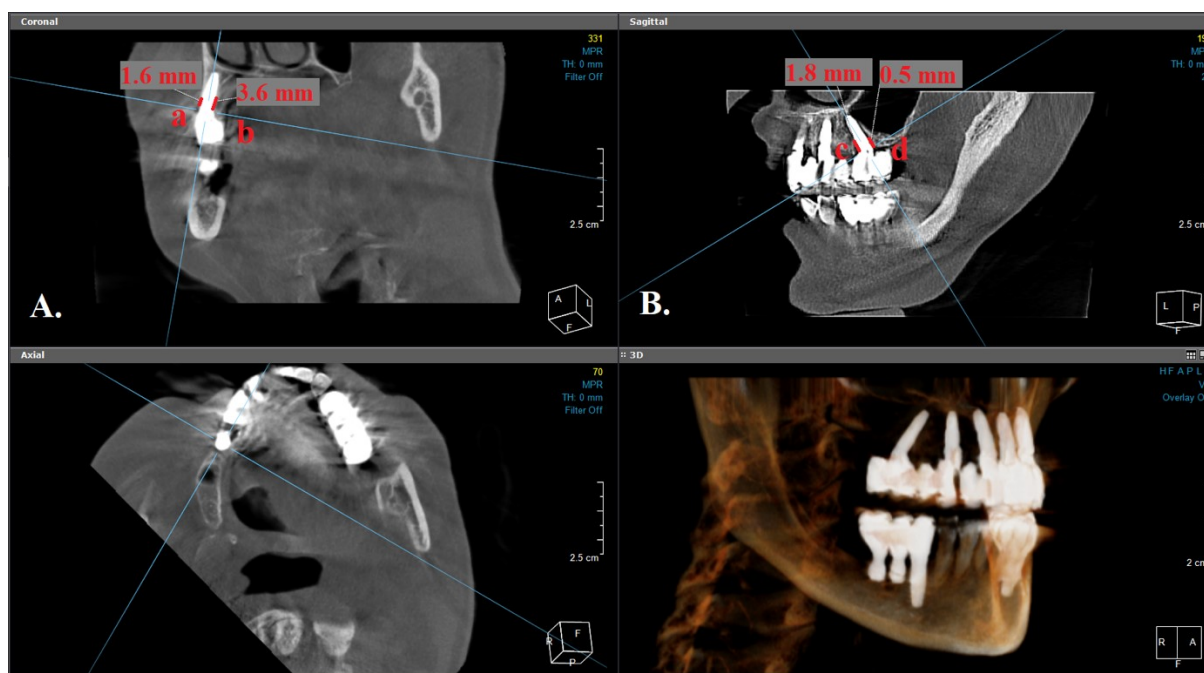
## **MATERIALS AND METHODS**

This paper was carried out with the permission of the 'Mehmetbey University Non-Pharmaceutical and Medical Device Ethics Committee dated 26.03.2024, with the permission being obtained by following up on the patients who received implant treatment at the Ahmet Keleşoğlu Faculty of Dentistry (Decision No: 03-2024/06). The study was designed retrospectively and was conducted in accordance with the 1975 Helsinki Declaration, as revised in 2013.

This research with 16-30 months follow-up was performed on 32 patients (58 implants) with complete edentulism in the maxilla and/or mandibula, aged between 25 and 67 years (mean:56). Inclusion criteria were patients older than 18 years of age, patients with no systemic contraindications to surgery, patients with edentulous jaws, patients

who would have required a bone grafting procedure for implant placement but who refused any bone grafting procedure and patients who had radiographic images immediately after the procedure and at follow-up sessions. Exclusion criteria included patients with bleeding problems, coagulation disorders, the presence of immune system diseases, uncontrolled diabetes mellitus, metabolic bone disease, patients who were pregnant or breastfeeding, and patients who had undergone radiotherapy to the maxillofacial region or had received chemotherapy within the last 12 years. The patients included in the study had angled dental implants performed in a two-stage procedure by the same surgeon (DIK). The angled placement of the implants was done free-hand, without using a guide. For this reason, cone beam computed tomography (CBCT) was taken after the procedure to check whether important anatomical structures close to the implant areas were damaged. Marginal bone loss was measured by two different maxillofacial surgeons (BO, DIK) using

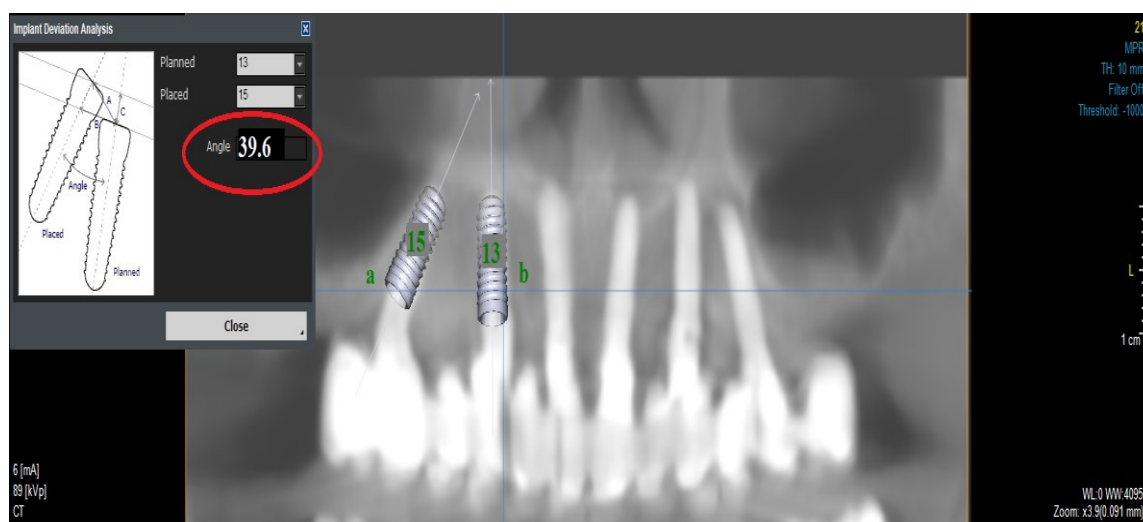
CBCT taken after the procedure and during the control session. In case of disagreement, it was re-evaluated and discussed, and the radiologist was consulted as a third researcher (SS). In case of disagreement, the measurements were re-evaluated and discussed, and the radiologist was consulted as a third researcher (SS). Consensus was achieved on the measurements. Radiological images were obtained with Kavo OP3d Pro (PaloDEX Group Oy, Tuusula, Finland) using the parameters of 90 kV, 8 mA exposure setting, exposure time 17.5-26.9 s, 13×15 cm field of view (FOV), and voxel size 0.320 mm. Calibration control was performed by comparing the actual length of the implant applied to the patient to the implant length measured on the radiograph. Marginal bone loss calculation was recorded by measuring the distance in mm between the implant neck level in the buccal, lingual, mesial and distal regions and the first point where the bone contacts the implant surface in cross-sectional sections taken from CBCT (Figure 1).



**Figure 1.** Marginal bone loss calculation was recorded by measuring the distance in mm between the neck level of the implant and the first point where the bone contacted the implant surface in cross-sectional sections taken from CBCT. A. In the coronal section, bone loss was measured in the buccal (a) and lingual (b) regions. B. In the sagittal section, bone loss in the mesial (c) and distal (d) regions was measured.

Implant angles were determined by calculating the angle between the long axes of two virtual implants placed using the implant

planning program (OnDemand3D version 1.0.7462 software, Cypermed Inc., Seoul, Republic of Korea). (Figure 2)



**Figure 2:** Implant angulation was determined by calculating the angle of the long axis of the two virtual implants (a, b) relative to each other using the tools in the implant planning programme (OnDemand).

An intraoral examination was performed to evaluate the clinical success criteria and possible complications of the implants. The criteria used to determine implant success were those proposed in the study of Buser et al.<sup>13</sup> and revised by Albrektsson and Zarb.<sup>14</sup> According to these criteria, the following conditions must be met for an implant to be successful: (1) Absence of sensory problems such as persistent pain, dysesthesia, or paresthesia at the implant site. (2) Absence of peri-implant infection with or without suppuration (inflammation). (3) Absence of implant mobility. (4) Absence of peri-implant bone resorption (>1.5 mm) within the first year after implant loading and persistent bone resorption (more than 0.2 mm/year) in subsequent years. Implants are considered successful if all of these criteria are met. In addition, other possible problems, such as soft tissue complications, significant bone loss, radiolucency (radiographic signs) around the implant and prosthesis-related complications, were recorded. An evaluation of the success rates and possible complications of implants was thus conducted.

### Statistical analysis

Firstly, demographic variables are presented with percentages. Numerical variables are summarized with means and standard deviations. The qualitative variables are shown with frequencies and percentages. For each parameter to be evaluated, normality analysis and the Kolmogorov-Smirnov test were performed for homogeneity of variances. For parameters that did not show normal distribution, the non-parametric Mann-Whitney U test and Kruskal-Wallis test were applied. For all analyses, a statistical significance level of 0.05 was used. Statistical analyses were performed using the IBM SPSS Statistics 20.0 computer program (IBM Corp. Released, 2011). IBM SPSS Statistics for Windows, Version 20.0. Armonk, NY: IBM Corp., USA).

### RESULTS

It was determined that 16 (50%) of the individuals included in the study were female and 16 (50%) were male. A total of 58 implants that were angled relative to the adjacent implant and met the inclusion criteria were identified (Table 1).

**Table 1:** Descriptive statistics

<b>Sex</b>			
Male		16(%50)	
Female		16(%50)	
<b>The arch where the implant is inserted</b>			
Maxilla		40(%68.9)	
Mandible		18 (%31.1)	
<b>Insertion Angle (°)</b>	26.2±6.1		24.9 [13-41.6]
<b>Diameter of the implant (mm)</b>	3.9±0.2		4.1 [3.5 -4.1]
<b>Length of Implant(mm)</b>	11±0.9		11 [10 -12]
<b>Connection Type</b>			
Multiunit		34 (%58.6)	
Cemented		24 (%41.4)	
<b>Follow-up Period(month)</b>	23.2±4.9		25 [16 -30]
<b>Opposite Arc Condition</b>			
Implant Mounted Restoration		40 (%68.9)	
Tooth		8 (%13.7)	
Crown and Bridge Restoration		10 (%17.4)	
<b>Number of Superstructure Parts</b>			
One Piece		42 (%72.4)	
2 Piece		12 (%20.6)	
3 Piece		4 (%7)	

Descriptive statistics are expressed as mean ± standard deviation or median [min -max] for numerical variables and (%) for categorical variables.

Of the implants placed, 4 were Straumann® (Straumann, Switzerland), 4 were Medentika® (Medentika, Germany) and 50 were NucleOSS (NucleOSS, Türkiye). Forty of the implants were in the maxilla and 18 were in the mandible. The average angle of the examined implants was 26.2±6.1 (min 13° max 41.6°), the average length was 11±0.9 (min 10 mm, max 12mm) and the average diameter was 3.9±0.2 (min 3.5 max 4.1). Thirty-four (58.6%) of the restorations were multiunit and 24 (41.4%) were of the cemented type. The mean follow-up period of the implants examined was determined as 23.2±4.9 months. Prosthetic restorations of implants placed in completely edentulous mouths were delivered in one piece (72.4%), two pieces (20.6%) and three pieces (7%). It was observed that 1 of the 58 implants examined did not osseointegrate after 3 months; therefore, this implant was renewed, while the remaining 57 implants were successful according to the success criteria of Buser and his team.<sup>12</sup> It was observed that two

implants underwent restoration renewal due to abutment implant connection screw fracture at the end of 14 months. Cheeping was observed in the prosthetic restorations of 8 of the 32 patients examined. While no pain or infection was observed in any of the 32 patients studied, decementation was observed in the restorations of 6 participants.

In the comparison of the marginal bone loss of angled implants placed in the maxilla or mandible, no statistically significant difference was found between the two groups ( $p>0.05$ ). When the implants examined were grouped according to their placement angles as  $<15^\circ$ ,  $15-30^\circ$  and  $>30^\circ$ , no statistically significant difference was found between the marginal bone loss in the groups ( $p>0.05$ ) (Table 2).

When the implants were classified according to the connection type with the prosthetic restoration (multiunit/cemented abutment) and the changes in marginal bone levels were examined, no statistically significant difference was found ( $p>0.05$ ).

**Table 2:** Descriptive statistics for the amount of marginal bone loss

	Implant Surfaces			
	Buccal	Lingual	Mesial	Distal
<b>Location Arc</b>				
Maxilla	0.48±1.19	0	0	0
Mandible	1±1.3	0.3±0.6	0	0
<b>p values</b>	0.295*	0.365*	0	0
<b>Insertion Angle</b>				
<15°	0	0	0	0
15-30°	0.8±1.3	0.07±0.3	0	0
>30°	0.2±0.6	0.1±0.4	0	0
<b>p values</b>	0.652**	0.609**	0	0
<b>Connection Type</b>				
Multiunit	0.7±1.2	0.1±0.4	0	0
Cemented	0.5±1.3	0	0	0
<b>p values</b>	0.711*	0.616*	0	0
<b>Opposite Arc Condition</b>				
Implant Mounted Restoration	0.3±0.8	0.05±0.2	0	0
Tooth	1.5±1.7	0.4±0.8	0	0
Crown and Bridge Restoration	1.3±1.8	0	0	0
<b>p values</b>	0.138**	0.266**	0	0
<b>Number of Superstructure Parts</b>				
One Piece	0.5±1.1	0.1±0.4	0	0
2 Piece	1.1±1.7	0	0	0
3 Piece	0	0	0	0
<b>p values</b>	0.545**	0.674**	0	0

Mann Whitney U \* Kruskal Wallis \*\* Descriptive statistics are presented as mean ± standard deviation.

When marginal bone loss was compared with the prosthetic restoration of the implant placed at an angle in occlusion according to the opposing arch condition (tooth, fixed crown bridge restoration, implant-supported restoration), no correlation

was found. ( $p > 0.05$ ) There was no statistical difference between the number of pieces of the prosthetic restoration and marginal bone loss ( $p > 0.05$ ) (Table 3).

**Table 3:** Descriptive statistics for the amount of marginal bone loss

	Implant Surfaces			
	Buccal	Lingual	Mesial	Distal
<b>Follow-up Period(month)</b>				
12-19 month	0.2±0.6	0.1±0.4	0	0
20-27 month	1.3±1.5	0.1±0.4	0	0
28-36 month	0	0	0	0
<b>p value</b>				
12-18 month / 26- 36 month	0.562**	0.473**	0	0
12 -18 month / 19 -25 month	<b>0.010**</b>			
19 -25 month / 26 -36 month	0.113**			

Kruskal Wallis \*\* Descriptive statistics are presented as mean ± standard deviation. P value in bold indicates a statistically significant difference ( $p < 0.05$ ).

According to the results of the study, the relationship between marginal bone loss at the 36-month follow-up was found to be of low statistical significance ( $p < 0.05$ ). Marginal bone losses evaluated in the 12-

19/20-27/28-36 follow-up periods did not show statistically significant differences on the lingual, mesial or distal surfaces ( $p > 0.05$ ). Marginal bone loss on the buccal surface differed significantly between 20-27 and 28-36 months ( $p = 0.010$ ).

## DISCUSSION

Pneumatization of the maxillary sinus and inferior alveolaris nerve can create anatomical limitations due to bone loss in toothless jaws, which can create difficulties when placing standard implants. This challenge increases the incentive to use angled implants, an alternative surgical technique.<sup>14</sup> While angled implants are applied mesially or distally to the borders of the maxillary sinus in the maxilla, they can be placed in the area between the mental foramen in the mandible. These angled implants are used to overcome anatomical difficulties and increase implant stability.<sup>15</sup> This approach aims to minimize anatomical restrictions caused by bone loss, reduce patient discomfort and costs and optimize the treatment process.<sup>16</sup> In this study, the clinical success of implants and marginal bone loss after fixed prosthetic restoration loading were evaluated in patients who had angled implants placed for different reasons.

The survival rate of the implant is an important success parameter in implant treatment. In the current study, 1 out of 58 angled implants evaluated had implant loss, resulting in a survival rate of 98.3%. A single implant loss occurred before the prosthesis was loaded and an angled implant was replaced in the adjacent area. No loss was observed in the implant loaded with the prosthesis. Charnavic et al. found implant loss in 82 (1.63%) of the 5029 angled implants they examined in a meta-analysis.<sup>17</sup> This data showed results compatible with the present study. Similarly, Pomares et al.<sup>18</sup> and Maló et al.<sup>19,20</sup> reported a survival rate of 93%–100% during their follow-up period in their studies on angled implants. Considering these studies, angled dental implants can be regarded as a good alternative in the long term due to their low risk of complications in atrophic jaws and high survival rates.

Marginal bone loss around dental implants plays a critical role in determining the effectiveness of implant treatment.<sup>21</sup> A review of the literature reveals that periapical and panoramic radiographs are frequently used to determine marginal bone loss.<sup>22</sup> Periapical radiographs taken with the parallel technique are considered to be a reliable measurement method for detecting marginal bone loss.<sup>23</sup> However, conventional two-dimensional (2D) intraoral radiographs are inadequate for buccal/lingual bone imaging.<sup>22</sup> When compared with different marginal bone loss measurement methods *in vitro* and *in vivo*, CBCT has been reported to be quite accurate in measuring buccolingual width.<sup>23,24</sup>

In this research study, a retrospective study was designed using postoperative cone beam computed tomography (CBCT) images to evaluate the relationship of angled implants with adjacent anatomical structures and adjacent implants.

Barnea et al. found that the degree of angulation was significantly associated with marginal bone loss for angled implants.<sup>25</sup> Each additional 10° of implant angle was associated with 0.6 mm of marginal bone loss. Rosen and Gynther recorded a 97% success rate with the placement of 103 curved implants in a study with up to 12 years of follow-up.<sup>26</sup> The mean marginal bone loss was 1.2 mm. These authors produced angled implants in resorbed jaws as an alternative to bone grafting. In this study, no significant difference was observed in the evaluation of implants with different angles in terms of marginal bone loss.

In the control sessions of the patients included in the study, porcelain fracture was the most common condition compared to other factors. In a prospective study conducted by Krennmair et al., they found porcelain fractures in the prostheses of 10 out



of 24 patients following prosthetic restorations supported by angled implants.<sup>27</sup> Chochlidakis K. et al.<sup>28</sup> also examined the prosthetic complications of implant-supported restorations in their study and stated that the most common situation encountered was porcelain fracture in prostheses. In this study, porcelain fractures were detected in 8 of the 32 patients examined. This result may be due to the lack of standardization in the clinical and laboratory processes of the restoration or the fact that it was not applied by the same physician, which seems to be consistent with the literature.<sup>28</sup>

Marginal bone losses evaluated in the follow-up periods in the study did not show statistically significant differences on the lingual, mesial or distal surfaces. This result was found to be supported by other studies in the literature.<sup>17,26</sup> However, marginal bone loss on the buccal surface differed significantly at 20-27 and 28-36 months, which may be associated with inadequate buccolingual bone thickness.

Repeated CBCT scans may lead to an increase in the total radiation dose, which may increase health risks in the long term.<sup>29</sup> In addition, repeated CBCT scans may increase radiation exposure, which may not be clinically necessary in most cases.<sup>30</sup> As stated in our study, since implants were applied without using a guide, CBCT scans were performed immediately after the procedure to check whether important anatomical structures were damaged. In addition, a single CBCT image is used in control sessions if the physician requires it. In our study, only patients who had CBCT records taken at two different periods were evaluated.

Cone beam computed tomography images may vary depending on technical parameters. Artifacts may occur in the images

due to scattering from high-density metal around the dental implant, which may pose difficulties in measuring accuracy.<sup>21</sup> Incorrect measurements may be made as a result. Our study has some limitations and these need to be addressed in future research. First of all, longer follow-up periods are needed to better understand the long-term results of angled implants. Secondly, to confirm the findings of the present study and improve the generalizability of the results, future studies ought to be carried out with larger sample groups.

In measurements using CBCT, artifacts originating from high-density materials may affect measurement accuracy. Standardization of imaging protocols and the use of advanced image processing techniques may help to overcome this problem. Variability in prosthetic restoration techniques and lack of standardization in clinical and laboratory processes are also significant limitations. The frequent occurrence of prosthetic complications, such as porcelain fracture, in our study is evidence of this. Standardization of prosthetic procedures and ensuring consistency among different practitioners may increase the reliability of results.

## **CONCLUSION**

Within the limitations of the study, angled dental implants can be used successfully in cases requiring additional surgical bone augmentation with insufficient alveolar bone height to accommodate long dental implants. In conclusion, although angled implants appear to have a high success rate in the short term, longer follow-up periods, larger sample groups, standardized imaging and prosthetic procedures would increase the reliability and validity of future studies.

## Ethical Approval

The necessary ethical approval for this study was received by the Karamanoğlu Mehmetbey University Non-Pharmaceutical and Medical Device Ethics Committee (Decision no: 03-2024/06).

## Financial Support

No financial support was received from any institution or organization for this study.

## Conflict of Interest

The authors deny any conflicts of interest related to this study.

## Author Contributions

Design: BÖ, DIK, Data collection or data entry: BÖ, Analysis and interpretation: DIK, BÖ, Literature review: BÖ, DIK, Writing: BÖ.

## REFERENCES

1. Lemos CA, Ferro-Alves ML, Okamoto R, Mendonça MR, Pellizzer EP. Short dental implants versus standard dental implants placed in the posterior jaws: a systematic review and meta-analysis. *J Dent*. 2016;47:8-17.
2. Malo P, de Araújo Nobre M, Lopes A, Moss SM, Molina GJ. A longitudinal study of the survival of All-on-4 implants in the mandible with up to 10 years of follow-up. *J Am Dent Assoc*. 2011;142:310-20.
3. Chrcanovic BR, Kisch J, Larsson C. Analysis of technical complications and risk factors for failure of combined tooth-implant-supported fixed dental prostheses. *Clin Implant Dent Relat Res*. 2020;22:523-32.
4. Ramezanzade S, Aeinehvand M, Khurshid Z, Keyhan SO, Fallahi HR, Abbasi A. Treatment options for oral rehabilitation of the atrophic maxilla: a literature review. *Avicenna J Dent Res*. 2023;15:122-33.
5. Schmid E, Rocuzzo A, Morandini M, Ramseier CA, Sculean A, Salvi GE. Clinical and radiographic evaluation of implant-supported single-unit crowns with cantilever extension in posterior areas: a retrospective study with a follow-up of at least 10 years. *Clin Implant Dent Relat Res*. 2021;23:189-96.
6. Vinci R, Teté G, Lucchetti FR, Capparé P, Gherlone EF. Implant survival rate in calvarial bone grafts: a retrospective clinical study with 10-year follow-up. *Clin Implant Dent Relat Res*. 2019;21:662-8.
7. Eshaweirf E, Sougei A. Short dental implants versus standard dental implants placed in the posterior jaws. *Int J Med Arts*. 2023;5:3572-82.
8. Gherlone EF, D'Orto B, Nagni M, Capparé P, Vinci R. Tilted implants and sinus floor elevation techniques compared in posterior edentulous maxilla: a retrospective clinical study over four years of follow-up. *NATO Adv Sci Inst Ser E Appl Sci*. 2022;12:6729.
9. Del Fabbro M, Pozzi A, Romeo D, de Araújo Nobre M, Agliardi E. Outcomes of fixed full-arch rehabilitations supported by tilted and axially placed implants: a systematic review and meta-analysis. *Int J Oral Maxillofac Implants*. 2022;37:1003-25.
10. Asawa N, Bulbule N, Kakade D, Shah R. Angulated implants: an alternative to bone augmentation and sinus lift procedure: a systematic review. *J Clin Diagn Res*. 2015;9:ZE10-ZE13.
11. De Vico G, Bonino M, Spinelli D, Schiavetti R, Sannino G, Pozzi A, et al. Rationale for tilted implants: FEA considerations and clinical reports. *Oral Implantol*. 2011;4:23-33.
12. Buser HP, Dula K, Lang NP. Tissue integration of non-submerged implants: 1-year results of a prospective study with 100 ITI hollow-screw and hollow-cylinder implants. *Clin Oral Implants Res*. 1990;1:33-40.
13. Albrektsson T, Zarb GA. Determinants of correct clinical reporting. *Int J Prosthodont*. 1998;11:355-61.
14. Agliardi E, Panigatti S, Clericò M, Villa C, Malò P. Immediate

- rehabilitation of the edentulous jaws with full fixed prostheses supported by four implants: interim results of a single cohort prospective study. *Clin Oral Implants Res.* 2010;21:459-65.
15. Ata-Ali J, Peñarrocha-Oltra D, Candel-Marti E, Peñarrocha-Diago M. Oral rehabilitation with tilted dental implants: a meta-analysis. *Med Oral Patol Oral Cir Bucal.* 2012;17:7.
  16. Sharaf MA, Wang S, Mashrah MA, Xu Y, Haider O, He F. Outcomes that may affect implant and prosthesis survival and complications in maxillary fixed prosthesis supported by four or six implants: a systematic review and meta-analysis. *Heliyon.* 2024;10:e24365.
  17. Chrcanovic BR, Albrektsson T, Wennerberg A. Tilted versus axially placed dental implants: a meta-analysis. *J Dent.* 2015;43:149-70.
  18. Pomares C. A retrospective clinical study of edentulous patients rehabilitated according to the “all on four” or the “all on six” immediate function concept. *Eur J Oral Implantol.* 2009;2:55-60.
  19. Maló P, Rangert B, Nobre M. All-on-4 immediate-function concept with Brånemark System implants for completely edentulous maxillae: a 1-year retrospective clinical study. *Clin Implant Dent Relat Res.* 2005;7:1-94.
  20. Maló P, de Araújo Nobre M, Lopes A, Francischone C, Rigolizzo M. “All-on-4” immediate-function concept for completely edentulous maxillae: a clinical report on the medium (3 years) and long-term (5 years) outcomes. *Clin Implant Dent Relat Res.* 2012;14:1-50.
  21. Pelekos G, Acharya A, Tonetti MS, Bornstein MM. Diagnostic performance of cone beam computed tomography in assessing peri-implant bone loss: a systematic review. *Clin Oral Implants Res.* 2019;29:443-64.
  22. González-Martín O, Oteo C, Ortega R, Alandez J, Sanz M, Veltri M. Evaluation of peri-implant buccal bone by computed tomography: an experimental study. *Clin Oral Implants Res.* 2016;27:950-5.
  23. Misch KA, Yi ES, Sarment DP. Accuracy of cone beam computed tomography for periodontal defect measurements. *J Periodontol.* 2006;77:1261-6.
  24. Li F, Jia PY, Ouyang XY. Comparison of measurements on cone beam computed tomography for periodontal intrabony defect with intra-surgical measurements. *Chin J Dent Res.* 2015;18:171-6.
  25. Barnea E, Tal H, Nissan J, Tarrasch R, Peleg M, Kolerman R. The use of tilted implants for posterior atrophic maxilla. *Clin Implant Dent Relat Res.* 2016;18:788-800.
  26. Rosén A, Gynther G. Implant treatment without bone grafting in edentulous severely resorbed maxillas: a long-term follow-up study. *J Oral Maxillofac Surg.* 2007;65:1010-6.
  27. Krennmair S, Seemann R, Weinländer M, Krennmair G, Piehslinger E. Immediately loaded distally cantilevered fixed mandibular prostheses supported by four implants placed in both fresh extraction and healed sites: 2-year results from a prospective study. *Eur J Oral Implantol.* 2014;7:73-84.
  28. Chochlidakis K, Einarsdottir E, Tsigarida A, Papaspyridakos P, Romeo D, Barmak AB, et al. Survival rates and prosthetic complications of implant fixed complete dental prostheses: an up to 5-year retrospective study. *J Prosthet Dent.* 2020;124:539-46.
  29. Aanenson JW, Till JE, Grogan HA. Understanding and communicating radiation dose and risk from cone beam computed tomography in dentistry. *J Prosthet Dent.* 2018;120:353-60.
  30. Pauwels R. Cone beam CT for dental and maxillofacial imaging: dose matters. *Radiat Prot Dosimetry.* 2015;165:156-61.

# Evaluation of Shear Bond Strength of Universal Adhesives to Dentin: in Vitro Study

Irem Kubra CAL<sup>1\*</sup>  Fatma OZTURK<sup>2</sup>   
Numan AYDIN<sup>3</sup>  Serpil KARAOĞLANOĞLU<sup>4</sup> 

<sup>1</sup> Res. Ass., Health Science University, Faculty of Dentistry, Ankara, Türkiye, iremmkubraa@gmail.com

<sup>2</sup> Res. Ass., Health Science University, Faculty of Dentistry, Ankara, Türkiye, ozt-fatma@hotmail.com

<sup>3</sup> Ass. Prof., Health Science University, Faculty of Dentistry, Ankara, Türkiye, dt\_numan@hotmail.com

<sup>4</sup> Prof., Health Science University, Faculty of Dentistry, Ankara, Türkiye, skaraoglanoglu2@yahoo.com

Article Info	ABSTRACT
<b>Article History</b> <b>Received:</b> 30.06.2024 <b>Accepted:</b> 04.09.2024 <b>Published:</b> 15.10.2024	<b>Aim:</b> Universal adhesives are widely used in restorative dentistry. The aim of this study was to evaluate the shear bond strength (SBS) of universal adhesives to dentin in different application modes. <b>Materials and Methods:</b> The study utilized seven universal adhesives and one total-etch adhesive. The sixty-four extracted intact human molars used in the study were embedded in acrylic blocks to the enamel-cement junction. The occlusal surface was removed to expose the dentin surface. After applying self-etch and total-etch adhesives to the dentin, flowable composite (Clearfil Majesty Flow, Kuraray) was placed in a transparent mold (2.38 mm diameter and 2 mm height) and polymerized. After thermal aging (1000 cycles), a SBS test has been carried out on a universal testing machine. The fracture types formed on the surface of the teeth were examined under a microscope. Data were analyzed by two-way analysis of variance (ANOVA) test ( $p<0.05$ ). <b>Results:</b> SBS values of universal adhesives on dentin showed statistically significant differences according to adhesive and application mode ( $p<0.05$ ). Total-etch application produced statistically higher SBS than self-etch application ( $p<0.05$ ). The two-step universal adhesive (G2 Bond Universal) had the highest SBS in both the self-etch and total-etch application modes ( $p<0.05$ ). When the bond surfaces of the universal adhesives were examined, fractures occurred most frequently in the adhesive type. <b>Conclusion:</b> The use of universal adhesives in the total-etch mode results in greater bond strength to dentin tissue. Universal adhesive type influences bond strength.
<b>Keywords:</b> Adhesion, Adhesive, Shear strength.	

## Üniversal Adezivlerin Dentine Makaslama Bağ Dayanımının İncelenmesi: İn Vitro Çalışma

Makale Bilgisi	ÖZET
<b>Makale Geçmişi</b> <b>Geliş Tarihi:</b> 30.06.2024 <b>Kabul Tarihi:</b> 04.09.2024 <b>Yayın Tarihi:</b> 15.10.2024	<b>Amaç:</b> Üniversal adezivler restoratif diş hekimliğinde yaygın olarak kullanılmaktadır. Bu çalışmanın amacı, üniversal adezivlerin dentine makaslama bağlanma dayanımını farklı uygulama modlarında değerlendirmektir. <b>Gereç ve Yöntemler:</b> Çalışmada 7 adet üniversal ve 1 adet total-etch adeziv kullanıldı. Çalışmada kullanılacak 64 adet çekilmiş sağlam insan molar dişi mine-sement sınırına kadar akrilik bloklara gömüldü. Dişler, dentin yüzeyini açığa çıkaracak şekilde okluzal yüzeyden aşındırıldı. Dentin dokusu üzerine adezivler self-etch ve total-etch modda uygulandıktan sonra şeffaf bir kalıp (2,38 mm çap ve 2 mm yükseklik) içerisinde akıcı kompozit (Clearfil Majesty Flow, Kuraray) konularak polimerize edildi. Termal yaşlandırma (1000 siklus) işleminden sonra üniversal test cihazında makaslama bağ dayanım testi yapıldı. Dişlerin yüzeyinde oluşan kırık tipleri mikroskop altında incelendi. Çalışmada veriler iki yönlü varyans analiz (ANOVA) testi kullanılarak değerlendirildi ( $p<0,05$ ). <b>Bulgular:</b> Üniversal adezivlerin dentin üzerindeki makaslama bağ dayanım değerleri adeziv ve uygulama moduna göre istatistiksel anlamlı farklılıklar gösterdi ( $p<0,05$ ). Total-etch uygulama self-etch uygulamadan istatistiksel olarak daha fazla makaslama bağ dayanım gücü oluşturdu ( $p<0,05$ ). İki aşamalı üniversal adeziv (G2 Bond Universal) self-etch ve total-etch uygulama modunda en fazla makaslama bağ dayanımı gösterdi ( $p<0,05$ ). Üniversal adezivlerin bağlantı yüzeyleri incelendiğinde en fazla adeziv tipte kırık görüldü. <b>Sonuç:</b> Üniversal adezivlerin total-etch modda kullanılması dentin dokusu üzerinde daha fazla bağlantı gücü oluşturmaktadır. Üniversal adeziv tipi bağlantı gücü üzerinde etkilidir.
<b>Anahtar Kelimeler:</b> Adezyon, Adeziv, Makaslama dayanımı.	

**To cite this article:** Cal IK, Öztürk F, Aydın N, Karaoğlanoğlu S. Evaluation of Shear Bond Strength of Universal Adhesives to Dentin: in Vitro Study, NEU Dent J. 2024;6(Special Issue):70-8. <https://doi.org/10.51122/neudentj.2024.117>

**\*Corresponding Author:** Irem Kubra CAL, [iremmkubraa@gmail.com](mailto:iremmkubraa@gmail.com)



This article is licensed under a Creative Commons Attribution-NonCommercial 4.0 International License (CC BY-NC 4.0)

## INTRODUCTION

Today, restorative dentistry tends to focus on the complete removal of carious tissue while avoiding the removal of healthy tooth structure to improve mechanical retention. Adhesion is the cornerstone of modern restorative dentistry.<sup>1</sup> Adhesive systems are used to provide a long-lasting bond between the tooth and resin-based materials.<sup>2</sup> These systems act as a mediating material in the restoration, increasing retention, marginal sealing and tooth-restoration interface resistance.<sup>3</sup>

Adhesive systems can be divided into two main categories based on the method of application to the tooth surface: total-etch and self-etch.<sup>4,5</sup> Acidifying enamel partially demineralizes hydroxyapatite, thus exposing enamel prisms that facilitate micro-attachment. For dentin, superficial hydroxyapatite is dissolved and the smear layer and smear plugs are removed after rinsing. Phosphoric acid (35-37%) is often used as an etching agent for total etch systems<sup>2</sup> and these systems involve the prior application of phosphoric acid.<sup>5,6</sup> Therefore, total-etch adhesives can be applied in three steps (etching, primer and adhesive) or in two steps (primer and adhesive combined in one material).<sup>7</sup>

Although total etch adhesives are still the gold standard, the current trend is towards the development of simplified self-etch materials.<sup>7</sup> Self-etch adhesives can be two or one-step depending on the primer and adhesive resin.<sup>5,8</sup> The application is simplified by combining all components (acid, primer and adhesive resin) in a single material.<sup>9,10</sup> Functional and base monomers, solvents and initiators, and optional fillers are included in these "universal" adhesives. It is difficult to stabilize all these different components in a single bottle while maintaining their bonding ability.<sup>2</sup> These systems are designed by the manufacturers to allow the dentist to decide which bonding technique to use in relation to

the choice of the bonding procedure and the number of steps.<sup>7</sup> The term "universal" indicates that these adhesives can be used in all modes of application, such as self etch, total etch and selective etch (selective enamel etching).<sup>2</sup>

Despite the advances made in adhesive technology, there are still unresolved issues regarding the durability of the adhesive interface.<sup>11</sup> It is still difficult to achieve a sealed connection between the resin and the dentin substrate, and it is doubtful that ideal interdiffusion of the adhesive system within the collagen scaffold can be achieved.<sup>12,13</sup> Although an adequate resin-dentin connection is usually achieved immediately, a decrease in the strength of the bond occurs over time.<sup>14</sup> As a result, the actual mechanisms of failure are not fully understood. In this sense, it is necessary to follow the recommendations of each company; otherwise, adhesive degradation may occur.<sup>15</sup>

Adhesion performance depends on many factors and may vary depending on the adhesive system used. Universal adhesives have the advantages of being simple, fast to apply and requiring less precision in technique. The stability and durability of the dentin-adhesive interface created by universal adhesive systems continues to be questioned. One of the major concerns with these systems is the increase in microleakage after aging, leading to limited bond strength. The lack of a standardized protocol to ensure stable and optimal adhesion of universal adhesive systems to dentin is a major problem. Furthermore, improvement of bond strength can be achieved by a multitude of methods.<sup>13</sup>

Despite the improved materials, it is still an important question whether clinicians should consider using these new adhesives with total-etch rather than self-etch.<sup>7</sup> Which adhesive protocol is optimal for universal adhesives cannot be answered definitively

based on the available clinical evidence and the short follow-up times evaluated.<sup>13</sup>

Furthermore, manufacturers use different combinations of components in universal adhesives; therefore, comparisons of available adhesives are difficult. Furthermore, studies comparing the SBS of different commercially available universal adhesives are scarce in the literature.<sup>2</sup>

The aim of this study was to contribute to the literature by investigating the SBS of universal adhesives to dentin in self-etch and total-etch mode.

## MATERIALS AND METHODS

Ethical approval for this study was obtained from Gülhane University of Health Sciences Pharmaceutical and Medical Received by off-device ethics committee (2024/284).

The SBS of a composite (Clearfil Majesty Flow, Kuraray) bonded to human dentin using seven different universal adhesive systems will be tested. A total-etch adhesive system (Prime&Bond NT, Dentsply) was used as the control group (Table 1). Sample size was determined using G-Power analysis software with a large effect size, 0.05 error level, and 80% power.

**Table 1:** Contents of the adhesive systems used

Adeziv Sistemler	İçindekiler	pH	Lot No
<b>G2-Bond Universal (GC, Tokyo, Japan)</b>	Two-step Universal Adhesive Primer: 4-MET, 10-MDP, 10-MDTP, dimethacrylate monomer, acetone, water, initiators, fillers Adhesive: dimethacrylate monomer, Bis-GMA, filler, photoinitiator	1.5	1110251
<b>Optibond Universal (Kerr, Schaumburg, USA)</b>	GPDM, glycerol dimethacrylate, HEMA, acetone, ethanol	2.3	9448958
<b>Bond Force II (Tokuyama, Japan)</b>	Phosphoric acid monomer, Bis-GMA, TEGDMA, 2-Hydroxyethyl methacrylate HEMA, Camphorquinone, alcohol and purified water.	2.8	138E52
<b>Prime&amp;Bond NT (Dentsply Sirona, Germany)</b>	Urathane dimetacrylate (UDMA), trimethacrylate, phosphoric acid modified acrylate resin (PENTA), highly dispersed silicon dioxide, camphorquinone, ethyl-4(dimethylamino) benzoate (photoaccelerator), butylated hydroxy toluene (BHT), cetylamine hydrofluoride, acetone	2.1	2205000548
<b>G-Premio Bond Universal (GC, Tokyo, Japan)</b>	MDP, 4-MET, MEPS, methacrylate monomer, acetone, water, initiator, silica	2.1	2202021
<b>Clearfil Tri-S Bond Universal (Kuraray Noritake, Tokyo, Japan)</b>	10-MDP, Bis-GMA, HEMA, colloidal silica, silane, sodium fluoride, camphoquinone, ethanol, water	2.5	1P0065
<b>Prime&amp;Bond Universal (Dentsply Sirona, Germany)</b>	10-MDP, bisacrylamide monomers, PENTA, isopropanol, water, initiator, stabilizer	2.5	2112000750
<b>Gluma Bond Universal (Kulzer, Hanau, Germany)</b>	UDMA, MDP, 4-META, HEMA, acetone, water, photo initiators, stabilizers	1.5	M010058

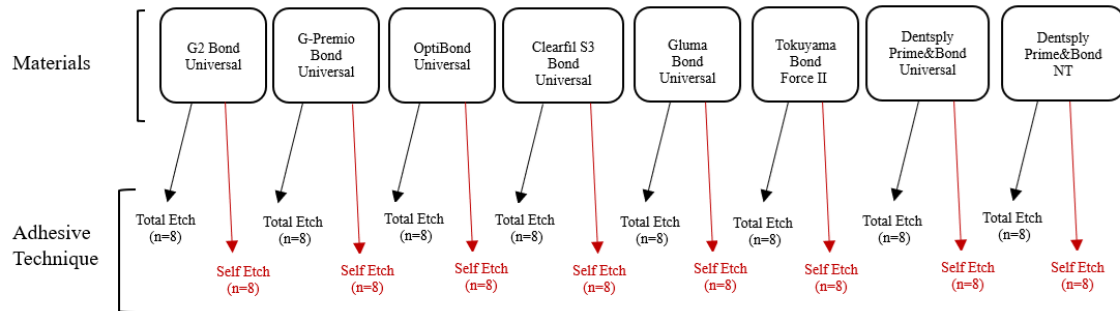
### Preparation of Samples

Sixty-four extracted caries-free wisdom teeth were used in the study. The teeth were kept in +4 degree distilled water after removal of calculus and soft tissues. The teeth embedded in acrylic blocks up to the enamel-cementum boundary were abraded from the occlusal surface perpendicular to the long axis of the tooth, leaving the dentin surface exposed. A 600-grit silicon carbide

(SiC) abrasive was applied to the abraded tooth surface for 1 minute under water to obtain a standardized smear layer on the specimens and to smooth the dentin surface. This surface was divided into two sections by marking the center mesially and distally with a bur, then rinsed with water and gently dried with oil-free air. The mesial half of the surface was treated with 35% phosphoric acid (K-ETCHANT Syringe, Kuraray) for 15 s while the distal half was not treated with acid. It was then rinsed for 15 s and dried again

using oil-free air. Adhesives were applied on the prepared surface in total-etch mode on the mesial part and self-etch mode on the distal part and polymerized with light (Q-Light, Woodpecker, Germany) for 30 s.

As shown in the figure, this study planned eight sample groups according to material type and two subgroups within each group including adhesive procedures (Figure 1).




**Figure 1:** Groups, sample numbers and adhesive application methods

Then, a flowable composite (Clearfil Majesty Flow, Kuraray) was placed in a transparent mold (2.38 mm diameter and 2 mm height) and light polymerized for 30 seconds. Adhesive systems have been applied according to user instructions. The specimens were post-polymerized in water at 37 degrees for a day and then aged. (Moddental- 1000 cycles) The temperature settings for the ageing baths were 5°C and 55°C. Immersion time in each bath was planned as 30 s and

transfer time as 5 s.

**SBS Test**

The SBS test was performed on a universal testing machine (H5KS Redhill, UK) at a crosshead speed of 1 mm/min until specimen fracture. The force required for debonding was obtained in Newtons (N) and converted to megapascals (MPa) by dividing by the surface area of the composite material. (Figure 2)



**Figure 2:** Schematic representation of sample preparation

**Microscopic Analysis**

Fracture surfaces were examined with (Leica MZ 12, Leica, Germany). If the fracture line is between the tooth and the composite cylinder, the fracture mode is

classified as adhesive. If the fracture line partially extends across the adhesive interface and penetrates one of the substrates, the fracture mode is classified as mixed, so we distinguish mixed fracture mode in dentin or composite (depending on which substrate it

covers). If more than 75% of the adhesive area contains dentin or composite, the fracture mode is classified as cohesive.

### Statistical Analysis

SPSS 22.0 (SPSS Inc., Chicago, IL, USA) program was used to analyze the SBS data. The normality distribution of the SBS data obtained from the study was performed by Kolmogorov-Smirnov test. Normally distributed SBS data were evaluated using two-way analysis of variance (ANOVA) and post hoc Tukey test ( $p < 0.05$ ).

### RESULT

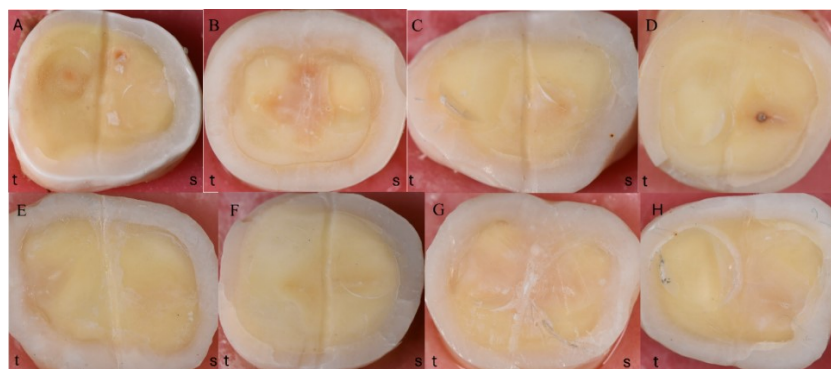
SBS findings are presented in Table 2. SBS values of universal adhesives on dentin showed statistically significant differences according to adhesive and application method ( $p < 0.05$ ). Total-etch application produced statistically higher SBS than self-etch application ( $p < 0.05$ ). Two-step universal adhesive (G2 Bond Universal) showed the highest SBS in all application methods ( $p < 0.05$ ). The SBS values for OptiBond Universal, Clearfil S3 Bond Universal, Gluma Bond Universal and Prime&Bond Universal were not statistically significantly different ( $p > 0.05$ ) in the total-etch application method. The single bottle adhesive Bond Force II was the adhesive system with the lowest values in both methods ( $p < 0.05$ ).

**Table 2:** SBS values (MPa) of the adhesives used in the study

Adhesive/Applcation	Self-Etch	Total-Etch	p
G2-Bond Universal	10.67±4.9 <sup>a,A</sup>	18.5±2.8 <sup>a,B</sup>	0,000
G-Premio Bond	5.7±1.4 <sup>b,A</sup>	8.5±2.3 <sup>b,B</sup>	0.040
OptiBond Universal	5.4±1.7 <sup>b,A</sup>	10.8±2.7 <sup>c,B</sup>	0.000
Clearfil S3 Bond Universal	6.3±0.9 <sup>bc,A</sup>	10.8±1.8 <sup>c,B</sup>	0.000
Gluma Bond Universal	8.1±2.1 <sup>c,A</sup>	11.6±2.5 <sup>cd,B</sup>	0.003
Bond Force II	3.1±0.5 <sup>d,A</sup>	7.6±1.2 <sup>b,B</sup>	0.000
Prime&Bond Universal	4.6±1.7 <sup>b,A</sup>	13.3±3.2 <sup>d,B</sup>	0.000
Prime&Bond NT	6.1±1.8 <sup>bc,A</sup>	14.9±1.5 <sup>d,B</sup>	0.000
p	0.000	0.000	

\* Statistically significant difference between self-etch application and total etch application is shown with A-D, statistically significant difference between adhesives is shown with a-d ( $p < 0.05$ ).

When the fracture types were analyzed, the most fracture surface was seen in the adhesive type. (Figure 3) Cohesive and mixed type fractures were mostly seen in the total-etch application of G2 Bond Universal adhesive. In the self-etch application of all universal adhesives, only adhesive type fracture was observed. Bond Force II and G-Premio Bond showed only adhesive type fracture in both self-etch and total-etch application.



**Figure 3:** Fracture types between material and tooth (A: G2 Bond Universal, B: G-Premio Bond, C: OptiBond Universal, D: Clearfil S3 Bond Universal, E: Gluma Bond Universal, F: Tokuyama Bond Force II, G: Densply Prime&Bond Universal, H: Densply Prime&Bond NT, t:total etch, s:self etch)



## DISCUSSION

The performance of a restorative material in clinical practice is essential for material selection. Clinical trials are more reliable than *in vitro* studies in determining the success of restorative treatment and the durability of the material. However, it is not easy to determine the cause of a failed restoration in clinical studies. Clinical studies, especially when testing the durability of the material, require more time than laboratory studies. Given the progressive evolution of materials, often the tested material is no longer in daily use by the time the study is completed.<sup>16</sup> This is why adhesive systems are often selected based on the results of laboratory tests, but these tests are affected by many variables, including specimen characteristics, specimen preparation, handling, storage and testing technique.<sup>3</sup>

Adhesive systems are an important component of restorative treatment outcomes. It enables the interaction between the resin and the dental substrate.<sup>17</sup> Without proper mechanical properties of the adhesive, the choice of resin is irrelevant because failure of the restoration is inevitable. Therefore, it is useful and important to compare dentin bond strengths and to test the bond strength of various new adhesive systems.<sup>3</sup>

Both the treatment modalities and materials used in dentistry are constantly changing and evolving. While the oldest adhesives on the market, total-etch adhesives, are still the gold standard for dental bonding, the trend is to develop self-etching materials that are easier to apply.<sup>7</sup> This simplifies manipulation by combining all components into a single dental material, reducing the number of steps to a one-step system.<sup>9,10</sup> Universal adhesives are easy to use, faster to apply, and less sensitive to changes in operator technique than multi-step etch-and-rinse adhesives.<sup>5,18</sup> There is also a wide variety of commercially available and widely used

universal adhesives.

This study compared several new universal adhesives for shear bond strength. Shear bond testing is the most common method for determining bond strength.<sup>19</sup>

Acid etching of dentin removes the smear layer and demineralizes the subsurface. This is a predictable clinical procedure, but some factors inherent in the conditioning of dentin tissue can affect the bond strength of adhesives.<sup>20,21</sup> Dentin collagen exposed to total-etch adhesives has been shown to be highly susceptible to hydrolytic and enzymatic degradation processes.<sup>10,22</sup> Although adhesive systems are becoming simpler, careful management is still required, particularly with regard to the effect of substrate pretreatment on bond performance. Acceptable bond strength values can be achieved without dentin pretreatment, regardless of the adhesive system used, under less sensitive technical conditions. In the study by Poggio et al.,<sup>23</sup> the application of acid to universal adhesives resulted in a weakening of the bond.

According to the results of our study, the two-stage G2 Bond Universal had the highest and Tokuyama Bond Force II had the lowest SBS values. According to the results of a study by Jäggi et al.,<sup>2</sup> it is possible that the adhesives tested, especially those with higher pH, may perform better when used with phosphoric acid. In our study, Tokuyama Bond Force II, which had the highest pH, had the lowest bond strength in both applications. This contradicts the result found by Jäggi et al.<sup>2</sup>

Related researches have generally not supported the notion that a lower pH will result in better bond strength. A previous study evaluating the dentin bond strength of self-etching adhesives with different pH values found that lower pH adhesives did not have higher dentin bond strength.<sup>24,25</sup> Other

studies have also shown that self-etching adhesives with relatively high pH values provide good dentin bond strength.<sup>26,27</sup>

A smooth specimen surface eliminates potential retentive elements and allows the focus to be on the chemical bonding capabilities of the adhesives. In this study, dentin surfaces were prepared using SiC disks. Of additional importance is the bond between the adhesive and the composite, which is achieved by the cross-linking of methacrylate and other functional groups during polymerization. It may make sense to combine composite materials and adhesive systems from the same manufacturer, as they often use similar base monomers and initiator systems. However, this study could not conclude that "bonding is better with the same manufacturer's products" because adhesives from other manufacturers showed better, worse, and similar results.<sup>2</sup>

Depending on the type of adhesive and the method of application of the same adhesive, universal adhesives can have significantly different bond strengths. According to a study by Brkanović et al.,<sup>3</sup> since the total-etch method has less effect on the fatigue strength of dentin than the self-etch method, a universal adhesive applied by this method will have a lower fatigue strength. However, clinical studies have shown that there is no statistically significant difference between different dentin preparations when a universal adhesive method is used.<sup>3,28</sup> Brkanović et al. p<sup>3</sup> demonstrated in a study that G2-Bond Universal has higher or equal dentin SBS compared to other adhesives, which is consistent with our study. In the same study, G2-Bond Universal was reported to be the most effective way to maintain high dentin bond strength in the self-etching approach compared to other representative adhesives. In our study, G2 Bond Universal, as well as other universal adhesives, showed better bond strength in the total etch application. A

meta-analysis by Rosa et al.,<sup>7</sup> total-etch application of universal adhesives to dentin did not show a statistically significant difference compared to self-etch application. Only one adhesive system was reported to have better bond strength with total-etch application.

Despite the efforts of manufacturers to develop and market new materials, the question remains whether clinicians should consider using these new adhesives with pre-acid etching rather than self-etch application. Which bonding protocol is best for multimodal adhesives cannot be definitively answered with the insufficient clinical evidence available and the short follow-up times evaluated.<sup>7</sup>

Although the laboratory results of this study need to be further evaluated clinically, it is important to note from a materials utilization standpoint that adhesives developed for the same indication and approved for clinical use show large differences in their adhesive properties. A better understanding of these concepts could significantly improve the bonding ability of universal adhesives, making this a highly important topic for further research.<sup>2</sup>

## **CONCLUSION**

Within the limitations of this study, the following conclusions were drawn:

1. Two-step universal adhesive G2 Bond Universal had the highest SBS in total-etch and self-etch modes.
2. Universal adhesives show higher SBS values when applied in total-etch mode.
3. The type of universal adhesive and the mode of application have an effect on bond strength.

## **Ethical Approval**

Ethical approval for this study was obtained from Gülhane University of Health Sciences Pharmaceutical and Medical Received by off-device ethics committee (2024/284).

### Financial Support

No financial support was received from any institution or organization for this study.

### Conflict of Interest

The authors deny any conflicts of interest related to this study.

### Author Contributions

Design: IKC, FO, SK, Data collection or data entry: IKC, NA, Analysis and interpretation: IKC, SK, Literature review: IKC, NA, Writing: IKC, NA, FO.

### REFERENCES

1. Murdoch-Kinch CA, McLean ME. Minimally invasive dentistry. *J Am Dent Assoc.* 2003;134:87-95
2. Jäggi M, Karlin S, Zitzmann NU, Rohr N. Shear bond strength of universal adhesives to human enamel and dentin. *J Esthet Restor Dent.* 2024;36:804-12.
3. Brkanović S, Sever EK, Vukelja J, Ivica A, et al. Comparison of different universal adhesive systems on dentin bond strength. *Materials.* 2023;16:1530.
4. Pashley DH, Tay FR, Breschi L, Tjäderhane L, et al. State of the art etch-and-rinse adhesives. *Dent Mater.* 2011;27:1-16.
5. Van Meerbeek B, Yoshihara K, Yoshida Y, Mine A, et al. State of the art of self-etch adhesives. *Dent Mater.* 2011;27:17-28.
6. Loguercio AD, Barroso LP, Grande RHM, Reis A. Comparison of intra- and intertooth resin-dentin bond strength variability. *J Adhes Dent* 2005;7:151-8.
7. Da Rosa WLDO, Piva E Da Silva AF. Bond strength of universal adhesives: A systematic review and meta-analysis. *J Dent.* 2015;43:765-76.
8. Reis A, Zander-Grande C, Kossatz S, Stanislawczuk R, et al. Effect of mode of application on the microtensile bond strength of a self-etch and etch-and-rinse adhesive system. *Oper Dent.* 2010;35:428-35.
9. Marchesi G, Frassetto A, Mazzoni A, Apolonio F, et al. Adhesive performance of a multi-mode adhesive system: 1-year in vitro study. *J Dent.* 2014;42:603-12.
10. Breschi L, Mazzoni A, Ruggeri A, Cadenaro M, et al. Dental adhesion review: Aging and stability of the bonded interface. *Dent Mater.* 2008;24:90-101.
11. Van Meerbeek B, Peumans M, Poitevin A, Mine A, et al. Relationship between bond-strength tests and clinical outcomes. *Dent Mater.* 2010;26:e100-21.
12. Stape THS, Tjäderhane L, Abuna G, Sinhoreti MAC, et al. Optimization of the etch-and-rinse technique: New perspectives to improve resin-dentin bonding and hybrid layer integrity by reducing residual water using dimethyl sulfoxide pretreatments. *Dent Mater.* 2018;34:967-77.
13. Hardan L, Bourgi R, Kharouf N, Mancino D, et al. Bond Strength of Universal Adhesives to Dentin: A Systematic Review and Meta-Analysis. *Polymers.* 2021;13:814.
14. Frassetto A, Breschi L, Turco G, Marchesi G, et al. Mechanisms of degradation of the hybrid layer in adhesive dentistry and therapeutic agents to improve bond durability-A literature review. *Dent Mater.* 2016;32:e41-53.
15. Cardoso SA, Oliveira HL, M EA, Carre NL, et al. Effect of shelf-life simulation on the bond strength of self-etch adhesive systems to dentin. *Appl Adhes Sci.* 2014;2:26.
16. Ismail AM, Bourauel C, ElBanna A, Salah Eldin T. Micro versus Macro Shear

- Bond Strength Testing of Dentin-Composite Interface Using Chisel and Wireloop Loading Techniques. *Dent J.* 2021;9:140.
17. Perdigão J. New developments in dental adhesion. *Dent Clin North Am.* 2007;51:333-57.
  18. Perdigão J, Muñoz MA, Sezinando A, Luque-Martinez IV, et al. Immediate adhesive properties to dentin and enamel of a universal adhesive associated with a hydrophobic resin coat. *Oper Dent.* 2014;39:489-99.
  19. Perdigão J, Sezinando A, Monteiro PC. Laboratory bonding ability of a multi-purpose dentin adhesive. *Am J Dent.* 2012;25:153-8.
  20. Scotti N, Rota R, Scansetti M, Migliaretti G, Pasqualini D, Berutti E. Fiber post adhesion to radicular dentin: The use of acid etching prior to a one-step self-etching adhesive. *Quintessence Int.* 2012;43:615-23.
  21. Ramos SM, Alderete L, Farge P. Dentinal tubules driven wetting of dentin: Cassie-Baxter modelling. *Eur Phys J E Soft Matter.* 2009;30:187-95.
  22. Pashley DH, Tay FR, Yiu C, Hashimoto M, et al. Collagen degradation by host-derived enzymes during aging. *J Dent Res.* 2004;83:216-21.
  23. Poggio C, Beltrami R, Colombo M, Chiesa M, Scribante A. Influence of dentin pretreatment on bond strength of universal adhesives. *Acta Biomater Odontol Scand.* 2017;3:30-35.
  24. Ozmen B, Koyuturk AE, Tokay U, Cortcu M, Sari ME. Evaluation of bond strength of self-etching adhesives having different pH on primary and permanent teeth dentin. *J Appl Biomater Funct Mater.* 2015;13:e274-9.
  25. Tsujimoto A, Barkmeier WW, Takamizawa T, Watanabe H, et al. Comparison between universal adhesives and two-step self-etch adhesives in terms of dentin bond fatigue durability in self-etch mode. *Eur J Oral Sci.* 2017;125:215-22.
  26. Tsai YL, Nakajima M, Wang CY, Foxton RM, Lin CP, Tagami J. Influence of etching ability of one-step self-etch adhesives on bonding to sound and non-carious cervical sclerotic dentin. *Dent Mater J.* 2011;30:941-7.
  27. Osorio R, Pisani-Proenca J, Erhardt MC, Osorio E, et al. Resistance of ten contemporary adhesives to resin-dentine bond degradation. *J Dent.* 2008;36:163-9.
  28. Suda S, Tsujimoto A, Barkmeier WW, Nojiri K, et al. Comparison of enamel bond fatigue durability between universal adhesives and two-step self-etch adhesives: Effect of phosphoric acid pre-etching. *Dent Mater J.* 2018;37:244-55.

# Effect of Energy Drinks on Surface Roughness and Weight Loss of Custom-Made Mouthguard Material

Tuba ŞENOCAK<sup>1\*</sup> Alper ÖZDOĞAN<sup>2</sup> Tuğçe KAVAZ<sup>3</sup>

<sup>1</sup> Lecturer, Erzincan Binali Yıldırım University, Faculty of Dentistry, Department of Prosthodontics, Erzincan, Türkiye, tubasenocak@erzincan.edu.tr

<sup>2</sup> Assoc. Prof., Atatürk University, Faculty of Dentistry, Department of Prosthodontics, Erzurum, Türkiye, alprozdn@gmail.com

<sup>3</sup> Assist. Prof., Medipol University, Faculty of Dentistry, Department of Prosthodontics, İstanbul, Türkiye, tugce.kavaz@medipol.edu.tr

## Article Info

### Article History

Received: 20.06.2024

Accepted: 23.09.2024

Published: 15.10.2024

### Keywords:

Energy drinks,  
Etilen Vinil Asetat,  
Mouthguard,  
Roughness,  
Weight.

## ABSTRACT

**Aim:** To investigate the effect of different drinks on the surface roughness and weight loss of custom-made mouthguard material prepared in two different thicknesses.

**Materials and Methods:** The custom-made mouthguard material Ethylene vinyl acetate (EVA) (4.0x125 mm) was used in the current research. 102 rectangular prism specimens (8 × 8 mm) from two different thickness (3 and 4 mm) were prepared. They were randomly divided into four different groups (n=13), numbered, and initial weight and roughness measurements were recorded. All specimens were then stored in 4 different drinks, including 2 different energy drinks, an isotonic sports drink, and water. At the end of the 7-day and 28-day periods, weight and roughness measurements of the specimens were again performed and recorded. The data were analyzed the repeated measures ANOVA, one-way ANOVA, and the paired sample t tests ( $\alpha=.05$ ).

**Results:** There were no statistically significant differences in the weight × beverage and roughness × beverage interactions ( $p>0.05$ ) both weight and roughness changes of specimens at 0, 7, and 28 days.

**Conclusion:** Energy drinks and sports drinks have no effect on the surface liquid and weight of the specially produced oral material.

## Enerji İçeceklerinin Kişiyeye Özel Üretilen Mouthguard Materyalinin Yüzey Pürüzlülüğü ve Ağırlık Kaybı Üzerindeki Etkisi

### Makale Bilgisi

#### Makale Geçmişi

Geliş Tarihi: 20.06.2024

Kabul Tarihi: 23.09.2024

Yayın Tarihi: 15.10.2024

### Anahtar Kelimeler:

Enerji içeceği,  
Etilen Vinil Asetat,  
Ağız koruyucu,  
Pürüzlülük,  
Ağırlık.

### ÖZET

**Amaç:** Bu çalışmanın amacı, iki farklı kalınlıkta hazırlanan kişiyeye özel mouthguard malzemesinin yüzey pürüzlülüğü ve ağırlık kaybı üzerine farklı içeceklerin etkisini araştırmaktır.

**Gereç ve Yöntemler:** Bu çalışmada özel yapım ağızlık malzemesi Etilen vinil asetat (EVA) (4,0x125 mm) kullanılmıştır. İki farklı kalınlıkta (3 ve 4 mm) 102 dikdörtgen prizma numunesi (8 × 8 mm) hazırlanmıştır. Numuneler daha sonra rastgele dört gruba ayrılmış (n=13), numaralandırılmış ve ilk ağırlık ve pürüzlülük ölçümleri kaydedilmiştir. Tüm numuneler daha sonra 2 farklı enerji içeceği, bir izotonik spor içeceği ve su olmak üzere 4 farklı içekte saklanmıştır. 7 günlük ve 28 günlük sürelerin sonunda numunelerin ağırlık ve pürüzlülük ölçümleri tekrar yapılmış ve kaydedilmiştir. Veriler tekrarlanan ölçümler ANOVA, tek yönlü ANOVA ve eşleştirilmiş örneklem t testleri ile analiz edilmiştir ( $\alpha=.05$ ).

**Bulgular:** Ağırlık × içecek ve pürüzlülük × içecek etkileşimlerinde ( $p>0,05$ ) 0, 7 ve 28. günlerde numunelerin hem ağırlık hem de pürüzlülük değişimlerinde istatistiksel olarak anlamlı bir fark bulunmamıştır.

**Sonuç:** Enerji içecekleri ve spor içeceklerinin özel olarak üretilen ağız materyalinin yüzey sıvısı ve ağırlığı üzerinde herhangi bir etkisi yoktur.

**To cite this article:** Şenocak, T., Özdoğan, A. & Kavaz, T. Effect of Energy Drinks on Surface Roughness and Weight Loss of Custom-Made Mouthguard Material NEU Dent J. 2024;6(Special Issue):79-87.  
<https://doi.org/10.51122/neudentj.2024.118>

\*Corresponding Author: Tuba ŞENOCAK, [tubasenocak@erzincan.edu.tr](mailto:tubasenocak@erzincan.edu.tr)



## INTRODUCTION

One of the etiologic factors for traumatic dental injuries is sports accidents. Mouthguards are widely used in many sports and can significantly reduce the risk of orofacial injuries.<sup>1,2</sup> Mouthguards are a highly protective and low-cost device designed to absorb the impacts that cause orofacial injuries.<sup>3</sup> Many sports use it as effective personal protective equipment. The production, materials used, and designs of mouth guards have changed over time according to their effectiveness. A properly manufactured mouthguard absorbs the impact inside the mouth, restricting the force to the hard and soft tissues in the mouth and distributing it evenly throughout the orofacial complex.<sup>3</sup> Mouthguards must be of sufficient thickness labially, palatally, lingually, and occlusally to be protective. The proper distribution of force that the athlete will experience during the impact will enable them to endure the stress and strain.

The mouthguard's thickness needs to fall between the minimum required values for this function.<sup>4</sup> In no place should the mouthguard's average thickness be less than 3 mm. In general, the thickness of the mouthguard on different surfaces should be between 3-4 mm.<sup>5</sup> If it is even thinner, it will not provide appropriate protection against potential hits and will also have a negative influence on the athlete's airway and speech.<sup>6</sup> Following shaping with a vacuum shapping equipment, a thickness reduction of 47% on the surface and 54% on the buccal surface may be observed, with 38% on the incisal edge and 38% on the labial edge.<sup>7,8</sup> Due to the model's varying height and width, thickness variations may also happen when making the mouthguard in the vacuum forming device, depending on the athlete's shaped and deepened palate dome as well as the axes of their anterior teeth.<sup>4</sup> According to the American National Standards Institute / American Dental

Association (ADA), the types of mouthguards are classified as type I stock, type II mouth (Class 1. Thermoplastic, Class 2. Chemical Hardening), type III special (Class 1. Vacuum, Class 2. Model).<sup>9</sup> Mouthguards that are custom-made fall under type III. Custom mouthguards are currently thought of as the standard of the best option,<sup>1,10,11</sup> because it can be completely altered to fit the patient's preferences for style and anatomy. EVA is a commonly used material for custom-made mouthguards.<sup>12,13</sup> EVA is a biocompatible, highly elastic, aesthetic, heat-formable, and non-allergenic material.<sup>14</sup>

The use of energy drinks is particularly popular among athletes as they have a performance-enhancing effect. Energy drinks are non-carbonated, sugar-sweetened beverages that are believed to enhance cognitive and physical performance.<sup>15</sup> Energy drinks help to replace the fluid electrolytes lost during and after exercise, which contributes to improving the athlete's performance.<sup>16</sup> Energy drinks are commonly eaten by athletes to enhance their physical performance and endurance, as well as to prevent dehydration.<sup>17</sup> Athletes have a dangerous consumption pattern during training and competition when they take "small sips from a bottle" of sports drinks and gels for carbohydrates.<sup>18,19</sup> In addition, consumption of energy drinks may pose a risk to oral hygiene and may cause dental erosion.<sup>20</sup> There are studies<sup>21,22</sup> in the literature that demonstrate that energy drinks can promote dental erosion, but none have looked at how they may affect the material of mouthguards worn by athletes.

This study set out to look into the effects of several energy drinks and sport drinks on the surface roughness and weight change of custom-made mouthguard material prepared in two different thicknesses. The null hypothesis of the study is that different drinks will affect the weight and roughness values of the mouthguard material, regardless of the thickness difference.

**MATERIALS AND METHODS**

A power analysis was conducted utilizing the G\*Power software application. (v3.0.10; Heinrich Heine University Düsseldorf) to obtain the highest power level with the smallest specimen size. The examination indicated that a minimum of thirteen specimens were necessary to achieve the highest level of power, with a total of 102 specimens utilized in the study (power=80,  $\alpha=0.05$ ).

The mouthguard material in the study was a 4.0x125 mm clear Bioplast Xtreme (Scheu-Dental GmbH, Iserlohn, Germany). Before the mouthguard is applied to the mouth, the material is adapted to the model using a special machine (Biostar; Scheu-Dental GmbH, Iserlohn, Germany) in accordance with the heat and pressure technique. The Bioplast Xtreme disks used in the study were heat treated in line with the manufacturer's instructions and let to cool naturally without being molded onto any models to simulate the mouthguard forming processes of the material. Differences that could have resulted from heat treatments were removed in this way. The thickness of the lamination surface of the mouthguard material, which protects against impact, is slightly higher than the remainder of the material. Both surfaces were considered as parameters in

determining the study groups. Specimens were prepared by cutting a rectangular prism of 8x8x4 mm for thicker (T4) and 8x8x3 mm for thinner (T3) under water cooling with a diamond bur. The accuracy of the specimen dimensions after each cut the measurement was taken using a digital caliper (Absolute AOS; Mitutoyoto Corp., Kanagawa, Japan) to ensure standardization. Every specimen was given a number, and a computerized analytical balance (XS105, Mettler Toledo, Greifensee, Switzerland) was used to take the initial measurements of the weigh. Each specimen was weighed on analytic balance with a precision of 0.1 mg. The initial surface roughness measurements of the specimens were recorded by two-dimensional profilometer (Surtronic 25; Taylor Hobson, Leicester, U.K.) (cutoff value ( $\lambda_c$ ) of 0.80 mm, an evaluation length of 2.4 mm). The initial weight values ( $w_0$ ) and the surface roughness values ( $R_a, r_0$ ) values were recorded. The specimens were then randomly divided into 4 groups ( $n=13$ ) and placed in boxes (70x20 mm) with transparent plastic lids. The specimens were stored in 4 different beverages, including three commercial energy drinks and water. Information about the energy drinks used is given in Table 1. The storage of the specimens in beverages was determined as follows:

**Table 1.** Ingredients of energy drinks

Energy drink	Manufacturer	pH	Ingredient
Red Bull	Red Bull Company; Austria	3.81	Water, sucrose, glucose, acidifier sodium citrates, carbon dioxide, taurine (0.4%), glucuronolactone (0.24%), caffeine (0.03%), inositol, vitamins (niacin, pantothenic acid, B6, B12), flavourings, and colours (caramel, riboflavin). Sugar content: 27 g (per 8.46 oz)
Burn	The Coca-Cola Company; Atlanta, Georgia, USA	3.03	Carbonated water, sucrose, citric acid, taurine (0.4%), acidity regulator: sodium citrate, coloring agents: E163, E150d, preservatives: potassium sorbate, sodium benzoate, flavor, caffeine (0.03%), inositol, vitamins [nicotinamide (B3), d calcium pantothenate, pyridoxine hydrochloride (B6), cyanocobalamin (B12)], seed extract of guarana (0.005%), antioxidants (ascorbic acid)
Powerade	The Coca-Cola Company; Atlanta, Georgia, USA	3.79	Water, Glucose, Acid (Citric Acid), Acidity Regulators (Sodium Citrates, Potassium Citrates), Fructose, Stabilisers (Acacia Gum, Glycerol Esters Of Wood Rosins), Sweeteners (Aspartame, Acesulfame-K), Flavourings, Colour (Brilliant Blue), Vitamin B6

The bottle containing each specimen was filled with 10 mL of the beverage to exceed the surface of the specimen and placed in an oven (Nükleon NIN-30; Nükleon, Ankara, Turkey) at 37 °C for 2 minutes.<sup>17</sup> Then, the beverages in each specimen were removed from the oven, and 10 mL of distilled water was added to exceed the specimen surface and stored at room temperature until the next beverage application. The purpose of storing the specimens in distilled water was to prevent weight loss by storing them in a dry environment, and the reason for closing the mouths of the containers was to prevent the water from evaporating and reducing the level. This procedure was performed every day at the same time and by the same researcher in order to complete each 24-hour period. At the conclusion of the 7-day period, weight and roughness measurements of the specimens were again performed and recorded according to the initial measurement procedures (w7, r7). The storage of the specimens in the beverages was repeated for 28 days, and at the end of the 28th day, weight and roughness measurements were performed again, and the data were recorded (w28, r28). The color changes caused by different drinks on the specimens were also visually examined.

The data was statistically analyzed using a statistical software tool (IBM SPSS Statistics, v20; IBM Corp). The analyses employed the paired sample t test, repeated measures ANOVA, one-way ANOVA, and the Kolmogorov-Smirnov test for normalcy ( $\alpha=.05$ ).

## **RESULTS**

There were no statistically significant differences in the weight×beverage and roughness×beverage interactions ( $p>0.05$ ), according to the two-way ANOVA test results used to assess the weight and roughness changes of both T3 and T4 specimens at 0, 7, and 28 days. Based on the results of the weight measurements of both T3 and T4 specimens;

There were no statistically significant differences specimens (T3, T4)×beverages interactions ( $p=0.58$ ), but there were statistically significant differences between specimens ( $p=0.001$ ), and among the beverages ( $p=0.004$ ) at 0 day. T4 ( $0.258930\pm 0.0365999$ ) had less weight than T3 ( $0.283988\pm 0.0414878$ ). Burn and Powerade had lower weight values than water, while the weight differences between RedBull and water and other drinks were not significant.

There were no statistically significant differences specimens (T3, T4) x beverages interactions ( $p=0.65$ ), but there were statistically significant differences between specimens ( $p=0.004$ ), and among the beverages ( $p=0.016$ ) at 7 days. T4 ( $0.263168\pm 0.0353625$ ) had less weight than T3 ( $0.284944\pm 0.041556$ ). Burn had lower weight values than water, while the weight differences between the others were not significant.

There were no statistically significant differences specimens (T3,T4)×beverages interactions ( $p=0.59$ ), but there were statistically significant differences between specimens ( $p=0.001$ ), and among the beverages ( $p=0.01$ ) at 28 days. T4 ( $0.26358\pm 0.0353647$ ) had less weight than T3 ( $0.288475\pm 0.041924$ ). Burn had lower weight values than water, while the weight differences between the others were not significant.

Based on the results of the surface roughness measurements of both T3 and T4 specimens;

There were no statistically significant differences specimens (T3,T4)×beverages interactions ( $p=0.43$ ), but there were no statistically significant differences between specimens ( $p=0.91$ ), and among the beverages ( $p=0.3$ ) at 0 day.

There were statistically significant differences specimens (T3,T4)×beverages interactions ( $p=0.01$ ), but there were no statistically significant differences between specimens ( $p=0.65$ ), and among the beverages ( $p=0.88$ ) at 7 days.



There were statistically significant differences specimens (T3, T4)xbeverages interactions ( $p=0.03$ ), but there were no statistically significant differences between specimens ( $p=0.53$ ), and among the beverages ( $p=0.15$ ) at 28 days. According to the one-way

ANOVA results for the comparison of T3 and T4 group specimens, there were no significant differences ( $p>0.05$ ) in terms of both weight and roughness changes at 7 and 28 days. Tables 2 and 3 display the mean and standard deviation values.

**Table 2.** Least square means and standard deviation (SD) for weight loss

		w0		w7		w28		N
		Mean	Standard Deviation	Mean	Standard Deviation	Mean	Standard Deviation	
T3	Water	.302354	.0436971	.302923	.0439729	.307554	.0436894	13
	Red Bull	.285469	.0422565	.288115	.0411814	.291838	.0411432	13
	Powerade	.284446	.0318508	.284092	.0336150	.288292	.0334585	13
	Burn	.263685	.0423218	.264646	.0420909	.266215	.0424908	13
	Total	.283988	.0414878	.284944	.0415560	.288475	.0419240	52
T4	Water	.282831	.0259529	.283062	.0259560	.283638	.0256130	13
	Red Bull	.262915	.0376436	.263038	.0375385	.264046	.0374451	13
	Powerade	.241462	.0408700	.249162	.0420741	.249162	.0420741	13
	Burn	.246618	.0269066	.256364	.0261400	.256364	.0261400	13
	Total	.258930	.0365999	.263168	.0353625	.263580	.0353647	52

(T3: 3 mm thick specimens, T4: 4 mm thick specimens; w0: Weight measurement on day 0, w7: Weight measurement on day 7, w28: Weight measurement on day 28)

**Table 3.** Least square means and standard deviation (SD) for surface roughness

		r0		r7		r28		N
		Mean	Standard Deviation	Mean	Standard Deviation	Mean	Standard Deviation	
T3	Water	.54	.33	.76	.24	.44	.13	13
	Red Bull	.41	.11	.65	.66	.68	.51	13
	Powerade	.51	.21	.41	.07	.52	.21	13
	Burn	.69	.52	.68	.57	.72	.52	13
	Total	.54	.34	.63	.46	.59	.39	52
T4	Water	.52	.15	.61	.28	.53	.16	13
	Red Bull	.5	.13	.64	.2	.6	.32	13
	Powerade	.56	.32	.88	.39	.88	.39	13
	Burn	.53	.22	.51	.11	.52	.11	13
	Total	.53	.21	.67	.29	.64	.3	52

(T3: 3 mm thick specimens, T4: 4 mm thick specimens; r0: Roughness measurement on day 0, r7: Roughness measurement on day 7, r28: Roughness measurement on day 28)

The paired sample t test's results, which analyzed the weight and roughness changes of the beverages individually for the specimens from the T3 group: w0-w7 ( $p<0.05$ ), w0-w28 ( $p<0.001$ ), and w7-w28 ( $p<0.001$ ) for water, Only the change from w0-w28 ( $p<0.05$ ) for Red Bull, Only the change w7-w28 ( $p<0.05$ ) for Powerade showed significance.

Burn experienced no significant

increases in weight or roughness ( $p>0.05$ ).

The paired sample t test's results, which analyzed the weight and roughness changes of the beverages individually for the specimens from the T4 group:

Changes in w0-w7 and w0-w28 for water ( $p<0.05$ ), w0-w28 ( $p<0.05$ ), w7-w28 ( $p<0.05$ ), and r0-r7 ( $p<0.05$ ) adjustments for Red Bull, Changes in r0-r7 and r0-r28 for Powerade were significant ( $p<0.05$ ).

Burn experienced no significant increases in weight or roughness ( $p>0.05$ ).

## **DISCUSSION**

The purpose of the study was to investigate the roughness and weight changes of custom-made mouthguard materials made in two different thicknesses after storage in various energy drinks. The null hypothesis was partially rejected since sample beverage interactions and weight measurements did not show statistical differences, and although there was no difference in roughness results on day 0, there was a difference on days 7 and 28.

Mouthguards may have different thicknesses or different thicknesses in different parts of the apparatus depending on the type of sport. A thicker mouthguard has higher protection than a thinner mouthguard.<sup>23</sup> EVA reduces impact energy to act as a form of shock absorber for hard forces.<sup>24</sup> Another aspect of EVA that should be considered for athletes is its great capacity for cushioning, given that it can soak up extra moisture from the oral area.<sup>25</sup> Water absorption and material thickness are the two most crucial characteristics required of the materials used in the manufacture of mouth guards.<sup>26</sup> Additionally, because microorganisms stick to surfaces more readily, the surface roughness of materials used in the mouth can have a direct impact on bacterial colonization. A higher bacterial colonization rate is a sign of developing gum and tooth disease.<sup>27</sup> One of the many diverse characteristics of dental materials is surface roughness, which is crucial because it has to do with microbial adhesion. Borro et al. assessed the surface roughness of EVA both before and after various cleaning techniques in their investigation into the significance of surface roughness's impact on bacterial adherence and bio-film formation.<sup>28</sup> There is research in the literature on how EVA layer thickness and color affect surface roughness.<sup>29</sup> It has been demonstrated in the literature that mechanical biofilm cleansing (tooth brushing) and friction and abrasion from use may have contributed to

the increase in surface hardness of sports mouthguards manufactured of EVA plates.<sup>30</sup> The hardness and surface roughness of acrylic resin samples with alloys fixed on top that had been soaked in artificial saliva for five minutes before being submerged in sodium bicarbonate, hydrogen peroxide, and water (control) were examined in a study conducted by Garcia et al., which supported our findings.<sup>31</sup> Similar to the increase in roughness values in the days that followed our investigation, the data demonstrated that the surface roughness of the other samples increased in comparison to those submerged in water. In a different investigation, it was demonstrated that the immersion method in sodium perborate, which was used to disinfect the mouthguard material, greatly raised the surface roughness values.<sup>32</sup> This demonstrates that the energy drink effect in our investigation is equally significant to the dipping and holding strategy.

Energy drinks have been reported to have deleterious effects on dental tissues and restorative materials because of their low pH levels and large quantities of non-reducing carbohydrates, even though there are remarkably few studies in the literature looking at how they affect mouthguard materials. Energy drinks like Red Bull and Burn have been reported to significant surface degradation of restorative materials,<sup>33</sup> while Red Bull was found to have the highest total titratable acidity and a strong propensity to erode enamel. Tanthanuch et al.<sup>34</sup> evaluated the effect of repeated exposure to sports and energy beverages on the surface characteristics of glass ionomer, nanohybrid, and bulk-fill resin composites. Surface hardness decreased significantly, whereas surface roughness and color increased significantly. Investigations on the effects of sports and energy drinks on the surface characteristics of dental materials have been published in the literature; however, investigations on the impact of mouthguards on surface roughness have not. Contrary to evidence in the literature, energy drinks had partially effect on the surface roughness and

weight change of EVA material, according to the results of the current study. This might be attributed to alterations in the chemical composition of the EVA material employed, as well as a difference in retention durations. Although the time interval measurements of Red Bull and Powerade brand energy drinks differed, there were no discrepancies in the time interval measurements of Burn brand energy drink. These discrepancies are assumed to be caused by the ingredients in the energy drinks.

The present study has some limitations, including the use of just two distinct thicknesses, the lack of a surface hardness evaluation, and a maximum time interval of 28 days for the specimens. Future studies may yield different findings when using specimens with various thicknesses, storage times, and time intervals.

### **CONCLUSIONS**

Within the limitations of this in vitro study, the following conclusions were drawn:

1. Weight measures are not significantly affected by interactions with beverages.
2. Energy drinks have effect on the surface roughness of EVA-based custom-made mouthguards.

### **Ethical Approval**

This in-vitro study does not require ethics committee approval.

### **Financial Support**

The authors declare that this study received no financial support.

### **Conflict of Interest**

The authors deny any conflicts of interest related to this study.

### **Author Contributions**

Design: TS, AO, TK, Data collection and processing: TS, TK, Analysis and interpretation: TS, AO, Literature review: TS, AO, TK, Writing: TS, AO.

### **REFERENCES**

1. Knapik JJ, Hoedebecke BL, Rogers GG, et al. Effectiveness of Mouthguards for the Prevention of Orofacial Injuries and Concussions in Sports: Systematic Review and Meta-Analysis. *Sports Med.* 2019;49:1217-32
2. Fernandes LM, Neto JCL, Lima TFR, et al. The use of mouthguards and prevalence of dento-alveolar trauma among athletes: A systematic review and meta-analysis. *Dent Traumatol.* 2019;35:54-72.
3. Bergman L, Milardović Ortolan S, Žarković D, et al. Prevalence of dental trauma and use of mouthguards in professional handball players. *Dent Traumatol.* 2017;33:199-204.
4. Takahashi M, Bando Y. Effect on thickness of a single-layer mouthguard of positional relationship between suction port of the vacuum forming device and the model. *Dent Traumatol.* 2021;37:502-9
5. Gage, C. C., Huxel Bliven, K. C., Bay, R. C. Effects of mouthguards on vertical dimension, muscle activation, and athlete preference: a prospective cross-sectional study. *Gen Dent*, 2015;63, 48-55
6. Verissimo C, Costa PVM, Santos-Filho PCF, et al. Custom-Fitted EVA Mouthguards: what is the ideal thickness? a dynamic finite element impact study. *Dent Traumatol.* 2016;32:95-102
7. Takahashi M, Araie Y, Satoh Y, et al. Shape change in mouthguard sheets during thermoforming - part 2: effect of the anteroposterior position of the model on mouthguard thickness. *Dent Traumatol.* 2017;33:114-20
8. Takahashi M, Bando Y. Thermoforming method to effectively maintain mouthguard thickness: Effect of moving the model position just before vacuum formation. *Dent Traumatol.* 2019;35:121-7.
9. AFFAIRS, A. C. O. S. Using mouthguards to reduce the incidence and severity of sports-related oral injuries. *J*

- Am Dent Assoc. 2006;137:1712-20.
10. Gawlak D, Mierzwińska-Nastalska E, Mańka-Malara K, et al. Assessment of custom and standard, self-adapted mouthguards in terms of comfort and users subjective impressions of their protective function. *Dent Traumatol.* 2015;31:113-7.
  11. Gould TE, Piland SG, Caswell S V., et al. National Athletic Trainers' Association Position Statement: Preventing and Managing Sport-Related Dental and Oral Injuries. *J Athl Train.* 2016;51:821-39.
  12. Tripodi D, Martinelli D, Ciaravino C, et al. The use of casein in sport mouthguards: microbiological and ecological variations in oral cavity. *JBRHA.* 2018;32:45-9.
  13. Parker K, Marlow B, Patel N et al. A review of mouthguards: effectiveness, types, characteristics and indications for use. *Br Dent J.* 2017;222:629-33.
  14. D'Ercole S, Martinelli D, Tripodi D. Influence of sport mouthguards on the ecological factors of the children oral cavity. *BMC Oral Health.* 2014;14:1-7.
  15. Larson N, DeWolfe J, Story M et al. Adolescent Consumption of Sports and Energy Drinks: Linkages to Higher Physical Activity, Unhealthy Beverage Patterns, Cigarette Smoking, and Screen Media Use. *J Nutr Educ Behav.* 2014;46:181-7.
  16. Aljaloud SO. Knowledge and behavior of Saudi University athletes toward energy and sport drinks with emphasis on microbial quality and safety. *Sports.* 2019;21:170-9.
  17. Erdemir U, Yıldız E, Eren MM, et al. Surface hardness of different restorative materials after long-term immersion in sports and energy drinks. *Dent Mater J.* 2012;31:729-36.
  18. Bryant S, McLaughlin K, Morgaine K, et al. Elite athletes and oral health. *Int J Sports Med.* 2011;32:720-4.
  19. Lun V, Erdman KA, Fung TS, et al. Dietary Supplementation Practices in Canadian High-Performance Athletes. *Int J Sport Nutr Exerc Metab.* 2012;22:31-7.
  20. Cochrane NJ, Yuan Y, Walker GD, et al. Erosive potential of sports beverages. *Aust Dent J.* 2012;57:359-64.
  21. Owens BM, Mallette JD, & Phebus JG. Effects of carbonated cola beverages, sports and energy drinks and orange juice on primary and permanent enamel dissolution. *Austin J Dent,* 2014;1:1004.
  22. Temple JL, Ziegler AM, Epstein LH. Influence of Price and Labeling on Energy Drink Purchasing in an Experimental Convenience Store. *J Nutr Educ Behav.* 2016;48:54-9.
  23. Zaman I, Rozlan SAM, Manshoor B et al. Study of Mouthguard Design for Endurance and Air-Flow Intake. *IOP Conf Ser Mater Sci Eng.* 2017;226:012007.
  24. Bochnig MS, Oh MJ, Nagel T, et al. Comparison of the shock absorption capacities of different mouthguards. *Dent Traumatol.* 2017;33:205-13.
  25. Fukasawa S, Churei H, Chowdhury RU, et al. Difference among shock-absorbing capabilities of mouthguard materials. *Dent Traumatol.* 2016;32:474-9.
  26. Tuna, E. B., & Ozel, E. Factors affecting sports-related orofacial injuries and the importance of mouthguards. *Sports Med.* 2014;44:777-83.
  27. Kawai K, Urano M, Ebisu S. Effect of surface roughness of porcelain on adhesion of bacteria and their synthesizing glucans. *J Prosthet Dent.* 2000;83:664-7.
  28. Haddad e Borro, L., de Queiroz, T. S., da Cruz, B. S., et al. Sports Med. Enhancing mouthguard longevity: Impact of surface treatment against aging from brushing and disinfectant exposure. *Dent Traumatol.* 2024;40:453-9.
  29. Almeida MH, Ceschim GV, Iorio NLPP, et al. Influence of thickness, color, and polishing process of ethylene-vinyl-acetate sheets on surface roughness and microorganism adhesion. *Dent Traumatol.* 2018;34:51-7.
  30. Ribeiro YJS, Delgado RZR, Paula-Silva

- FWG, et al. Sports mouthguards: Contamination, roughness, and chlorhexidine for disinfection - A randomized clinical trial. *Braz Dent J.* 2022;32:66-73.
31. Garcia RCMR, Júnior JAS, Rached RN, Del Bel Cury AA. Effect of denture cleansers on the surface roughness and hardness of a microwave-cured acrylic resin and dental alloys. *J Prosthodont Implant Esthetic Reconstruct Dentistry.* 2004;13:173-8.
  32. Machado AL, Breeding LC, Vergani CE, da Cruz Perez LE. Hardness and surface roughness of reline and denture base acrylic resins after repeated disinfection procedures. *J. Prosthet. Dent.*, 2009;102:115-122.
  33. Yazkan B. Surface degradation evaluation of different self-adhesive restorative materials after prolonged energy drinks exposure. *J Esthet Restor Dent.* 2020;32:707-14.
  34. Tanthanuch S, Kukiattrakoon B, Thongsroi T, et al. In vitro surface and color changes of tooth-colored restorative materials after sport and energy drink cyclic immersions. *BMC Oral Health.* 2022;22:578.

# Evaluation of the Effect of Background Color on the Color Change of Composite Resins of Different Translucencies

İrem KAYA<sup>1\*</sup>  Ahmet EROL<sup>2</sup>  Nevin ÇOBANOĞLU<sup>3</sup> 

<sup>1</sup> Res. Ass., Selçuk University, Faculty of Dentistry, Restorative Dentistry, Konya, Türkiye, irm.ky55@gmail.com

<sup>2</sup> Specialist Dentist, Konya Oral and Dental Health Hospital, Restorative Dentistry, Konya, Türkiye, aerox\_a309@hotmail.com

<sup>3</sup> Prof., Selçuk University, Faculty of Dentistry, Restorative Dentistry, Konya, Türkiye, nevin\_çeylan@hotmail.com

Article Info	ABSTRACT
<b>Article History</b> <b>Received:</b> 30.06.2024 <b>Accepted:</b> 05.09.2024 <b>Published:</b> 15.10.2024	<b>Aim:</b> To evaluate the effect of background color on color change evaluation of composite resins with different translucency <b>Material and Method:</b> Estelite $\Sigma$ Quick (EQ) CE, OA2 and Filtek Ultimate (FU) A2 Enamel, A2 Dentin composites were used in our study. Samples were prepared by layering only enamel and dentin and enamel + dentin (n=10) from composites of both brands. After preparation, the samples were kept in distilled water for 24 hours and then in coloring solution for 10 days. The colors of the composite samples were measured with a spectrophotometer (VitaEasysshade) on black, white and gray backgrounds after 24 hours (initial) and after coloring. Color change values of the same composites measured on different surfaces were compared. One-way ANOVA and Tukey's post-hoc tests were used for statistical analysis. ( $\alpha=0.05$ ). <b>Results:</b> When layered with dentin, enamel composites consistently showed lower $\Delta E00$ values than enamel composites alone ( $p<0.05$ ). When different translucent shades from the same company were compared on different substrates, the $\Delta E00$ order was found to be enamel > dentin $\geq$ enamel + dentin for all substrates. <b>Conclusion:</b> The different substrates did not affect the color assessment of samples containing an opaque composite resin, dentin composite; however, they did affect the color assessment of FU enamel, a translucent composite resin. More accurate color assessment can be achieved when translucent composite resins are layered with more opaque composite resins.
<b>Keywords:</b> Color stability, Opacity, Translucency, Composite resin, Background color.	

## Farklı Yarı Saydamlıktaki Kompozit Rezinerin Renk Değişikliğinin Değerlendirilmesi Üzerinde Arka Plan Renginin Etkisi

Makale Bilgisi	ÖZET
<b>Makale Geçmiş</b> <b>Geliş Tarihi:</b> 30.06.2024 <b>Kabul Tarihi:</b> 05.09.2024 <b>Yayın Tarihi:</b> 15.10.2024	<b>Amaç:</b> Bu çalışmanın amacı; farklı yarı saydamlıktaki kompozit rezinlerin renk değişikliği değerlendirilmesi üzerinde arka plan renginin etkisini değerlendirmektir. <b>Geçer ve Yöntemler:</b> Çalışmamızda Estelite $\Sigma$ Quick (EQ) CE (mine), OA2 (dentin) ve Filtek Ultimate (FU) A2 Mine, A2 Dentin kompozitleri kullanıldı. Her iki markanın kompozit rezinlerinden disk şeklinde örnekler mine ve dentin tek başına ve mine+dentin tabakalanarak hazırlandı (n=10). Örnekler hazırlandıktan sonra 24 saat distile suda, ardından 10 gün renklendirici solüsyonda (Nescafe Classic), bekletildi. Kompozit örneklerin renkleri 24 saat sonra (başlangıç) ve renklendirmeden sonra siyah, beyaz ve gri arka planda spektrofotometre (Vita Easysshade) ile ölçüldü. Her arka plan için iki ölçüm değeri kullanılarak renk değişim değeri ( $\Delta E00$ ) hesaplandı. Aynı kompozitlerin farklı arka planlarda ölçülen renk değişim değerleri karşılaştırıldı. Ayrıca aynı firmanın farklı translüsent tonlarının $\Delta E00$ değerleri farklı arka planlarda karşılaştırıldı. One-way ANOVA ve Tukey's post-hoc testleri istatistiksel analiz için kullanıldı. ( $\alpha = 0.05$ ). <b>Bulgular:</b> Mine kompozitleri dentin ile tabakalanarak kullanıldığında hep yalnız mine kompozitlerinin $\Delta E00$ değerlerinden daha düşük değerler gösterdi ( $p<0.05$ ). Aynı kompozit rezin örneklerin farklı arka planlardaki $\Delta E00$ değerleri karşılaştırıldığında sadece siyah arka planda ölçülen FU mine diğer iki arka planda ölçülen $\Delta E00$ değerlerinden yüksek bulunmuştur ( $p<0,05$ ). Aynı firmanın farklı translüsent tonları farklı arka planda karşılaştırıldığında $\Delta E00$ sıralaması tüm arka planlar için mine > dentin $\geq$ mine+ dentin şeklinde bulunmuştur. <b>Sonuç:</b> Farklı arka planlar opak bir kompozit rezin olan dentin kompoziti içeren örneklerin renk değerlendirmesini etkilememiş fakat translüsent bir kompozit rezin olan FU minenin renk değerlendirmesini etkilemiştir. Translüsent kompozit rezinler daha opak kompozit rezinlerle tabakalanarak uygulandıklarında daha doğru renk değerlendirmesi yapılabilir.

**To cite this article:** Kaya İ, Erol A, Çobanoğlu N. Evaluation of the Effect of Background Color on the Color Change of Composite Resins of Different Translucencies, NEU Dent J. 2024;6(Special Issue):88-96.  
<https://doi.org/10.51122/neudentj.2024.119>

\*Corresponding Author: İrem Kaya, [irm.ky55@gmail.com](mailto:irm.ky55@gmail.com)



## **INTRODUCTION**

Since their introduction in the 1960s, resin composites have become one of the commonly used materials in aesthetic dentistry due to their sufficient strength, superior aesthetic qualities, cost-effectiveness compared to ceramics, and ability to bond to dentin and enamel. Natural-looking aesthetics are preferred over artificial ones in general.<sup>1</sup> An aesthetic restoration should provide a natural appearance that satisfies the patient, in addition to ensuring functionality.<sup>2</sup> In this sense, restorations should imitate the color and translucency of natural teeth for optimal aesthetic appearance. Translucency gives the restoration a genuine aspect by giving it a natural and lifelike appearance.<sup>3</sup> In restorations, achieving the desired optical properties of teeth sometimes requires using only a universal resin. In other cases, opaque (dentin) resins are necessary to address regional high value needs of the tooth and to conceal the dark oral cavity background. These opaque resins are occasionally used alone on the buccal surface of the restoration but are often covered with a more translucent enamel composite. To enhance the optical properties of the incisal area of teeth, resins with higher translucency are used.<sup>4</sup>

In aesthetic dentistry, choosing the right aesthetic materials that closely resemble real teeth is a critical first step. Dental and resin composite materials are semi-transparent materials, and the difference in light transmittance affects their clinical appearance.<sup>5</sup>

The instrumental color measurement of semi-transparent materials depends on the background conditions. When light reflects onto a semi-transparent sample against a bright or white background, a substantial amount of the light reaching the background is reflected. In contrast, if the sample is against a matte or black background or in a light trap, the amount of reflection is significantly reduced.<sup>6</sup>

Changes in color parameters brought about by the semi-transparent material's filtering effects while utilizing a solid background are impacted by interactions including optical scattering, absorption, the semi-transparent material's thickness, and background reflections.<sup>7</sup> To accurately assess the color of dental resin composites, it might be preferable to exclude the influence of background reflection. Initially, color changes were evaluated without a background color and subsequently on a white plate, highlighting considerable variations in color alteration based on the background used.<sup>8</sup> However, in studies evaluating the color stability of composite resins, discoloration occurring on the back surface, for example, in more translucent materials, can significantly affect the measured color from the top surface, leading to incorrect assessments compared to opaque materials. Emulating scenarios where more translucent resins like enamel composites are layered over dentin, or using a black background that could eliminate the effect of discoloration on the back surface, may be beneficial for achieving more accurate results.

The aim of this study is to evaluate the effect of background color on the assessment of color change in composite resins with different levels of translucency. The null hypothesis of the study:

- 1- There is no difference between the color change values of samples prepared from the same company's composite resins.
- 2- There is no difference between the color change values of the same composites measured on different backgrounds.

## **MATERIALS AND METHODS**

In our study, Estelite  $\Sigma$  Quick (EQ) CE (enamel), OA2 (dentin) (Tokuyama, Japan) and Filtek Ultimate (FU) A2 enamel and A2 dentin (3M Espe, Germany) composite resins were used. The compositions of the composites are provided in Table 1.

**Table 1.** Restorative materials used in the study

Material	Type	Contents	Filler Particle Amount	Manufacturer Company
Tokuyama Estelite Quick Sigma	Supra-nano spherical hybrid	<b>Matrix:</b> Bis-MPEPP, Bis-GMA, UDMA TEGDMA <b>Filler:</b> Supra-nano spherical filler containing 200nm spherical SiO <sub>2</sub> -ZrO <sub>2</sub>	82(w/w)	Tokuyama Dental Corporation, Taitouku Tokyo, Japan
Filtek Ultimate	Nanohybrid	<b>Matrix:</b> UDMA Bis-GMA, Bis-EMA, TEGDMA, and PEGDMA resin <b>Filler:</b> Silica, zirconia, and clustered zirconia/silica aggregate filler ranging in size from 0.6 to 10 micrometers	78.5 w/w	3M ESPE, Seefeld, Germany

**Table 2.** Polishing wheel used in the study

	Abrasive Particle	Contents	Manufacturer Company
Twist Dia	Pre-polisher: 14µm High shine polisher: 10µm	Two-stage Kuraray, Japan Polishing system Diamond-coated flexible silicone spirals	Kuraray, Japan

Ten samples of each composite resin from both brands were prepared in disk shape either as enamel and dentin alone or layered as enamel+dentin (n=10). From the composite resins, samples in disk shape with a diameter of 8 mm and thickness of 2 mm were created using the plastic molds. For the enamel+dentin groups, samples were constructed by layering to achieve a structure with 1 mm of enamel and 1 mm of dentin, utilizing specially prepared molds. All samples underwent polymerization following the manufacturer's guidelines using an LED light source (Valo, Ultradent, South Jordan, USA). During polymerization, the light tip was placed in contact with a glass slide to minimize the light application distance, positioned centrally over the sample, and operated at 1000 mW/cm<sup>2</sup> power. Polymerization was verified using a radiometer for every set of 10 samples. The prepared samples were polished using two-stage diamond particle-impregnated polishing spirals (Twist Dia). Initially, a coarse-grit spiral (14µ) was applied without water cooling in a

counterclockwise direction for 20 seconds, followed by a fine-grit spiral (10µ) applied at 10000 rpm in a counterclockwise direction for another 20 seconds, also without water cooling. Following preparation, the samples were cleaned with distilled water and left in an oven with distilled water set at 37°C for 24 hours to finish the polymerization process. Following this, initial color measurements (baseline - T<sub>0</sub>) were taken. Coffee solution was chosen as the staining solution since it is one of the most consumed beverages worldwide. The coffee solution was made by dissolving 3.6 grams of coffee (Nescafe Gold Classic, Nestle, Turkey) in 300 ml of boiled distilled water, which was cooled to room temperature. Subsequently, 2 ml of the coffee solution was added to specimen storage containers containing the samples, which were then placed in an oven at 37°C for incubation. The coffee solution was freshly prepared each day. After the staining period (10 days later), the samples were washed under running tap water for 10 seconds, dried with



blotting paper, and then second color measurements (T1) were taken.

Color measurements were conducted by a single researcher using a portable spectrometer device, Vita Easyshade 5 (Vita-Zahnfabrik, Bad Säckingen, Germany). Each color measurement was taken under standard conditions with black, white, and gray backgrounds. Each measurement was repeated three times, and the average L\*, a\*, b\* values were recorded according to the CIEDE2000 color formulation. The device was calibrated every 10 measurements. Using the L\*, a\*, b\* values at T0 and T1 for each background,  $\Delta E00$  was calculated using the CIEDE2000 formula.

Tukey's post-hoc tests and One-way ANOVA were used for statistical analysis ( $\alpha = 0.05$ ).

## RESULTS

The  $\Delta E00$  values of EQ and FU composite groups are presented in Table 3 and 4.

**Table 3.** The mean and standard deviation  $\Delta E00$  values of the EQ composite resin groups. The letters in the upper right indicate statistical differences between the columns.

Estelite $\Sigma$ Quick	$\Delta E00$ Mean $\pm$ Std. Deviation
White background-Enamel	4.81 $\pm$ 1.22 <sup>C</sup>
White background-Enamel+dentin	1.97 $\pm$ 0.31 <sup>A</sup>
White background-Dentin	2.69 $\pm$ 0.85 <sup>A,B</sup>
Gray background-Enamel	5.76 $\pm$ 0.54 <sup>C</sup>
Gray background-Enamel+dentin	2.79 $\pm$ 0.65 <sup>A,B</sup>
Gray background-Dentin	2.45 $\pm$ 0.47 <sup>A,B</sup>
Black background-Enamel	5.25 $\pm$ 0.70 <sup>C</sup>
Black background-Enamel+dentin	3.37 $\pm$ 0.59 <sup>B</sup>
Black background-Dentin	2.63 $\pm$ 0.45 <sup>A,B</sup>

**Table 4.** The mean and standard deviation  $\Delta E00$  values of the FU composite resin groups. The letters in the upper right indicate statistical differences between the columns.

Filtek Ultimate	$\Delta E00$ Mean $\pm$ Std. Deviation
White background-Enamel	9.54 $\pm$ 0.86 <sup>E</sup>
White background-Enamel+dentin	2.77 $\pm$ 0.74 <sup>A</sup>
White background-Dentin	8.98 $\pm$ 2.05 <sup>DE</sup>
Gray background-Enamel	9.13 $\pm$ 1.39 <sup>DE</sup>
Gray background-Enamel+dentin	3.64 $\pm$ 0.56 <sup>AB</sup>
Gray background-Dentin	7.27 $\pm$ 4.29 <sup>C,D</sup>
Black background-Enamel	10.95 $\pm$ 0.61 <sup>F</sup>
Black background-Enamel+dentin	4.63 $\pm$ 0.44 <sup>A,B</sup>
Black background-Dentin	6.18 $\pm$ 2.26 <sup>B,C,D</sup>

The  $\Delta E00$  change values of the samples range from 1.97 $\pm$ 0.31 to 10.95 $\pm$ 0.61. The enamel groups' samples in both composite groups displayed the greatest color change, whereas the dentin-containing composite groups' samples displayed the lowest values.

Significantly lower  $\Delta E00$  values were observed when enamel composites were coated with dentin than with enamel-only composites for both brands across the entire background ( $p < 0.05$ ). When comparing the  $\Delta E00$  values of the same composite resin samples across different backgrounds, it was found that only the Filtek Ultimate (FU) enamel measured on the black background had higher  $\Delta E00$  values compared to those measured on the other two backgrounds ( $p < 0.05$ ) (Figure.1-2). The order of  $\Delta E00$  values was enamel > dentin  $\geq$  enamel + dentin in all backgrounds for both composites.

## DISCUSSION

Because composite resins can mimic the natural appearance of teeth, they are now the material of choice for aesthetic restorations.<sup>9</sup> Modern dental resin composites used for restorative purposes vary mainly in terms of their resin matrix, particle size, and shape, providing a diverse array of options for selection.<sup>10,11</sup>

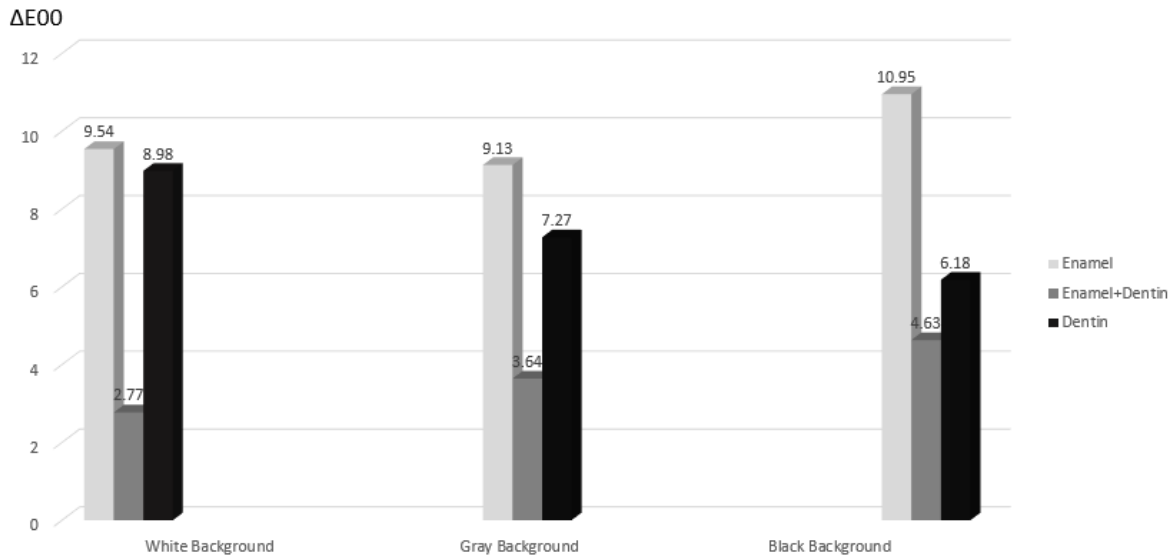


Figure 1. Color change ( $\Delta E_{00}$ ) values measured on different backgrounds for Filtek Ultimate.

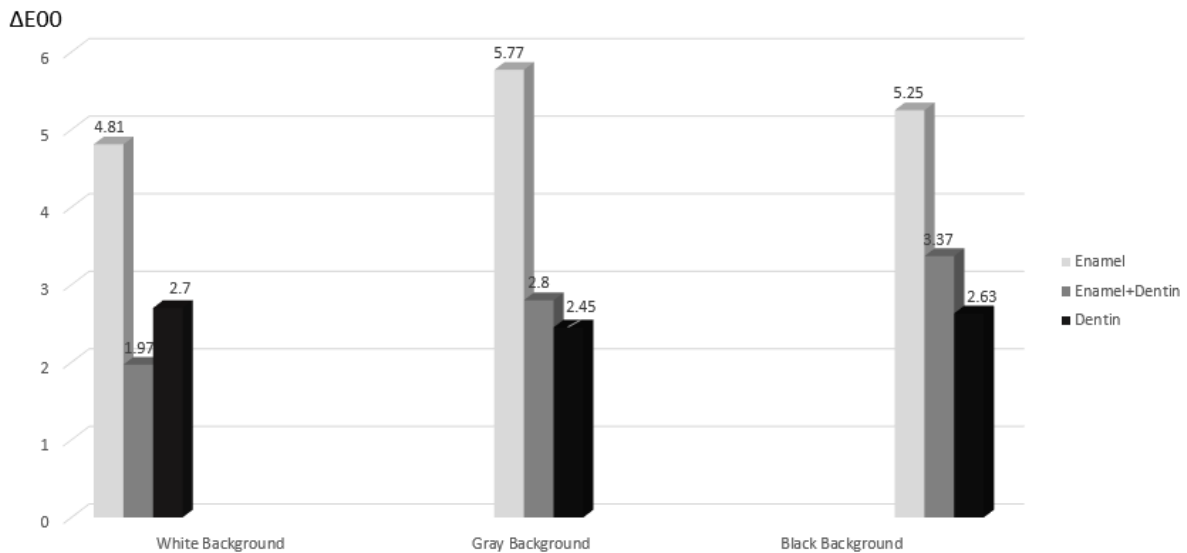


Figure 2. Color change ( $\Delta E_{00}$ ) values measured on different backgrounds for Estelite  $\Sigma$  Quick.

In our study, two nanohybrid composite resins (Filtek Ultimate, Estelite  $\Sigma$  Quick) were used. Composite resin samples in this study were prepared by placing them into 2 mm silicone molds, similar to the method described in the study and Bagheri et al.<sup>12</sup>

Recently, new systems have been introduced to streamline the polishing process for resin composites, with Clearfil Twist Dia being one of them. According to a study by Korkut et al.,<sup>13</sup> which examined how various polishing systems affect the discoloration of microhybrid and nanohybrid composite resins,

the spiral-shaped Clearfil Twist Dia polishing system was found to be more effective and advantageous compared to other systems. In our study, after preparing the composite samples, we employed Clearfil Twist Dia spiral disks for a two-stage polishing process, each stage lasting 20 seconds.

Güler et al.<sup>14</sup> reported that the normal consumption time for a cup of coffee is 15 minutes, and regular coffee consumption among daily drinkers averages 3.2 cups per day. In our study, samples were immersed in coffee for 10 days, which approximately simulates 10 months of coffee consumption.

In dentistry, besides visual assessment, instrumental color measurement can be performed using spectrophotometers and colorimeters. Consistent with previous studies,<sup>15-16</sup> to eliminate biases associated with human eye evaluation, in our study, color measurements were conducted using the portable spectrometer device Vita Easyshade 5 (Vita-Zahnfabrik, Bad Säckingen, Germany).

For the evaluation of composite resin colors, CIELAB ( $\Delta E_{ab}$ ) and CIEDE2000 ( $\Delta E_{00}$ ) formulas can be used. The CIEDE2000 formula incorporates three weighting functions: hue, value, and chroma. It has been reported that the CIEDE2000 system provides a better indicator of perceptibility by the human eye and the acceptability of color changes.<sup>16-17</sup> Perceptibility refers to the smallest color difference perceived by the human eye, whereas acceptability means the color difference between a restoration and an adjacent tooth being acceptable.<sup>18</sup> Data obtained from the CIEDE2000 formula were adjusted according to the perceptibility and acceptability thresholds defined by Paravina et al.<sup>18</sup> as  $\Delta E_{00} < 0.8$  units and  $\Delta E_{00} > 1.8$  units, respectively. In our study, all measurements taken after exposure to coffee were above the acceptability threshold of 1.8 units, similarly with Ertaş et al.<sup>19</sup>

In our study, it was observed that when enamel composites were used alone, they showed more color change than dentin composites, but when they were used layered with dentin, there was no difference between them and dentin alone, and they showed less color change than enamel composites. For this reason, the first hypothesis of our study which there is no difference between the color change values of samples prepared from the same company's composite resins was rejected. Similarly earlier research has indicated that translucent composites undergo greater color changes than opaque composite resins.<sup>20,21</sup> Lago et al.<sup>22</sup> observed that enamel composites colored with red wine showed significantly

more color change compared to dentin composites. Similarly, Mada et al.<sup>23</sup> found in their study that Filtek Supreme 3M composite left in coffee solution exhibited more discoloration in the enamel composite compared to the body composite. They suggested that this effect likely stems from the interaction and absorption differences between the staining solution and the organic matrix of the composite resins.

Furthermore, another study indicated that composite resin shades with lower chroma tended to exhibit reduced color stability compared to higher chromatic shades.<sup>20</sup> It was suggested that pigments and unreacted components, which could oxidize over time, might compromise optical stability, particularly in highly translucent resins where these effects could be more noticeable.<sup>24</sup>

Çobanoğlu et al.<sup>21</sup> discovered that enamel composites showed more color change than dentin and body composite resins when they measured color on a white background after exposure to coffee. They hypothesized that, due to the enamel hues' greater translucency, the stains on the back of the samples could be more noticeable than with opaque resins. In the current study, we tried to reveal the effect of two different methods, which are predicted to be more accurate in evaluating the color of an enamel composite resin layer that will not be exposed to coloring solution from the back side when applied to dentin tissue or dentin composite, similar to its use in the clinic. In the first method, the enamel composite was layered with dentin, while in the second method, the sample prepared only with enamel composite was exposed to discoloration, so even if the backside also became discolored, measurements were taken on a black background under the assumption that the reflected color from the back would be similar before and after discoloration.

Samples where enamel composites were layered with dentin showed less color change

than samples prepared with enamel alone. Considering these results, since enamel composites are mostly used in the clinic by applying them on dentin tissue or dentin composites, when evaluating the color stability of enamel composites, applying them layered with dentin composites rather than alone may give more accurate results. In this way, the effect of the background color on the evaluation will be reduced.

Conversely, however when comparing the  $\Delta E_{00}$  values of the same composite resin samples on different backgrounds, only the  $\Delta E_{00}$  value measured on a black background for FU enamel was found to be higher than the  $\Delta E_{00}$  values measured on the other two backgrounds ( $p < 0.05$ ). For this reason, the second hypothesis of our study which there is no difference between the color change values of the same composites measured on different backgrounds was rejected. In color measurement, the effect of the background is a highly debated topic. Stefano Ardu's review<sup>15</sup> suggested that the background has no effect or minimal effect on color perception. Ardu reported that black and gray backgrounds simulate the intraoral environment better than a white background. In our study, the background did not affect the dentin and dentin-layered enamel groups but did influence the color change in the FU Enamel group.

In a study examining resin translucency, shades that were more translucent showed lower lightness, lower chroma, and higher hue. This translucency was found to increase the effect of a black background.<sup>25</sup> This explanation is consistent with the color change values measured on a black background, contrary to our expectations from this study. Compared to opaque resins, the black background color may have been more pronounced before discoloration in the translucent enamel composite than after discoloration. For this reason, the color change may have been found more on the black background than on other

backgrounds.

In our study, the appearance of greater color change for FU enamel when seen against a black background, such as the oral cavity, compared to when layered with dentin, necessitates considering the effect of a black background when using translucent materials for aesthetic restorations.

Furthermore, in our study, the variation in background did not statistically significantly affect the ranking of color change values for composite resins. The hypothesis that change in background does not affect the order of color change values for composite resins has been accepted. The order of  $\Delta E_{00}$  values was enamel > dentin  $\geq$  enamel + dentin in all backgrounds for both composites.

## **CONCLUSION**

Different backgrounds did not affect the color evaluation of samples containing an opaque composite resin, dentin composite. However, the color change value of FU enamel, which is a translucent composite resin, was influenced, resulting in higher color change values when seen against a black background. This outcome should be taken into consideration, especially in scenarios such as the taking the oral cavity where a black background is involved into consideration. Moreover, placing translucent composite resins over less transparent ones improves the precision of color assessments.

## **Ethical Approval**

This study is a pilot study and does not require ethical approval.

## **Financial Support**

The authors declare that this study received no financial support.

## **Conflict of Interest**

The authors deny any conflicts of interest related to this study.

**Author Contributions**

Design: TS, AO, TK, Data collection or data entry: TS, TK, Analysis and interpretation: TS, AO, Literature search: TS, A, YO, TK, Writing: TS, AO.

**REFERENCES**

1. Yu B, Ahn J-S, Lee Y-K. Measurement of translucency of tooth enamel and dentin. *Acta Odontol Scand.* 2009;67:57-64.
2. Dietschi D. Free-hand composite resin restorations: a key to anterior aesthetics. *Pract Periodontics Aesthet Dent.* 1995;7:15-25.
3. Lee Y-K, Powers JM. Calculation of colour resulting from composite/compomer layering techniques. *J Oral Rehabil.* 2004;31:1102-8.
4. Arimoto A, Nakajima M, Hosaka K, et al. Translucency, opalescence and light transmission characteristics of light-cured resin composites. *Dent Mater.* 2010;26:1090-7.
5. Arikawa H, Fujii K, Kanie T, et al. Light transmittance characteristics of light-cured composite resins. *Dent Mater.* 1998;14:405-11.
6. Lee Y-K, Lim B-S, Kim C-W. Effect of surface conditions on the color of dental resin composites. *J Biomed Mater Res.* 2002;63:657-63.
7. O'Brien WJ, Johnston WM, Fanian F. Double-layer color effects in porcelain systems. *J Dent Res.* 1985;64:940-3.
8. Hosoya Y, Goto G. Color changes of light-cured composite resins. *J Clin Pediatr Dent.* 1992;16:247-52.
9. Albuquerque PPAC, Bertolo ML, Cavalcante LMA, et al. Degree of conversion, depth of cure, and color stability of experimental dental composite formulated with camphorquinone and phenanthrenequinone photoinitiators. *J Esthet Restor Dent.* 2015;27:49-57.
10. Ferracane JL. Resin composite-state of the art. *Dent Mater.* 2011;27:29-38.
11. Sakaguchi RL, Ferracane J, Powers JM. *Craig's restorative dental materials.* 14th ed. St. Louis: Elsevier; 2018. p. 136-44.
12. Bagheri R, Burrow MF, Tyas M. Influence of food-simulating solutions and surface finish on susceptibility to staining of aesthetic restorative materials. *J Dent.* 2005;33:389-98.
13. Korkut B. Evaluation of the effect of polishing materials on discoloration of microhybrid and nanohybrid resin composites. *Turk Klin J Dent Sci.* 2021;27:451-61.
14. Guler AU, Yilmaz F, Kulunk T, et al. Effects of different drinks on stainability of resin composite provisional restorative materials. *J Prosthet Dent.* 2005;94:118-24.
15. Ardu S, Braut V, Di Bella E, et al. Influence of background on natural tooth colour coordinates: an in vivo evaluation. *Odontology.* 2014;102:267-71.
16. Tekçe N, Tuncer S, Demirci M, et al. The effect of different drinks on the color stability of different restorative materials after one month. *Restor Dent Endod.* 2015;40:255-61.
17. Turgut S, Kilinc H, Eyupoglu GB, et al. Color relationships of natural anterior teeth: An study. *Niger J Clin Pract.* 2018;21:925-31.
18. Paravina RD. New shade guide for tooth whitening monitoring: visual assessment. *J Prosthet Dent.* 2008;99:178-84.
19. Ertaş E, Güler AU, Yücel AC, et al. Color stability of resin composites after immersion in different drinks. *Dent Mater J.* 2006;25:371-76.
20. Mutlu-Sagesen L, Ergün G, Ozkan Y, et al. Color stability of a dental composite after immersion in various media. *Dent Mater J.* 2005;24:382-90.
21. Çobanoğlu N, Sağ Güngör F, Abdulateef OF, et al. Effect of translucency on color stability of resin-based composites. *Bezmialem Sci.* 2023;11:213-20.
22. Lago M, Mozzaquatro LR, Rodrigues C, et al. Influence of Bleaching Agents on Color and Translucency of Aged Resin

- Composites. *J Esthet Restor Dent.* 2017;29:368-77.
23. Mada DC, Gasparik C, Irimie AI, et al. Evaluation of chromatic changes of a nanocomposite resin using the new whiteness index. *Clujul Med.* 2018;91:222-8.
24. Piccoli YB, Lima VP, Basso GR, et al. Optical Stability of High-translucency Resin-based Composites. *Oper Dent.* 2019;44:536-44.
25. Salgado VE, Rego GF, Schneider LF, et al. Does translucency influence cure efficiency and color stability of resin-based composites? *Dent Mater.* 2018;34:957-66.

# Comparison of Microleakage of Monolithic Zirconia after Surface Treatment and Thermal Cycles Using Data Analysis Software

Emel ARSLAN<sup>1</sup>  Halil Nuri ÖZDEMİR<sup>2\*</sup>  Hatice SEVMEZ<sup>3</sup> 

<sup>1</sup> Ass. Prof., Bolu Abant İzzet Baysal University, Faculty of Dentistry, Department of Prosthodontic, Bolu, Türkiye, emel.arslan08@outlook.com

<sup>2</sup> Res. Ass., Bolu Abant İzzet Baysal University, Faculty of Dentistry, Department of Prosthodontic, Bolu, Türkiye, ha.halil.nuri1453@gmail.com

<sup>3</sup> Ass. Prof., Bolu Abant İzzet Baysal University, Faculty of Dentistry, Department of Prosthodontic, Bolu, Türkiye, hsevmez@hotmail.com

Article Info	ABSTRACT
<b>Article History</b> <b>Received:</b> 16.06.2024 <b>Accepted:</b> 14.10.2024 <b>Published:</b> 15.10.2024	<b>Objective:</b> The aim of this study was to investigate the microleakage of monolithic zirconia after different surface treatments using computer software. <b>Materials and Methods:</b> Three different monolithic zirconia ML (Multilayered), STML (Super Translucent Multilayered), UTML (Ultra Translucent Multilayered) were prepared as discs with a diameter of 15 mm and a thickness of 1.2 mm. Four different surface treatments (Hydrofluoric acid, Tribochemical silica coating, Hydrofluoric acid application + Tribochemical silica coating, Milling + Tribochemical silica coating + Hydrofluoric acid application) were applied to the prepared samples according to their groups (n=8). Samples, Group C: Control group, Group HF: Hydrofluoric acid application, Group T: Tribochemical silica coating, Group HF+T: Hydrofluoric acid application + Tribochemical silica coating, Group F+HF+T: Milling + Tribochemical silica coating + Hydrofluoric acid application, then adhesive system was applied to all specimens and repaired with resin cement. The specimens were thermocycled for one year aging and then immersed in basic fuchsin solution to evaluate microleakage. The specimens were separated with a micro-cut device and evaluated under a stereomicroscope. The dimensions of the images were measured in Python program and the permeability and surface treatments of the zirconia samples were compared. Statistical analysis was performed by two-way ANOVA (p<0.05). <b>Results:</b> UTML F+HF+T showed the lowest microleakage (12.15 ± 1.69), while ML C showed the highest microleakage (73.93 ± 1.59). Among the zirconia specimens, the highest adaptation was obtained in the UTML zirconia (37.59 ± 23.58). <b>Conclusion:</b> According to the data obtained, milling + tribochemical silica coating + acid application surface treatments are recommended for the repair of monolithic zirconia restorations. The sintering temperature and Yttrium Oxide (Y <sub>2</sub> O <sub>3</sub> ) content of the monolithic zirconia used are effective factors in microleakage after repair.
<b>Keywords:</b> Monolithic zirconia, Microleakage, Repair, Surface Treatment, Thermal Cycle.	

## Monolitik Zirkonyaların Yüzey İşlemleri ve Termal Siklus Sonrasında Mikrosızıntılarının Veri Analizi Yazılımıyla Karşılaştırılması

Makale Bilgisi	ÖZET
<b>Makale Geçmişi</b> <b>Geliş Tarihi:</b> 16.06.2024 <b>Kabul Tarihi:</b> 14.10.2024 <b>Yayın Tarihi:</b> 15.10.2024	<b>Amaç:</b> Bu çalışmanın amacı; monolitik zirkonyalara uygulanan farklı yüzey işlemleri sonrasında mikrosızıntılarını bilgisayar yazılımıyla incelemektir. <b>Gereç ve Yöntemler:</b> Çalışmada kullanılmak amacıyla, üç farklı monolitik zirkonya ML (Multilayered), STML (Super Translucent Multilayered), UTML (Ultra Translucent Multilayered) 15 mm çapında 1,2 mm kalınlığında disk şeklinde hazırlandı. Hazırlanan örnekler gruplarına göre dört farklı yüzey işlemi (Hidroflorik asit, Tribokimyasal silika kaplama, Hidroflorik asit uygulama+ Tribokimyasal silika kaplama, Frez ile aşındırma + Tribokimyasal silika kaplama + Hidroflorik asit uygulaması) uygulandı (n=8). Örnekler, Grup C: Kontrol grubu, Grup HF: Hidroflorik asit uygulama, Grup T: Tribokimyasal silika kaplama, Grup HF+T: Hidroflorik asit uygulama+ Tribokimyasal silika kaplama, Grup F+HF+T: Frez ile aşındırma, + Tribokimyasal silika kaplama + Hidroflorik asit uygulaması şeklinde 5 gruba ayrıldı, daha sonra tüm örnekler adeziv sistem uygulanıp rezin siman ile tamir yapıldı. Örnekler bir yıllık yaşlandırma amacıyla termal-siklusa tabi tutulup daha sonrasında mikrosızıntıyı değerlendirmek amacıyla bazik fuksin solüsyonuna daldırıldı. Micro-cut cihazı ile ayrılan örnekler stereomikroskop altında değerlendirildi. Alınan görüntülerin ölçüleri Python programında ölçülerek zirkonya örneklerin geçirgenliği ve yüzey işlemleri karşılaştırıldı. İstatiksel analiz iki yönlü ANOVA ile yapıldı (p<0,05). <b>Bulgular:</b> Örneklerden en düşük mikrosızıntıyı UTML F+HF+T gösterirken (12,15 ± 1,69), en yüksek mikrosızıntı ML C (73,93 ± 1,59) görüldü. Zirkonya örnekler arasında en yüksek adaptasyon UTML zirkonya örneklerde (37,59 ± 23,58) elde edildi. <b>Sonuç:</b> Elde edilen veriler doğrultusunda frezleme+ tribokimyasal silika kaplama+asit uygulama yüzey işlemleri, monolitik zirkonya restorasyonların tamiri açısından önerilmektedir. Kullanılan monolitik zirkonyanın sinterleme sıcaklığı ve içeriğindeki İtiryum Oksit (Y <sub>2</sub> O <sub>3</sub> ) tamir sonrası mikrosızıntıda etkili faktördür.
<b>Anahtar Kelimeler:</b> Monolitik Zirkonya, Mikrosızıntı, Yüzey İşlemi, Tamir, Termal Siklus.	

**To cite this article:** Arslan E, Özdemir HN, Sevmez H. Comparison of Microleakage of Monolithic Zirconia after Surface Treatment and Thermal Cycles Using Data Analysis Software. NEU Dent J. 2024;6(Special Issue):97-107.  
<https://doi.org/10.51122/neudentj.2024.120>

**\*Corresponding Author:** Halil Nuri ÖZDEMİR, [ha.halil.nuri1453@gmail.com](mailto:ha.halil.nuri1453@gmail.com)



This article is licensed under a Creative Commons Attribution-NonCommercial 4.0 International License (CC BY-NC 4.0)

## INTRODUCTION

Resin composites are commonly utilized in clinical dental practice due to their superior mechanical properties, excellent adhesion to tooth structures, ease of application, aesthetic appeal, and compatibility with minimally invasive dental techniques.<sup>1,2</sup> These materials offer the distinct advantage of reparability over time, as opposed to complete replacement of damaged restorations. Repair procedures mitigate the drawbacks of full replacement, which often involve extensive preparation and high costs.<sup>3</sup>

Clinically, crowns have been observed to experience issues such as crumbling and delamination after prolonged use, which leads to restoration failures.<sup>4</sup> Advances in materials science have introduced high-purity, highly translucent yttria-stabilized tetragonal zirconia polycrystalline (Y-TZP) ceramics, which address the typical limitations of zirconia ceramics, such as inadequate translucency and a monolayer appearance.<sup>5</sup> To establish a strong bond between tooth structures and porcelain restorations, various surface treatments are employed. Acid etching is one such method, although it is less effective with zirconia restorations due to their structural properties.<sup>6-8</sup> Various methods, such as etching, laser irradiation, and nano-grade aluminum coating, are used to create surface roughness that enhances the micromechanical bond between the zirconia and the resin cement.<sup>9</sup>

Despite these modifications, the micromechanical bond remains insufficient, thus necessitating the use of primers with resin cements. For optimal cementation of zirconia restorations, self-adhesive, resin-based agents and universal adhesives containing 10-methacryloyloxydecyl dihydrogen phosphate (10-MDP) are recommended.<sup>10</sup> Other surface treatments, such as tribochemical silica coating—which involves air-etching the ceramic surface with alumina particles coated

with silica—have been developed to enhance the bonding between resin cement and zirconia.<sup>11</sup> Abrasion with diamond milling is a method frequently used on the fracture surface when repairing in the mouth. Abrasion removes contamination from the fracture surface. It also provides a mechanical connection by providing visibly rougher surfaces than other methods.<sup>12</sup>

Microleakage testing of dental materials is a generally accepted technique for the evaluation of margin integrity. Microleakage refers to the clinically undetectable passage of bacteria, fluids, molecules, or ions in the microgaps ( $10^{-6}$   $\mu\text{m}$ ) between a cavity wall and the restorative material applied over it. The evaluation of microleakage is conducted using the basic fuchsin stain methylene blue.<sup>13</sup>

While there is a relative of studies examining the durability of monolithic zirconia following repair, there is a significant gap in the literature about microleakage and surface treatments. This study aimed to evaluate the impact of different surface treatments on the repair of aged resin composites using monolithic zirconia. The null hypothesis was that there would be no significant difference between the microleakage of disc-shaped specimens repaired with various aged monolithic zirconia materials and surface treatments.

## MATERIAL and METHODS

### Preparation of the Samples

Three types of monolithic zirconia blocks with different translucency properties were used: multilayered (ML), ultra super translucent multilayered (UTML), and super translucent multilayered (STML) (Table 1). Power and sample size analysis for 'f test - ANOVA: Fixed effects, special, main effects, and interactions' was conducted using G\*Power v3.1.9.2. Sample size was determined by referencing the study according to the 95% confidence interval (CI;  $1-\alpha$ ), 95% test power ( $1-\beta$ ), effect size  $f=0.374$  and analysis of variance (ANOVA)



test.<sup>14</sup> A total of 120 samples were included in the study. All were of the same brand (Katana; Kuraray, Noritake Dental Inc, Tokyo, Japan) and were manufactured using a CAM (Yenadent D43, Yenadent Ltd, İstanbul, Türkiye) system. The sample was designed using computer software (Meshmixer, California, USA) and pre-sintered in a laboratory with a sintering furnace (Everest Therm; KaVo Dental GmbH, Biberach, Germany) following the manufacturer's instructions. According to the international standard ISO 6872, the final dimensions were in the form of a disk 15 mm in diameter and 1.2 mm in thickness, consistent with the methodology used in scientific studies on the durability of all-ceramic materials (Figure 1).<sup>15</sup>

The thickness of the samples was checked using a digital caliper. The prepared ceramic samples were ultrasonically washed for two minutes, then air-dried and prepared for surface treatment.



**Figure 1.** Preparation of Specimens

**Table 1.** Materials used in the study, manufacturer, composition and flexural strength.

Material	Code	Manufacturer	Composition	Flexural Strength (MPa)
Multilayer	ML	Kuraray, Noritake Dental Inc., Tokyo, Japan	ZrO <sub>2</sub> + HfO <sub>2</sub> + Y <sub>2</sub> O <sub>3</sub> >99%, (Y <sub>2</sub> O <sub>3</sub> ) 4%, (HfO <sub>2</sub> ) ≤5%, other oxides ≤1%	1125
Supertranslucent	STML	Kuraray, Noritake Dental Inc., Tokyo, Japan	(ZrO <sub>2</sub> + HfO <sub>2</sub> + Y <sub>2</sub> O <sub>3</sub> ) >99 %, (Y <sub>2</sub> O <sub>3</sub> ) 5.3 %, (HfO <sub>2</sub> ) ≤5 %, other oxides ≤1 %	748
Ultraslucent	UTML	Kuraray, Noritake Dental Inc., Tokyo, Japan	(ZrO <sub>2</sub> + HfO <sub>2</sub> + Y <sub>2</sub> O <sub>3</sub> ) >99 %, (Y <sub>2</sub> O <sub>3</sub> ) 5.4 %, (HfO <sub>2</sub> ) ≤5 %, other oxides ≤1 %	557

### Surface Treatment of the Samples

The prepared samples were randomly divided into five groups. For group C (the control group), no surface treatment was applied to the samples. For group HF (hydrofluoric acid), 9% HF (Ultradent Porcelain Etch; Ultradent Inc., South Jordan, USA) was applied to the samples and left for 60 seconds. After two minutes of washing, the HF was removed. Silane (Ultradent, Utah, USA) was then applied to the sample surfaces and allowed to dry for 60 seconds. For group T, tribochemical silica coating was applied. Samples were roughened with 30 µm silica-coated Al<sub>2</sub>O<sub>3</sub> particles (3M ESPE, Seefeld, Germany) for 15 seconds under 3 bars of pressure.<sup>16</sup> A distance of 10 mm was left between the application tip of the blasting

device and the sample. All operations were performed by a single user. After the procedure, the silica-coated samples were cleaned with 96% isopropyl alcohol using an ultrasonic device (Euronda, Sassuolo, Italy). For group HF+T, HF and tribochemical silica coating were applied. A 9% HF solution was applied to the samples and allowed to remain for 60 seconds. After two minutes of washing, the HF was removed. Silane was then applied to the sample surfaces and allowed to dry for 60 seconds. The surfaces were then roughened with 30 µm silica-coated Al<sub>2</sub>O<sub>3</sub> particles for 15 seconds under 3 bars of pressure. A distance of 10 mm was left between the application tip of the silica coating and the sample. After the procedure, the silica-coated samples were cleaned with 96% isopropyl alcohol using an ultrasonic device.

Group F+HF+T involved the use of milling burs and HF as well as tribochemical silica coating applications. The samples were roughened by abrading in the same direction for ten seconds with finger pressure by the same operator using 125 µm green-banded diamond burs (Acurata, Thurmansbang, Germany) with a high-speed water-cooled clinical aerator (NSK, Nagaoka, Japan). The device was calibrated by a dental technician with professional assistance. Self-adhesive resin cement (Panavia SA Cement, Kuraray, Osaka, Japan) was bonded to the surfaces with special molds prepared for standardization. A mold with a diameter of 15 mm and a thickness of 2.5 mm was created using pink wax (Polywax, München, Germany). This mold was placed in silicone impression material (Zhermack, Badia Polesine, Italy). The samples, after the adhesive was applied, were then placed in the mold. The polymerization process was performed with an LED (light emitting-diode) light device (Bredent GmbH & Co KG, Senden, Germany) for 40 seconds. The measurements of luminous flux, luminous intensity, and energy density from the LED device were recorded with the Bluephase meter II radiometer (Ivoclar Vivadent, Schaan, Switzerland), and the accuracy was determined by comparison with the technical specifications and standards of the LED device itself. Next, the repair material was removed from the mold. After being bonded to each other with adhesive systems, the samples were soaked in 37°C distilled water for 24 hours and thermal-cycled to mimic aging. The samples were subjected to the aging procedure through a 10.000-cycle thermodynamic cyler (Gökçeler Makine, Sivas, Türkiye) at 5–55°C with a 30-second dwell time.<sup>17</sup>

### **Evaluation with a Microscope**

Two coats of blue nail polish (Flormar, Kocaeli, Türkiye) were applied to all areas of the zirconia, except for 1 mm of the connection area. To evaluate marginal leakage, the samples

were soaked in 0.5% basic fuchsin at 37°C for 24 hours. After staining, the prepared samples were cut in half to evaluate the microleakage. Using a linear precision saw (Isomet 1000 Linear Precision Saw; Beuhler, Illinois, USA), the specimens were cut in half at a speed of 600 rpm. The cutting process took into account the thickness of the water-cooled cutting blade, which is 0.3 mm. The prepared samples were kept in basic fuchsin solution for one day to evaluate the coloration of the microleakage areas. Then, images of the samples were taken under a stereomicroscope (SZx10 Olympus, Tokyo, Japan) at 25x magnification) (Figure 2). Calibration was performed by placing a ruler within the field of view of the microscope and utilizing the microscope's measurement capabilities. Surface images were captured once the ruler's measurements were aligned with the measurements provided by the microscope's software. The images were transferred to a computer program (Pycharm 3.12.3, Prague, Czech Republic), and the dimensional sizes of the images were obtained in square millimeters (mm<sup>2</sup>) through the program (Figure 3).

### **Statistical Analysis**

Statistical analyses were performed using the SPSS software (IMB SPSS Statistics for Windows version 14.0; IBM Corp., New York, USA). To assess the homogeneity of the composite and thickness variance distributions for each group (n = 8), the Shapiro-Wilk test was applied, and normal distributions were found. The measurement values for the monolithic zirconia types and the surface treatments were analyzed using a two-way ANOVA test, and the obtained values were compared using Tukey's test. The p-value's significance level was determined to be p<0.05.




Figure 2: Images of samples under the microscope

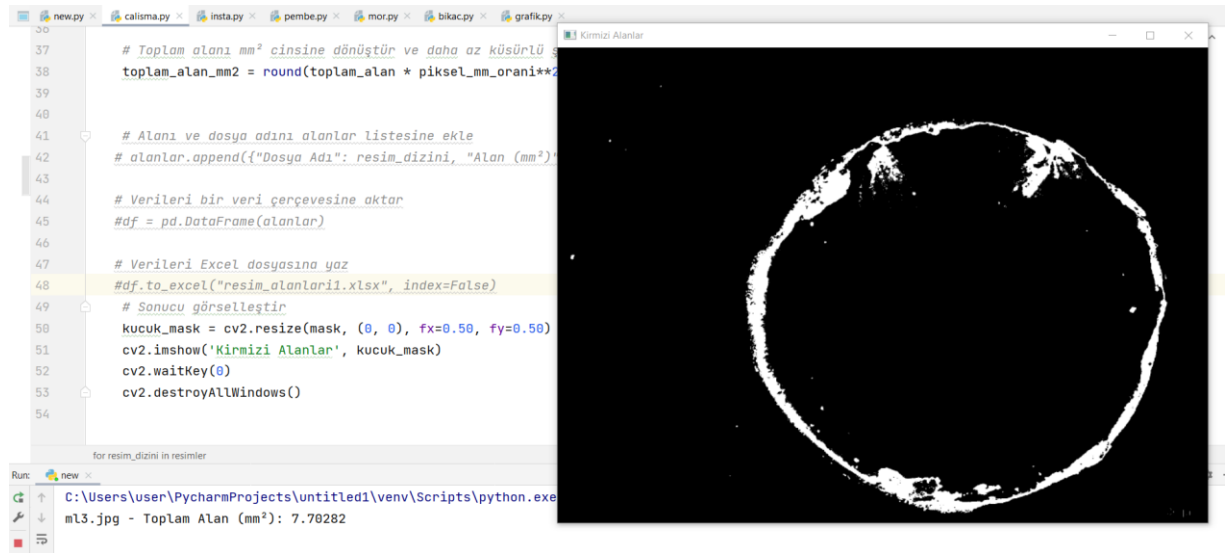

Figure 3. Measurement of microleakage areas in the Pycharm program

## RESULTS

A two-way ANOVA test showed a significant difference in the microleakage values of the monolithic zirconia types and the surface treatments ( $p < 0.001$ ) (Table 2). Table 3 presents the mean microleakage values and standard deviations (SD) of the monolithic zirconia types and the surface treatments. Group F+HF+T exhibited lower microleakage values compared to other surface treatments ( $p < 0.05$ ). When compared with other surface treatments, significant differences were observed among all groups ( $p < 0.05$ ). The lowest microleakage was observed in the control group. A significant difference was found between zirconia grades

for control and HF-treated surfaces ( $p < 0.001$ ). However, no significant difference was observed between UTML and STML on tribochemical silica-coated surfaces ( $p \geq 0.05$ ). The lowest microleakage value was obtained for UTML zirconia in the F+HF+T group ( $12.15 \pm 1.69$ ), while the highest microleakage value was found for ML zirconia in the control group ( $73.93 \pm 1.59$ ). No significant difference was observed between zirconia types in the control group ( $p \geq 0.05$ ), but significant differences were found between zirconia types when surface treatments were applied ( $p < 0.05$ ). Additional multiple comparison results are presented in Table 3 and Figure 4.

**Table 2:** Two-way ANOVA Test for the Effect of Monolithic Zirconia Types and Surface Treatments on Microleakage

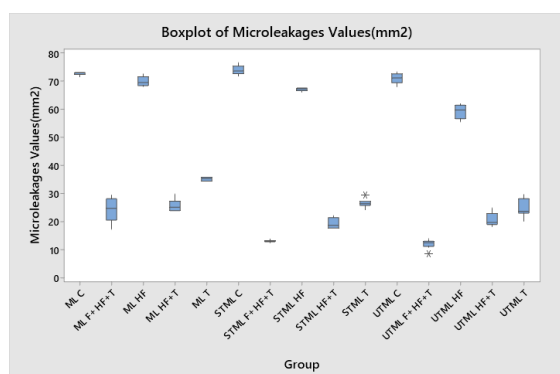
Microleakage	Type III Sum of Squares	df	Mean Square	F	Sig.	Partial Eta Squared
Corrected Model	66892.136 <sup>a</sup>	14	4778.010	1106.864	<0.001	0.993
Intercept	202517.827	1	202517.827	46914.874	<0.001	0.998
Material	1347.706	2	673.853	156.103	<0.001	0.748
Surface Treatment	64967.154	4	16241.789	3762.540	<0.001	0.993
Material * Surface Treatment	577.276	8	72.160	16.716	<0.001	0.560
Error	453.254	105	4.317			
Total	269863.218	120				
Corrected Total	67345.391	119				

a. R Squared = .993 (Adjusted R Squared = .992)

**Table 3:** Microleakage Descriptive Statistics

Microleakage	Zirconia Types			
	ML	STML	UTML	Total
Group C	73.93 ± 1.59 <sup>ab</sup>	71.00 ± 1.77 <sup>a</sup>	72.56 ± 1.82 <sup>ab</sup>	72.56 ± 1.82 <sup>A</sup>
Group HF	67.16 ± 0.58 <sup>bc</sup>	59.33 ± 2.49 <sup>c</sup>	65.51 ± 4.92 <sup>d</sup>	65.51 ± 4.92 <sup>B</sup>
Group T	35.25 ± 0.69 <sup>e</sup>	26.67 ± 1.52 <sup>f</sup>	24.77 ± 3.22 <sup>f</sup>	28.90 ± 5.07 <sup>C</sup>
Group HF+T	25.77 ± 2.12 <sup>f</sup>	19.38 ± 1.85 <sup>h</sup>	20.68 ± 2.40 <sup>gh</sup>	21.94 ± 3.48 <sup>D</sup>
Group F+HF+T	24.21 ± 4.43 <sup>fg</sup>	13.12 ± 0.38 <sup>i</sup>	12.15 ± 1.69 <sup>i</sup>	16.49 ± 6.17 <sup>E</sup>
Total	45.60 ± 21.80	40.05 ± 25.71	37.59 ± 23.58	41.08 ± 23.79

A-E: No difference between surface treatment with the same letter. a-i: No difference between zirconia types and surface treatment interactions with the same letter.

**Figure 4.** Boxplot of Microleakage values according to zirconium

## DISCUSSION

The results of this study revealed that the surface treatment techniques significantly affected the microleakage values after the repair procedures were performed on the monolithic zirconia ( $p < 0.05$ ). The highest mean marginal compliance values were observed in the burs+HF+ tribochemical silica coating treatments. Therefore, the null hypothesis tested in this study was rejected because our findings showed that there was a significant difference between the microleakage values of the

monolithic zirconia that was repaired using different surface treatments. In this study, a diamond bur of silica-coated aluminum oxide was used for mechanical surface roughening. The use of bonding agents increases the bond strength of the repair bonds.

Most clinicians prefer to use the bonding system that they already have in their practice rather than acquire a specialized bonding system for composite repair procedures.<sup>18-20</sup> However, the bonding potential of zirconia restorations is low, and there is no standard repair procedure. Different resin cements have been proposed for the repair of these restorations.<sup>21,22</sup>

The silica coating has been observed to produce microcracks on the surface of zirconia ceramics, increasing their strength.<sup>23</sup> The porcelain and the silane form a chemical connection when the silica creates a glassy coating on the ceramic surface. The results of our study corroborated this finding, as tribochemical silica coating demonstrated a

higher level of agreement compared to the other groups. In study, the marginal compatibility with the tribochemical silica coating was significantly increased compared to the control and HF treatments. This is due to the fact that the tribochemical silica coating provides chemical retention with the silica-coated zirconia surface because it binds to the silane more effectively than silica coating.<sup>24,25</sup> According to a recent study, the use of HF etching on both glass matrix and crystal surfaces resulted in the highest bond strength.<sup>26</sup> Moreover, the application of silane and HF to the ceramic surface prior to cementation has been documented to significantly enhance the bonding efficacy of silica-based ceramics.<sup>27,28</sup> However, it has been shown that the lack of a glassy phase or high crystal content causes HF etching to fail in ceramics reinforced with zirconia and alumina.<sup>29</sup> Ural et al.<sup>30</sup> found that HF application did not cause any changes in zirconia surface morphology. According to the results of the present study, the HF-treated groups exhibited reduced microleakage in surface marginal areas compared to the control group.

In HF applications, the protocols can vary considerably, particularly in terms of etching time and acid concentration.<sup>31,32</sup> These variations complicate the assessment of the definitive advantages of this surface treatment, making it challenging to establish a standardized approach for optimal bonding outcomes. In a systematic review, it was concluded that surface treatments with tribochemical silica particles and HF acid resulted in lower coupling than etching with  $\text{Al}_2\text{O}_3$  or diamond bur abrasives.<sup>33</sup> The current study contradict is incompatible with that systematic review. However, in this study, tribochemical silica coating and diamond milling were used together to reduce microleakage. In clinics, the combination of the two surface treatments may be preferred as a surface treatment for monolithic zirconia repairs.

Prolonged exposure of Y-TZP zirconia to low temperatures may cause different disadvantages. One of these is surface roughness. In addition, reduced durability results in bending force resistance that is sufficient to withstand chewing forces.<sup>34</sup> The addition of a stabilizer containing  $\text{Y}_2\text{O}_3$  as a component to the zirconia material can significantly improve the mechanical properties of zirconia and enhance its biological properties.<sup>35</sup> In the results of the current study, UTML (5.4%  $\text{Y}_2\text{O}_3$ ), with the highest  $\text{Y}_2\text{O}_3$  content, showed the least microleakage ( $12.15 \pm 1.69$ ), while ML (4%  $\text{Y}_2\text{O}_3$ ), with the lowest stabilizer content, showed the highest microleakage values among all of the surface treatments. The results suggest that increasing the  $\text{Y}_2\text{O}_3$  ratio may enhance the marginal compatibility of the material.

In addition, different sintering temperatures are likely to change the edge fit due to shrinkage as ceramic materials cool to room temperature.<sup>36</sup> This shrinkage depends on several factors, including material composition, density, and the sintering procedure.<sup>37</sup> Ersoy et al.<sup>38</sup> found that increasing the sintering temperature and decreasing the sintering time improve the mechanical properties of the zirconia structure. The sintering temperature of ML monolithic zirconia used in the current study was  $1500^\circ\text{C}$ , while the sintering temperature of the STML and UTML monolithic zirconia was  $1550^\circ\text{C}$ , as specified by the manufacturer. The differences in the microleakage values of the different experimental groups in this study may have been due to the stability of the zirconia samples and structural differences. With an increase in the sintering temperature, the zirconia samples were found to be completely sintered until the tetragonal stage, and no transformation was observed until the monoclinic stage.<sup>38,39</sup> New generation zirconia types include 4Y-PSZ (Katana ML), 5Y-PSZ (Katana STML), and 6Y-PSZ (Katana UTML). In modern dentistry,

the content of  $Y_2O_3$ , the proportion of tetragonal or cubic phases, and the material's fracture toughness are crucial factors for clinical applications. The addition of  $Y_2O_3$  to  $ZrO_2$  powder significantly increases the cubic  $ZrO_2$  phase. While this improves certain properties, it can reduce both flexural strength and fracture toughness.<sup>40</sup>

In this study, thermal cycling was applied for 10,000 cycles, which is equivalent to one year. However, D'Amario et al.<sup>41</sup> reported that thermal cycling significantly reduced the bond strength between zirconia and resin cement. In another study, thermal cycling with 10,000 cycles had no effect on bond strength, and even veneer ceramics showed higher bond strength after thermal cycling. In the present study, applying too many thermal cycles was found because it reduced bond strength.<sup>42</sup>

Additionally, the dye penetration method is often preferred in microscope studies due to its cost and ease of application.<sup>43</sup> In the current study, microleakage values were compared using the PyCharm 3.12.3 software to ensure objectivity, rather than relying on traditional scoring methods. Although AutoCAD software was used in previous studies, the data obtained with this program were automatically calculated numerically.<sup>14,44,45</sup>

The chief limitation of this study is that the oral environment cannot be replicated using different surface treatments and monolithic zirconia with different components. However, this study can guide future in-vivo and in-vitro studies. It will also inform clinicians about the microleakage that may occur after the preferred surface treatment for monolithic restoration repair.

## CONCLUSIONS

Conclusions obtained as a result of the limitations of the study; Mechanical and chemical treatments applied to the surface during the repair of monolithic restorations help reduce the risk of microleakage. The

components of the monolithic material influence the microleakage values. For minimizing the risk of microleakage, it is recommended that clinicians use monolithic zirconia with high  $Y_2O_3$  content with processes such as tribochemical silica coating and milling.

## Ethical Approval

This in-vitro study does not require ethics committee approval.

## Financial Support

The authors declare that this study received no financial support.

## Conflict of Interest

The authors deny any conflicts of interest related to this study.

## Author Contributions

Design: EA, HS, Data collection or data entry: EA, HS, Analysis and interpretation: EA, HS, Literature review: EA, Writing: EA, HNÖ, HS.

## REFERENCES

1. Joulaei M, Bahari M, Ahmadi A, Oskoe SS. Effect of different surface treatments on repair micro-shear bond strength of silica-and zirconia-filled composite resins. *J Dent Res Dent Clin Dent Prospects*. 2012;6:131-7.
2. Mamanee T, Takahashi M, Nakajima M, Foxton RM, Tagami J. Initial and long-term bond strengths of one-step self-etch adhesives with silane coupling agent to enamel-dentin-composite in combined situation. *Dent Mater J*. 2015;34:663-70.
3. Nassar M, Al-Fakhri O, Shabbir N, Islam MS, Gordan VV, Lynch CD, et al. Teaching of the repair of defective composite restorations in Middle Eastern and North African Dental Schools. *J Dent*. 2021;112:103753.
4. Rekow E, Silva N, Coelho P, Zhang Y, Guess P, Thompson V. Performance of dental ceramics: challenges for improvements. *J Dent Res*. 2011;90:937-52.
5. Tang Z, Zhao X, Wang H, Liu B. Clinical evaluation of monolithic zirconia crowns

- for posterior teeth restorations. *Medicine*. 2019;98:e17385.
6. Pereira GKR, Graunke P, Maroli A, Zucuni CP, Prochnow C, Valandro LF, et al. Lithium disilicate glass-ceramic vs translucent zirconia polycrystals bonded to distinct substrates: Fatigue failure load, number of cycles for failure, survival rates, and stress distribution. *J Mech Behav Biomed Mater*. 2019;91:122-30.
  7. Soares PM, Cadore-Rodrigues AC, Borges ALS, Valandro LF, Pereira GKR, Rippe MP. Load-bearing capacity under fatigue and FEA analysis of simplified ceramic restorations supported by Peek or zirconia polycrystals as foundation substrate for implant purposes. *J Mech Behav Biomed Mater*. 2021;123:104760.
  8. Stawarczyk B, Keul C, Eichberger M, Figge D, Edelhoff D, Lmkemann N. Three generations of zirconia: From veneered to monolithic. Part I. *Quintessence Int*. 2017;48:369-80.
  9. Buyukerkmen EB, Bozkurt DA, Terlemez A. Effect of surface treatment, ferrule height, and luting agent type on pull-out bond strength of monolithic zirconia endocrowns. *J Oral Sci*. 2022;64:279-82.
  10. Shin YJ, Shin Y, Yi YA, Kim J, Lee IB, Cho BH, et al. Evaluation of the shear bond strength of resin cement to Y-TZP ceramic after different surface treatments. *Scanning: Scanning Microsc*. 2014;36:479-86.
  11. Heikkinen TT, Matinlinna JP, Vallittu PK, Lassila LV. Dental zirconia adhesion with silicon compounds using some experimental and conventional surface conditioning methods. *Silicon*. 2009;1:199-202.
  12. Han I-H, Kang D-W, Chung C-H, Choe H-C, Son M-K. Effect of various intraoral repair systems on the shear bond strength of composite resin to zirconia. *J Adv Prosthodont*. 2013;5:248-55.
  13. Kidd EA. Microleakage: a review. *J Dent*. 1976;4:199-206.
  14. Gnay A, Eskibağlar M, Cangl S, Karaağaç Eskibağlar B, Adıgzel , Çelenk S. İki Farklı Işık Cihazı ile Polimerize Edilen Bonding Ajanların Mikrosızıntılarının AutoCAD Programı Kullanılarak Değerlendirilmesi. *7tepe Dent J*. 2023;19:173-8.
  15. ISO I. 6872: Dentistry-ceramic materials. Switzerland: International Organization for Standardization. 2008.
  16. Çağlar İ, Ateş SM, Arslan E, Duymuş ZY. Farklı Yntemlerle retilen Metal Alt Yapılara Kompozit Rezin Baėlantisi. *J Dent Fac Ataturk Univ*. 2021;31:414-9.
  17. Gale M, Darvell B. Thermal cycling procedures for laboratory testing of dental restorations. *J Dent*. 1999;27:89-99.
  18. Burrer P, Costermani A, Par M, Attin T, Taubck TT. Effect of varying working distances between sandblasting device and composite substrate surface on the repair bond strength. *Materials*. 2021;14:1621.
  19. Yin H, Kwon S, Chung SH, Kim RJY. Performance of universal adhesives in composite resin repair. *BioMed Res Int*. 2022;2022:7663490.
  20. Wendler M, Belli R, Panzer R, Skibbe D, Petschelt A, Lohbauer U. Repair bond strength of aged resin composite after different surface and bonding treatments. *Materials*. 2016;9:547.
  21. Valandro LF, zcan M, Amaral R, Vanderlei A, Bottino MA. Effect of testing methods on the bond strength of resin to zirconia-alumina ceramic: microtensile versus shear test. *Dent Mater J*. 2008;27:849-55.
  22. Akay C, Çakırbay Tanış M, Şen M. Effects of hot chemical etching and 10-metacryloxydecyl dihydrogen phosphate (MDP) monomer on the bond strength of zirconia ceramics to resin-based cements. *J Prosthodont*. 2017;26:419-23.
  23. Zhang Y, Lawn BR, Malament KA, Thompson VP, Rekow ED. Damage accumulation and fatigue life of particle-abraded ceramics. *Int J Prosthodont*. 2006;19:442-8.
  24. Amaral R, zcan M, Bottino MA, Valandro LF. Microtensile bond strength

- of a resin cement to glass infiltrated zirconia-reinforced ceramic: the effect of surface conditioning. *Dent Mater.* 2006;22:283-90.
25. Altan B, Cinar S, Tuncelli B. Evaluation of shear bond strength of zirconia-based monolithic CAD-CAM materials to resin cement after different surface treatments. *Niger J Clin Pract.* 2019;22:1475-82.
  26. Bona AD, Anusavice KJ. Microstructure, composition, and etching topography of dental ceramics. *Int J Prosthodont.* 2002;15:159-67.
  27. Thompson JY, Stoner BR, Piascik JR, Smith R. Adhesion/cementation to zirconia and other non-silicate ceramics: where are we now? *Dent Mater.* 2011;27:71-82.
  28. Seto KB, McLaren EA, Caputo AA, White SN. Fatigue behavior of the resinous cement to zirconia bond. *J Prosthodont.* 2013;22:523-8.
  29. Aboushelib MN, Kleverlaan CJ, Feilzer AJ. Selective infiltration-etching technique for a strong and durable bond of resin cements to zirconia-based materials. *J Prosthetic Dent.* 2007;98:379-88.
  30. Ural Ç, Külünk T, Külünk Ş, Kurt M. The effect of laser treatment on bonding between zirconia ceramic surface and resin cement. *Acta Odontol Scand.* 2010;68:354-9.
  31. Gul P, Altınok-Uygun L. Repair bond strength of resin composite to three aged CAD/CAM blocks using different repair systems. *Acta Odontol Scand.* 2020;12:131.
  32. Bayraktar Y, Arslan M, Demirtaş Z. Repair bond strength and surface topography of resin-ceramic and ceramic restorative blocks treated by laser and conventional surface treatments. *Microsc Res Tech.* 2021;84:1145-54.
  33. da Rosa LS, Pilecco RO, Soares PM, Rippe MP, Pereira GKR, Valandro LF, et al. Repair protocols for indirect monolithic restorations: a literature review. *PeerJ.* 2024;12:e16942.
  34. Pereira GK, Guilardi LF, Dapieve KS, Kleverlaan CJ, Rippe MP, Valandro LF. Mechanical reliability, fatigue strength and survival analysis of new polycrystalline translucent zirconia ceramics for monolithic restorations. *J Mech Behav Biomed Mater.* 2018;85:57-65.
  35. Hao Z, Ma Y, Liu W, Meng Y, Nakamura K, et al. Influence of low-temperature degradation on the wear characteristics of zirconia against polymer-infiltrated ceramic-network material. *J Prosthet Dent.* 2018;120:596-602.
  36. Hjerpe J, Vallittu PK, Fröberg K, Lassila LV. Effect of sintering time on biaxial strength of zirconium dioxide. *Dent Mater.* 2009;25:166-71.
  37. Khaledi AAR, Vojdani M, Farzin M, Pirouzi S. The effect of sintering program on the compressive strength of zirconia copings. *J Dent.* 2018;19:206-11.
  38. Ersoy NM, Aydogdu HM, Degirmenci BÜ, Çökük N, Sevimay M. The effects of sintering temperature and duration on the flexural strength and grain size of zirconia. *Acta Biomater Odontol Scand.* 2015;1:43-50.
  39. Mohaghegh M, Baseri S, Kalantari MH, Giti R, Ghoraishian SA. Influence of Sintering Temperature on the Marginal Fit and Compressive Strength of Monolithic Zirconia Crowns. *J Dent.* 2022;23:307-13.
  40. Kontonasaki E, Giasimakopoulos P, Rigos AE. Strength and aging resistance of monolithic zirconia: an update to current knowledge. *Jpn Dent Sci Rev.* 2020;56:1-23.
  41. D'Amario M, Campidoglio M, Morresi AL, Luciani L, Marchetti E, Baldi M. Effect of thermocycling on the bond strength between dual-cured resin cements and zirconium-oxide ceramics. *J Oral Sci.* 2010;52:425-30.
  42. Blatz MB, Bergler M, Ozer F, Holst S, Phark J-H, Chiche GJ. Bond strength of different veneering ceramics to zirconia and their susceptibility to thermocycling. *Am J Dent.* 2010;23:213-6.



43. Bahari M, Mohammadi N, Alizadeh Oskoe P, Savadi Oskoe S, Davoodi F. Effect of an extra layer of hydrophobic resin on the microleakage of C1 V composite resin restorations with a universal adhesive system. *J Investig Clin Dent*. 2017;8:e12234.
44. Wahab F, Abu-Tabra IT, Amin WM. An in vitro study of micro leakage of different types of composites with respect to their matrix compositions. *JAMMR*. 2014;4:1908-22.
45. Bolgöl B, Ayna B, Şimşek İ, Celenk S, Şeker O, Kılınç G. Leakage testing for different adhesive systems and composites to permanent teeth. *Niger J Clin Pract*. 2017;20:787-91.

## A Contemporary Approach: Presentation of 4 Cases with the Entire Papilla Preservation (EPP) Technique

Şükran ACIPINAR<sup>1\*</sup>  Taha Yasin ERDOĞAN<sup>2</sup> 

<sup>1</sup> Ass. Prof., Department of Periodontology, Faculty of Dentistry, Sivas Cumhuriyet University, Sivas, Türkiye, [sukranacipinar@cumhuriyet.edu.tr](mailto:sukranacipinar@cumhuriyet.edu.tr)

<sup>2</sup> Res. Ass., Department of Periodontology, Faculty of Dentistry, Sivas Cumhuriyet University, Sivas, Türkiye, [tyasinerdogan93@gmail.com](mailto:tyasinerdogan93@gmail.com)

### Article Info

#### Article History

Received: 27.06.2024

Accepted: 05.09.2024

Published: 15.10.2024

#### Keywords:

Alveolar bone loss,  
Guided tissue regeneration,  
Interdental papilla.

### ABSTRACT

Regeneration of periodontal tissue is a primary goal of periodontal treatment. Periodontal regeneration approaches are widely used in the treatment of intraosseous defects. However, the success of these techniques depends on many factors, including surgical considerations. Failures in wound closure in the interdental region, which are surgical factors, have led to the development of papilla preservation techniques. The entire papilla preservation technique (EPP) maintains the integrity of the papilla associated with the defect. This technique stabilizes the blood clot with intact gingiva, preventing wound exposure and contamination.

EPP is performed in intra-osseous defects through a short buccal vertical incision, without incising the papilla of the involved tooth. A full-thickness buccal flap is lifted from the incision to the relevant papilla and a tunnel extending under the papilla is prepared. The papilla is also lifted to full thickness. The defect is cleaned of granulation tissue and the wound is closed primarily with or without biomaterial application. In this report, we present 4 cases, 3 in the anterior maxilla and 1 in the mandibular premolar region, undergoing periodontal surgery with EPP with biomaterial application with a 3-month follow-up. In all cases, soft tissue healing was uncomplicated and radiographs showed bone filling at 3 months.

EPP has a high success rate in periodontal regeneration by providing complete nutrition of the interdental papilla through natural, continuous vascular support in intraosseous defects.

## Güncel Bir Yaklaşım Olarak Papillanın Tamamının Korunması Tekniği İle 4 Olgu Sunumu

### Makale Bilgisi

#### Makale Geçmişi

Geliş Tarihi: 27.06.2024

Kabul Tarihi: 05.09.2024

Yayın Tarihi: 15.10.2024

#### Anahtar Kelimeler:

Alveolar kemik kaybı,  
Yönlendirilmiş doku  
rejenerasyonu,  
İnterdental papilla.

### ÖZET

Periodontal dokunun rejenerasyonu periodontal tedavinin temel hedeflerinden biridir. Kemik içi defektlerin tedavisinde periodontal rejenerasyon teknikleri yaygın olarak kullanılmaktadır. Ancak teknikler yüksek hassasiyet gerektirir ve başarı birçok faktöre bağlıdır. Hastaya ve defektlere bağlı faktörlerin yanında cerrahiye bağlı faktörler de sonuçlar üzerinde önemli bir etkiye sahiptir. Cerrahi faktörler arasında interdental bölgede primer yara kapanmasındaki başarısızlıklar papilla koruma tekniklerinin gelişimine neden olmuştur. Papillanın tamamının korunması tekniği (PTK), defektle ilişkili papillanın bütünlüğünü korumak için önerilmiştir. Bu teknik, kan pıhtısını stabilize etmek için sağlam bir diş eti sağlamakta, bölgeyi kontaminasyondan korumakta ve yara ekspozunu önlemektedir.

PTK, kemik içi defektlerde, ilgili dişin papilla insizyonu olmadan, mukogingival hattının hemen ötesine uzanan kısa bir bukkal vertikal serbestleştirici insizyonla uygulanır. İnsizyondan ilgili papillaya kadar tam kalınlıkta bukkal flep kaldırılır ve papillanın altına uzanan tünel hazırlanır. Papilla da tam kalınlıkta olacak şekilde kaldırılır. Kemik içi defekt granülasyon dokularından temizlenir ve biyomateryal uygulanarak veya uygulanmaksızın yara primer olarak kapatılır. Bu raporda, 3'ü maksilla anterior bölgede, 1'i mandibular premolar bölgede olmak üzere, biyomateryal uygulanarak PTK ile periodontal cerrahi gerçekleştirilen 4 adet olgu ve 3 aylık takipleri sunulmaktadır. Olguların tümünde klinik olarak yumuşak doku yara iyileşmesi komplikasyonsuzdur. Hastaların takip radyografilerinde 3 aylık dönemde kemik dolumları izlenmektedir. PTK, kemik içi defektlerde interdental papillanın, doğal kesintisiz damar desteğiyle tamamen beslenmesini sağlayarak, periodontal rejenerasyonda yüksek başarı oranına sahiptir.

**To cite this article:** Acipinar Ş, Erdoğan TY. A Contemporary Approach: Presentation of 4 Cases with the Entire Papilla Preservation (EPP) Technique. NEU Dent J. 2024;6(Special Issue):108-15. <https://doi.org/10.51122/neudentj.2024.121>

\*Corresponding Author: Şükran ACIPINAR, [sukranacipinar@cumhuriyet.edu.tr](mailto:sukranacipinar@cumhuriyet.edu.tr)



## INTRODUCTION

Regeneration of periodontal tissue is one of the primary goals of periodontal treatment. Numerous surgical techniques and biomaterials have been employed for periodontal tissue regeneration.<sup>1,2</sup> However, these techniques require meticulous study, and the outcomes of regenerative therapy are influenced by various factors, including the specific case, the nature of the defect and the surgical procedure itself.<sup>3,4</sup> Surgical factors, such as the impact of the interdental papilla incision on wound healing, play a significant role. Impaired wound healing due to the incision of the interdental papilla can result in inadequate protection of the area from the intraoral environment and exposure to biomaterials. This exposure is a common complication that can lead to contamination of the surgical field, adversely affecting the outcome.<sup>5</sup>

To overcome these shortcomings, alternative approaches have been proposed, including minimally invasive flap design, microsurgery, and the use of Emdogain, which alter both surgical methodology and the application of materials.<sup>5</sup> The objective of these approaches is to create an optimal environment for the wound to heal smoothly and stably, thereby facilitating primary closure.

Surgical approaches, such as the papilla preservation technique,<sup>6</sup> have demonstrably increased the clinical success rate in periodontal surgery. However, these techniques involve the incision of interdental papillae, even in limited areas, and the suturing of the papilla has been shown to have a local adverse effect on blood circulation, causing papillary atrophy.<sup>7</sup>

In 2017, a new surgical approach, the 'entire papilla preservation (EPP) technique', was proposed for the regenerative periodontal treatment of isolated deep intraosseous defects.<sup>8</sup> EPP represents a contemporary, conservative

surgical approach that provides adequate access to isolated interproximal intraosseous defects for debridement, while preserving the vascular and anatomical integrity of the interdental papilla associated with the defect. This preservation allows for the creation of an intact gingival environment over the intraosseous defect, facilitating the preservation of the delicate biological regeneration process and stabilizing the clot.

The EPP technique involves making a single releasing vertical incision on the buccal side, contralateral to the defect. This incision crosses the mucogingival junction by 1-2 mm, ensuring the preservation of the integrity of the papilla in a tunnel-like manner. The incision line is situated in a safe area of the natural bone, distant from the bone defect. A full-thickness flap extending from the incision to the defect is elevated, and a tunnel is prepared under the papilla.

The granulation tissues are removed and irrigated with a sterile saline solution. The area is then sutured, either with or without the application of a biomaterial. The healing potential of a properly sutured incision is considerable, and uncomplicated wound healing at the incision line has been widely reported.<sup>5</sup> The absence of an incision in the papilla provides an intact gingival environment to stabilize the blood clot, and promote healing, eliminating the need for any sutures in the papilla. This technique ensures that the papilla is fully nourished with a natural, uninterrupted vascular supply, thereby preventing exposure of the wound or biomaterial.

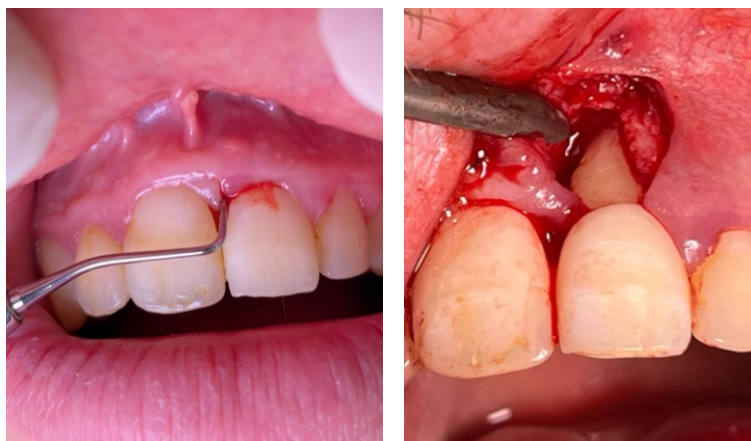
In light of the aforementioned information, this report presents four cases of periodontal surgery with EPP, three in the anterior maxilla and one in the mandibular premolar region, along with their 3-month follow-ups.

## CASE REPORTS

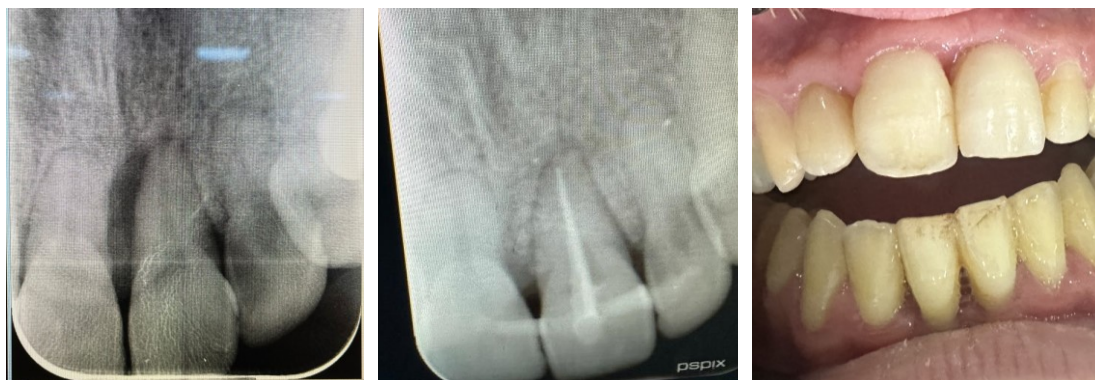### Case 1

A 23-year-old male patient presented to our clinic for the removal of calculus. The patient's medical history indicated that he had previously undergone orthodontic treatment. A clinical examination revealed the presence of an 11 mm periodontal pocket depth on the mesial aspect of tooth number 21. A radiographic and clinical evaluation revealed that tooth number 21 exhibited an intra-osseous periodontal defect. Phase 1 periodontal treatment was initiated. At the follow-up visit six weeks later, it was determined that the pocket depth of the relevant tooth had regressed to 9 mm and bleeding on probing and suppuration findings continued. The patient was therefore taken to phase 2 periodontal treatment with the application of EPP. During the surgical

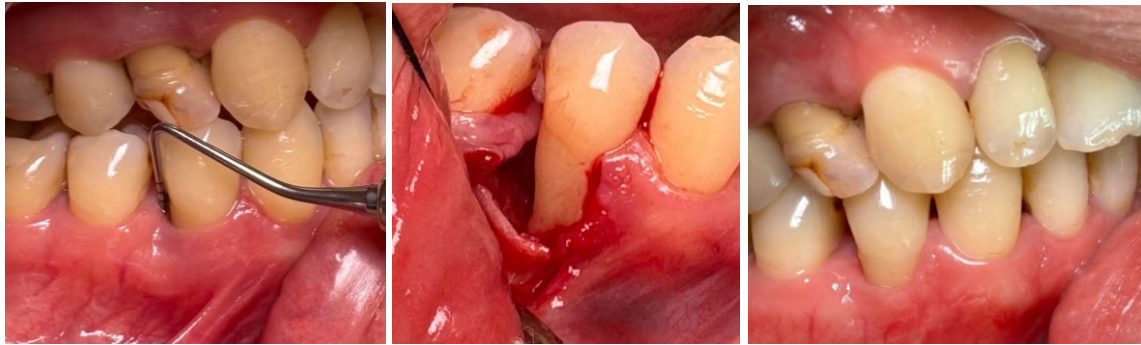procedure, the area of the intra-bony defect was accessed through a vertical incision on the adjacent lateral aspect of the papilla (Figure 1). The granulation tissues were then cleaned and irrigation with a sterile saline solution. A synthetic bone graft material was placed in the defect, and the defect was covered with platelet-rich fibrin (PRF) obtained from the patient's venous blood at 2800 rpm for 12 minutes. The flap was then sutured with a 6.0 polypropylene suture. The patient was prescribed postoperative antibiotics, analgesics, and a mouthwash. Two weeks later, the sutures were removed, and the patient did not report any complaints regarding his postoperative condition. At the 90-day follow-up, a clinical evaluation revealed the absence of bleeding on probing and suppuration, and a radiographic examination confirmed the presence of bone filling in the intraosseous defect (Figure 2).



**Figure 1:** Preoperative probing depth at the distal side of the maxillary left central incisor (left), the entire papilla preservation (EPP) technique (right).



**Figure 2:** Baseline (left) and 3 month periapical radiograph (mid) and 3 month follow-up intraoral appearance (right).

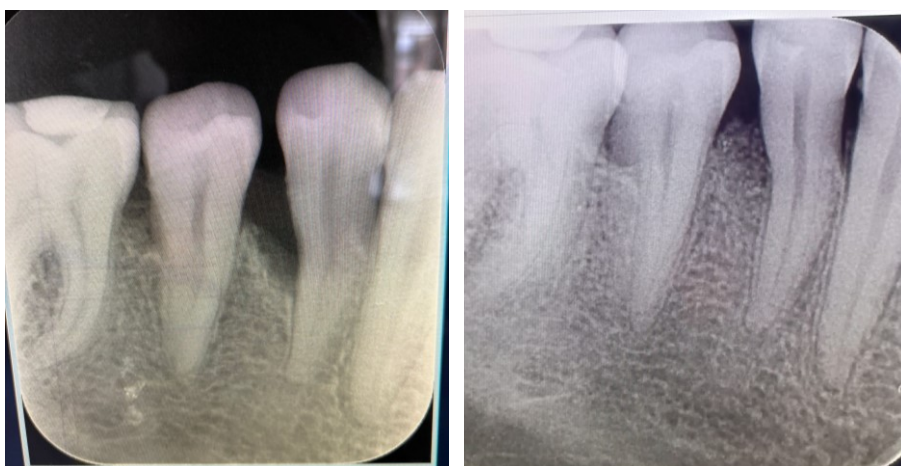

**Figure 3:** Ten mm preoperative probing depth at the distal side of the mandibular right premolar(left), intraoperative appearance(mid) and intraoral appearance at 3 months (right).

### Case 2

A 41-year-old male patient presented to our clinic for the removal calculus. A review of the patient's medical history revealed no evidence of systemic disease. A clinical evaluation revealed the presence of a periodontal pocket, measuring 10 mm in depth, distal to tooth number 44 (Figure 3). A radiographic and clinical evaluation revealed that tooth number 44 exhibited an intraosseous periodontal defect. The patient was subjected to phase 1 periodontal treatment, and subsequent re-evaluation demonstrated a reduction in pocket depth by 1 mm, resulting in a total depth of 9 mm. At this stage, the patient underwent phase 2 periodontal treatment, which included EPP. During the surgical procedure, the

intraosseous defect was cleaned of granulation tissues and irrigated with a sterile saline solution. A demineralized freeze-dried bone allograft was then placed into the defect. The flap was then sutured with a 5.0 silk suture. Following the procedure, the patient was prescribed antibiotics, analgesics, and mouthwash. Two weeks later, the sutures were removed, and the patient did not report any complaints regarding his postoperative condition. At the 90-day follow-up, there was an improvement in the clinical periodontal parameters, with no evidence of bleeding or suppuration on probing. Furthermore, the radiographic examination confirmed the presence of bone filling in the intraosseous defect (Figure 4).



**Figure 4:** Baseline radiograph (left) and 3. month periapical radiograph shows bone filling (right).

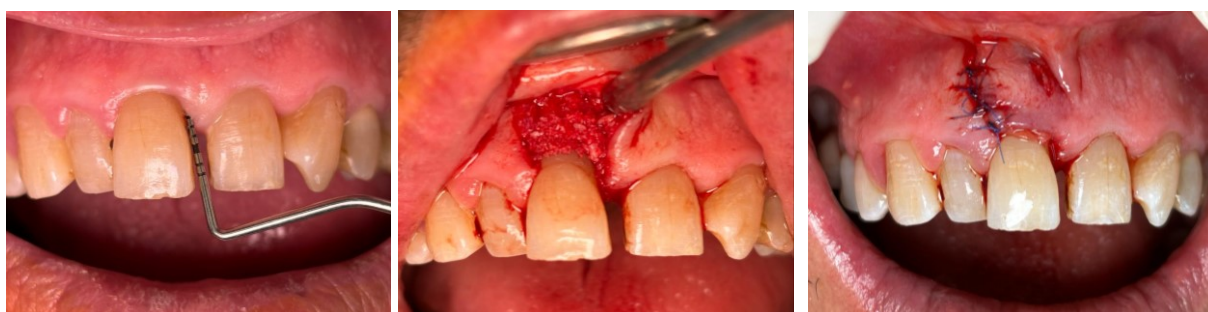### Case 3

A 61-year-old male patient presented to

our clinic for the removal of calculus. In the anamnesis, it was established that the patient did not have any systemic disease. A clinical

evaluation revealed the presence of a 7 mm periodontal pocket depth in the mesial aspect of tooth number 11 in the buccal tipping position. A radiographic and clinical evaluation revealed the presence of an intraosseous periodontal defect in tooth number 11. Phase 1 periodontal treatment was initiated. Following a six-week healing period, EPP was applied to the relevant tooth as part of Phase 2 periodontal treatment, given that there was no reduction in pocket depth. During the surgical procedure, the intraosseous defect was cleaned of granulation tissues and irrigated with a sterile saline solution. A demineralized freeze-dried bone

allograft was placed into the defect. The defect was subsequently covered with platelet-rich fibrin (PRF). The flap was then sutured with a 6.0 polypropylene suture. (Figure 5). Following the procedure, the patient was prescribed antibiotics, analgesics, and mouthwash. On the 14th day, the sutures were removed, and the patient did not report any postoperative complaints. At the 90-day follow-up, improvements in clinical periodontal parameters such as bleeding on probing were observed, and a radiographic examination confirmed bone fill in the intraosseous defect. (Figure 6)

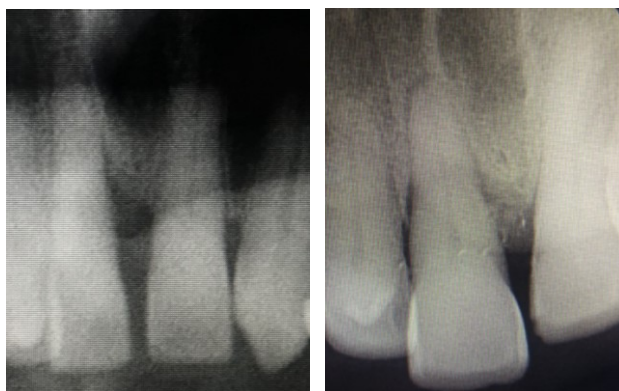

**Figure 5:** Measurement of pocket depth of tooth number 11 before EPP (left), appearance with graft placed during surgery (mid) and intraoral appearance at 2 weeks after surgery (right).

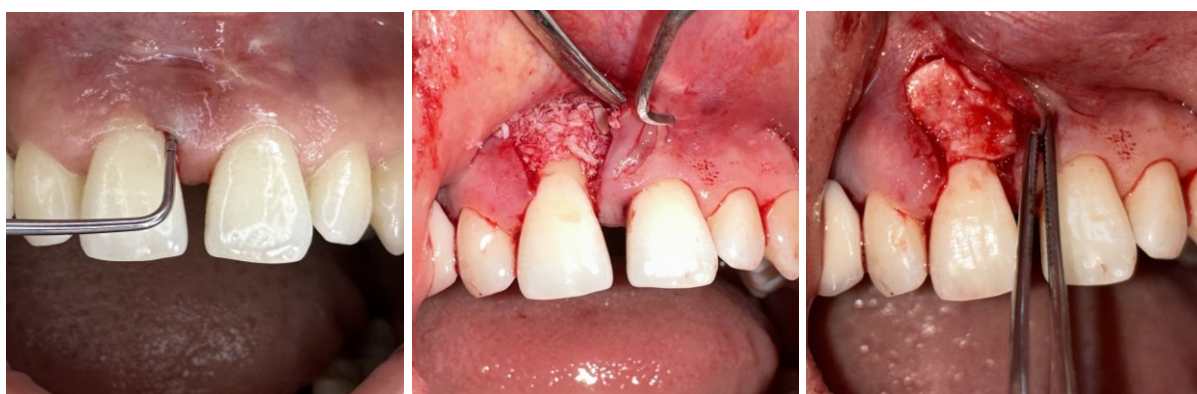#### **Case 4**

A 32-year-old female patient presented to our clinic with a complaint of pain in her anterior teeth. A review of the patient's medical history revealed no evidence of underlying systemic disease. A periodontal pocket depth of 10 mm was observed in the mesial aspect of tooth number 11 during the clinical examination. A radiographic and clinical evaluation revealed that tooth number 11 had an intra-osseous periodontal defect. The patient was subjected to phase 1 periodontal treatment. Following the healing period, it was established that the pocket depth had decreased to 8 mm, the presence of suppuration was detected and EPP was subsequently applied to the relevant tooth within the context of phase 2 periodontal treatment. During the surgical procedure, the

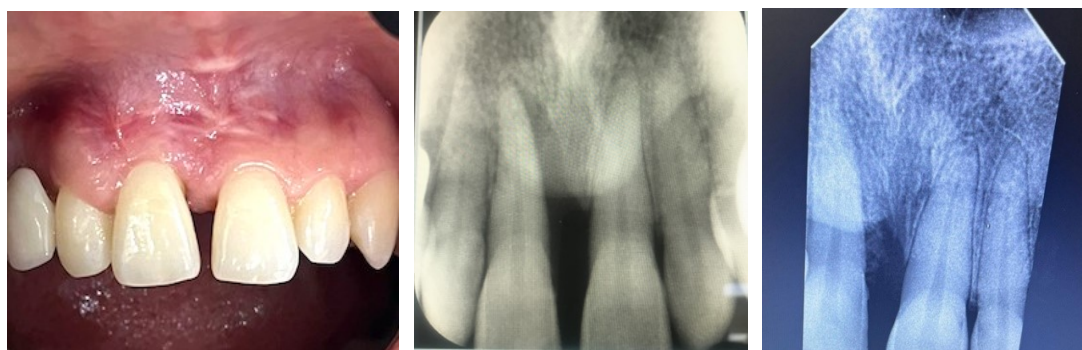
intraosseous defect was cleaned of granulation tissues and irrigated with a sterile saline solution. A demineralized freeze-dried bone allograft was then placed into the defect. The defect was subsequently covered with a collagen membrane and PRF, which was obtained from the patient's venous blood. The flap was then sutured with a 6.0 polypropylene suture. (Figure 7) Following the procedure, the patient was prescribed antibiotics, analgesics and a mouthwash. On the 10th day, the sutures were removed, and the patient did not report any postoperative complaints. At the three-month follow-up, clinical evaluation demonstrated that the incision line healed uneventfully, there was no bleeding or suppuration on probing, and a radiographic examination revealed that the defect had been filled with bone (Figure 8).



**Figure 6:** Baseline radiograph (left) and 3. month periapical radiograph shows bone filling (right).



**Figure 7:** Baseline intraoral appearance (left), graft (mid) and membrane application(right) in right maxillary central incisor treated with the entire papilla preservation technique.



**Figure 8:** Intraoral appearance at 3 months (left), baseline radiograph (mid) and 3. month periapical radiograph shows bone filling (right).

## DISCUSSION

The success of periodontal regeneration techniques depends on a number of factors, with each step, including incision design, flap shape, debridement methods, material positioning, flap repositioning and suturing-playing a role in the final outcome.<sup>9</sup> The primary closure of the interdental space serves to protect the wound site from the intraoral environment and reduce microbial infection. In conventional periodontal

flap surgery, an incision is employed to separate the interdental papilla.<sup>10</sup> This incision allows full access to the defect but increases the risk of flap separation and biomaterial exposure, which are the main short-term postoperative complications during the early soft tissue healing phase. These complications can lead to bacterial contamination and, consequently, periodontal regeneration failure.<sup>9</sup>

Several techniques have been proposed to

reduce the risk of complications during the early stages of wound healing.<sup>5</sup> These approaches involve the preservation of the interdental papilla through minimally invasive surgical techniques. However, despite these techniques, an incision is still required to access the papilla, which may lead to papillary atrophy.<sup>7</sup> To achieve more optimal results, the EPP technique has been proposed, which preserves the integrity of the entire papilla associated with the defect through a tunnel-like incision.<sup>8</sup> This technique allows for the performance of regenerative treatment with a vertical incision away from the bone defect, thereby avoiding an incision in the interdental papilla, reducing the risk of papillary rupture. The EPP technique ensures the maintenance of an intact gingival chamber, thereby enabling clinical outcomes comparable to those achieved through conventional treatment, while reducing the incidence of aesthetic complications. The EPP technique does not involve the dissection of supra crestal fibers in the interdental tissues, thus maintaining the papilla in its coronal position. This technique helps to preserve the underlying cavity and stabilize the blood clot and interproximal soft tissues.<sup>5</sup>

In EPP, the defect can only be accessed from the buccal side, which may limit its clinical applicability. Extensive involvement of the palatal and lingual sides of the tooth renders this approach unsuitable, as access to the palatal part of the defect is severely limited. The primary indication for EPP is a two-walled intraosseous defect with a missing buccal bone wall and a relatively well-preserved lingual wall.<sup>5</sup> All cases in the case series exhibited a deficient buccal wall. This case selection is consistent with another study in which EPP was performed in two-walled defects, with the majority of defects in both groups being essentially non-supportive. The successful results support the hypothesis that EPP improves soft tissue and wound stability in this study.<sup>5</sup>

In the case series, graft material was employed in all cases, with the addition of PRF in two cases and PRF and a collagen membrane in one case. The selection of biomaterial did not result in any discernible clinical differences in the healing process. These results are consistent with the results of a study in which bone grafts and soft tissue grafts such as CTG were applied, and non-absorbable membranes were not required.<sup>9</sup>

In the case series of the present study, all incisions healed uneventfully. Minimal gingival recession was observed in the buccal region, with no loss of interdental papilla. The average gingival recession in all cases was 0.62 mm (min:0.2 mm max:1.2 mm). These results are in accordance with the findings of a 12-case study which reported that the early healing process was uneventful in all cases and that 100% primary wound closure was achieved within one year.<sup>11</sup> Furthermore, the study demonstrated that EPP led to significant results with a negligible increase in gingival recession. The minimal increase in gingival recession was associated with a decrease in probing depth, suggesting that gingival recession may be explained by the shrinkage of marginal soft tissues during secondary wound healing.

## **CONCLUSION**

The 'EPP' technique, characterized by a tunnel-like configuration, can prevent the exposure of regenerative biomaterials, enhance the stabilization of the blood clot in deep intraosseous defects, and facilitate the achievement of optimal clinical outcomes.

### **Ethical Approval**

This in-vitro study does not require ethics committee approval.

### **Financial Support**

The authors declare that this study received no financial support.



### **Conflict of Interest**

The authors deny any conflicts of interest related to this study.

### **Author Contributions**

Design: ŞA, TYE, Data collection or data entry: ŞA, TYE, Analysis and interpretation: ŞA, Literature review: ŞA, Writing: ŞA.

### **REFERENCES**

1. Nyman S, Lindhe J, Karring T, Rylander H. New attachment following surgical treatment of human periodontal disease. *J Clin Periodontol.* 1982;9:290–6.
2. Camelo M, Nevins ML, Lynch SE, Schenk RK, Simion M, Nevins M. Periodontal regeneration with an autogenous bone-Bio-Oss composite graft and a Bio-Gide membrane. *Int J Periodontics Restorative Dent.* 2001;21:109-19.
3. Kornman KS, Robertson PB. Fundamental principles affecting the outcomes of therapy for osseous lesions. *Periodontol 2000.* 2000;22:22-43.
4. Farina R, Simonelli A, Rizzi A, Pramstraller M, Cucchi A, Trombelli L. Early postoperative healing following buccal single flap approach to access intraosseous periodontal defects. *Clin Oral Investig.* 2013;17:1573-83.
5. Aslan S, Buduneli N, Cortellini P. Clinical outcomes of the entire papilla preservation technique with and without biomaterials in the treatment of isolated intrabony defects: A randomized controlled clinical trial. *J Clin Periodontol.* 2020;47:470-8.
6. Takei HH, Han TJ, Carranza FA, Kenney EB, Lekovic V. Flap technique for periodontal bone implants. Papilla preservation technique. *J Periodontol.* 1985;56:204-10.
7. Ogawa Y, Yoshikawa K, Ishikawa T, Saito A, Imamura K. Double-sided entire papilla preservation technique in the combination periodontal regenerative therapy: A case report. *Clin Adv Periodontics.* 2023;10.1002.
8. Aslan S, Buduneli N, Cortellini P. Entire papilla preservation technique: a novel surgical approach for regenerative treatment of deep and wide intrabony defects. *Int J Periodontics Restorative Dent.* 2017;37:227-33.
9. Pei X. New surgery approaches preserving entire papilla to treat isolated interdental intrabony defects: A narrative review. *Clin Exp Dent Res.* 2021;7:719-25.
10. Cortellini P, Tonetti MS. Clinical concepts for regenerative therapy in intrabony defects. *Periodontol 2000.* 2015;68:282-307.
11. Aslan S, Buduneli N, Cortellini P. Entire papilla preservation technique in the regenerative treatment of deep intrabony defects: 1-Year results. *J Clin Periodontol.* 2017;44:926-32.

## Total Pulpotomy with MTA in Young Permanent Teeth: Case Series

Menekşe ALİM<sup>1\*</sup>  Mehmet BANI<sup>2</sup> 

<sup>1</sup> Res. Assist., Gazi University, School of Dentistry, Department of Pediatric Dentistry, Ankara, Türkiye, dt.alimmenekse@gmail.com

<sup>2</sup> Prof., Gazi University, School of Dentistry, Department of Pediatric Dentistry, Ankara, Türkiye, mehmetbani@gazi.edu.tr

Article Info	ABSTRACT
<b>Article History</b> <b>Received:</b> 27.06.2024 <b>Accepted:</b> 05.09.2024 <b>Published:</b> 15.10.2024 <b>Keywords:</b> Pulpotomy, Vital pulp therapy, Young permanent teeth.	Vital pulp therapy is a way to preserve the vitality and function of pulp damaged by trauma, caries or restorative procedures. Vital pulp therapy procedures include direct pulp capping, indirect pulp capping, partial and coronal pulpotomy treatments where diseased pulp tissue is removed. Over the years, the focus of vital pulp therapy has been on the preservation of the radicular pulp in immature permanent teeth to ensure the completion of root formation (apexogenesis). Today, it has been reported that vital pulp therapy can be considered as an alternative to root canal treatment, including in teeth with certain conditions that are considered to have irreversibly inflamed pulp. Coronal amputation therapy, a vital pulp treatment, involves complete removal of the coronal pulp, placement of a biologically acceptable material into the pulp chamber and restoration. The covering material must be able to relieve inflammation and initiate healing of the pulp tissue and allow new dentin tissue to form. The oldest material used in pulpotomy is calcium hydroxide. Mineral trioxide aggregate, which is a more recent material, is frequently preferred today due to its biocompatible and bioactive properties. In this case report, the results of 4 cases of coronal pulpotomy with mineral trioxide aggregate in young permanent teeth with a follow-up of 18 months are presented.

### Genç Daimi Dişlerde MTA ile Koronal Pulpotomi: Vaka Serisi

Makale Bilgisi	ÖZET
<b>Makale Geçmişi</b> <b>Geliş Tarihi:</b> 27.06.2024 <b>Kabul Tarihi:</b> 05.09.2024 <b>Yayın Tarihi:</b> 15.10.2024 <b>Anahtar Kelimeler:</b> Pulpotomi, Vital pulpa tedavisi, Genç daimi diş.	Vital pulpa tedavisi travma, çürük veya restoratif prosedürler sebebiyle hasar alan pulpanın canlılığını ve işlevini korumanın bir yoludur. Vital pulpa tedavisi prosedürleri; direkt kuafaj, indirekt kuafaj, hastalıklı pulpa dokusunun çıkarıldığı parsiyel ve koronal pulpotomi tedavilerini içermektedir. Yıllar boyunca vital pulpa tedavisinin odak noktası, kök oluşumunun (apeksogenez) tamamlanmasını sağlamak için gelişimini tamamlamamış daimi dişlerde radiküler pulpanın korunması olmuştur. Günümüzde ise vital pulpa tedavisinin, belirli şartlara sahip geri dönüşümsüz olarak inflame pulpaya sahip olduğu düşünülen dişler de dahil olmak üzere, kök kanal tedavisine alternatif olarak değerlendirilebileceği bildirilmiştir. Vital pulpa tedavilerinden olan koronal amputasyon tedavisi koronal pulpanın tamamen çıkarılması, biyolojik olarak kabul edilebilir bir materyalin pulpa odasına yerleştirilmesi ve restorasyonunu içerir. Kaplama materyali ise, pulpa dokusundaki inflamasyonu giderip iyileşmeyi başlatabilmeli ve yeni dentin dokusunun oluşabilmesini sağlamalıdır. Pulpotomide kullanılan en eski materyal kalsiyum hidroksittir. Daha güncel bir materyal olan mineral trioksit agregatı ise biyoyumlu ve biyoaktif özellikleri nedeniyle günümüzde sıklıkla tercih edilmektedir. Bu olgu raporunda genç daimi dişlerde mineral trioksit agregatı ile koronal pulpotomi uygulanan 4 olgunun 18 ay takipli tedavi sonuçları sunulmuştur.

**To cite this article:** Alim M, Bani, M. Total Pulpotomy with MTA in Young Permanent Teeth: Case Series. NEU Dent J. 2024;6(Special Issue):116-24. <https://doi.org/10.51122/neudentj.2024.122>

**\*Corresponding Author:** Menekşe ALİM, [dt.alimmenekse@gmail.com](mailto:dt.alimmenekse@gmail.com)



## INTRODUCTION

Vital pulp therapy (VPT) consists of different treatment strategies to preserve the integrity, health and pulp vitality of teeth with deep carious lesions approaching or involving the pulp, or when pulp tissue is exposed due to mechanical causes such as trauma. VPT procedures include direct and indirect pulp capping, partial and coronal pulpotomies to remove diseased pulp tissue.<sup>1</sup>

According to common understanding, pulpotomies were limited to treating decayed deciduous teeth and traumatized permanent teeth, while root canal treatment (RCT) of caries-perforated pulp in mature permanent teeth was recommended. It has now been suggested that pulpotomy treatment may be a treatment option, even in cases of irreversible pulpitis (IP).<sup>2</sup> The goals of coronal pulpotomy treatment are to preserve pulp vitality, promote repair of remaining pulp tissue, and restore structural and functional health of the pulp dentin complex.<sup>3</sup> Traditionally, the determination of pulpal diagnosis has been based on the clinician's assessment of the patient's pain history and clinical tests such as vitality and percussion testing.<sup>4,5</sup> Historically, however, clinical test results have not accurately reflected the histological state of the pulp.<sup>6,7</sup> Histologic proof of pulpitis advancement suggests that there is no limit to which the pulp becomes irreparable.<sup>8,9</sup> Instead, pulpitis is interpreted as a graded disease, with some investigators proposing the terms "initial," "mild," "moderate," and "severe pulpitis" for grading.<sup>8,10</sup> Clinically, scrutiny of pulp tissue during and after hemostasis additional diagnostic data about the status of the pulp.<sup>11</sup> Thus, it seems that even symptomatic pulps can be treated with VPT.<sup>12</sup>

Influencing factors in the achievement of pulpotomy treatments include correct diagnosis, clinical findings, appropriate treatment method, bleeding control, use of biocompatible material,

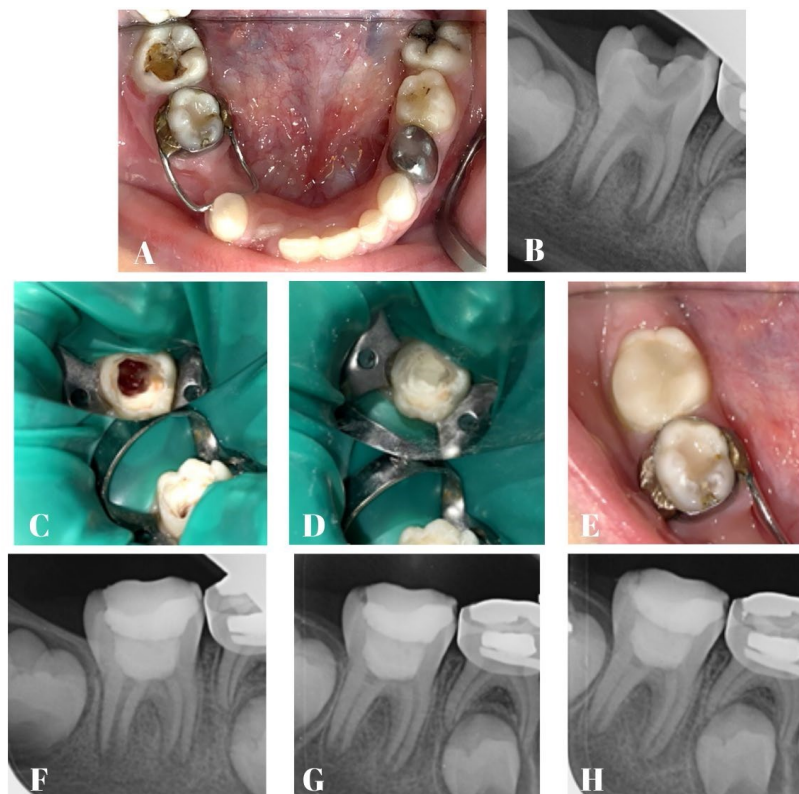
blood supply, healthy periodontal tissues, crown sealing and appropriate crown material, degree of microbial contamination and repair ability of dental tissue.<sup>13</sup> When these factors are considered, coronal pulpotomy treatments have been reported as a simple, biological, regenerative, conservative and economical method with a high achievement rate.<sup>1</sup> The oldest material used in pulpotomy is calcium hydroxide. Mineral trioxide aggregate (MTA), a more recent material, is frequently preferred today due to its biocompatible and bioactive properties.<sup>14,15</sup> Clinical investigations of cariously exposed permanent molars diagnosed with reversible pulpitis and treated with MTA have shown high success rates ranging from 82% to 100%.<sup>16-19</sup> Although few studies have investigated the use of MTA for pulpotomies of permanent molars with clinical signs and symptoms indicative of irreversibly inflamed pulp, success rates have been quite high.<sup>20-22</sup> It has been reporting that to evaluate the success of pulpotomy treatments, treated teeth should be followed up at 6 and 12 months postoperatively and then annually for four years if necessary.<sup>23</sup> The advantages of coronal pulpotomy treatment, which can be considered as an alternative to RCT, are preservation of the structural integrity of the tooth, less painful procedure, elimination of complications related to difficult root canal anatomy, and reduced cost and time spent in the clinic.<sup>10</sup> The aim of this study was to evaluate the results of coronal pulpotomy treatment with MTA in young permanent teeth diagnosed with reversible/irreversible pulpitis.

### Case 1

An 8-year-old girl patient was applied to the Pediatric Dentistry Clinic of Gazi University with pain in the lower right region. The pain started spontaneously and was persistent. Clinical examination revealed percussion sensitivity in tooth 46, which had deep dentin caries (Figure 1A). No pathologic changes were observed in the intraoral soft

tissues. Radiographic examination revealed radiolucency and loss of lamina dura in the apical and bifurcation region (Figure 1B). It was also observed that root development was incomplete and the root tips were open. A positive response was obtained to the vitality test. After clinical and radiologic examination, irreversible pulpitis was diagnosed. After removal of the coronal pulp, coronal pulpotomy/apexification preferences were planned according to the bleeding control status. Local anesthesia was applied, the caries were removed under rubber-dam isolation, and the coronal pulp tissue was removed with an aerator under water cooling. Hemostasis was achieved in 5 minutes with a cotton pellet moistened with 2.5% sodium hypochlorite (NaOCl) and the treatment was continued as a coronal pulpotomy (Figure 1C). MTA (Bio-MTA-Cerkamed) used as pulp coating material. MTA powder and liquid were mixed according to the manufacturer's instructions for 30 s until the compound reaches a consistence of soft

plasticine. A 2-3 mm MTA as placed on the pulp chamber floor (Figure 1D). After the initial hardening time of 4 minutes of MTA was completed, conventional glass ionomer cement (Nova Glass-F-Imicryl) was placed in the cavity as a base. After etching the tooth surface using phosphoric acid gel for 20 seconds, the teeth were washed with air water spray and a thin layer of universal adhesive was applied to the prepared tooth surface and cured with led light. Composite resin (Charisma-Heraus Kulzer) was applied to the tooth by layering technique and each layer was cured with led light for 20 seconds (Figure 1E). The patient was followed up for clinical and radiographic evaluation at 6, 12 and 18 months (Figure 1F, 1G, 1H). It was found that the patient's complaints were completely resolved and there was no pain on percussion. At the end of the 18th month, the disappearance of radiolucent appearance, root elongation, increase in dentin thickness and closure of the apex were observed.

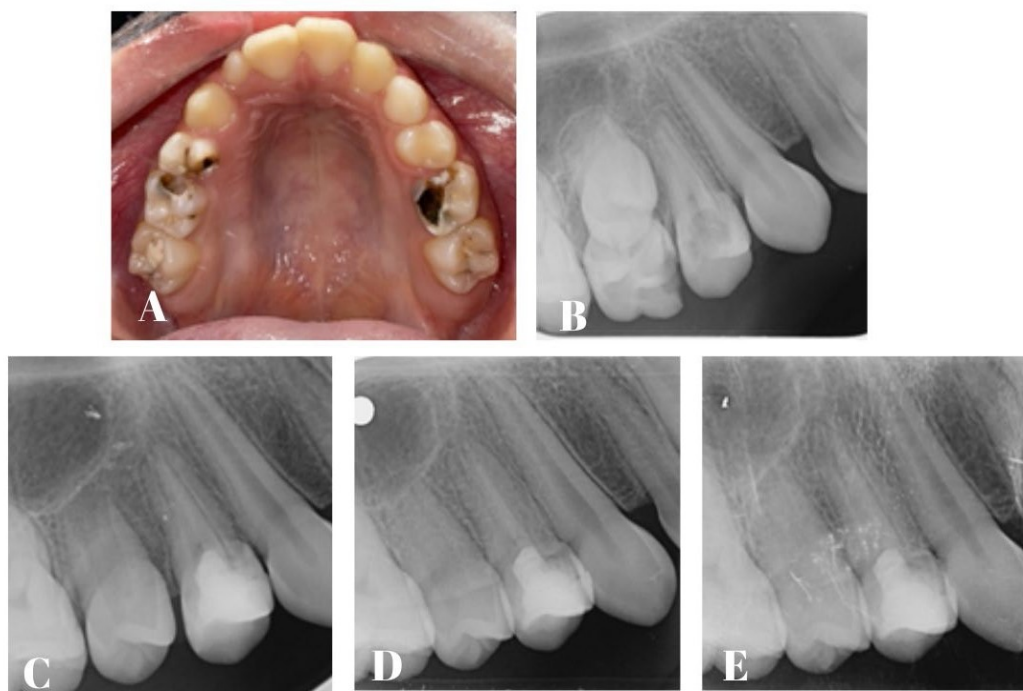


**Figure 1.** A: Preoperative photograph showing tooth 46 with deep dentin caries, B: Preoperative radiograph of tooth 46, C: Total pulpotomy performed in tooth 46, D: MTA placed over the pulp, E: Postoperative photograph, F-G-H: 6,12 and 18 months follow-up.

### Case 2

An 11-year-old girl patient presented to our clinic with pain in the right upper region. The patient stated that the pain started after eating and did not continue after the stimulus was removed. Intraoral examination showed deep dentin caries in tooth 14 (Figure 2A). No pain was detected on percussion and palpation. The radiographic examination did not reveal any negative findings in tooth number 14, which had not yet completed root development (Figure 2B). As a consequence of clinical and radiographic examination, reversible pulpitis

was diagnosed in tooth number 14. After the caries were removed under local anesthesia and rubber-dam isolation, it was decided to perform a coronal pulpotomy because the pulp was exposed to caries at multiple points. The procedure described in the other case was performed respectively. The patient was followed up for clinical and radiographic evaluation at 6, 12 and 18 months (Figure 2C, 2D, 2E). The tooth was asymptomatic and at the end of the 18th month, root elongation, increased dentin thickness and closure of the apex were observed.

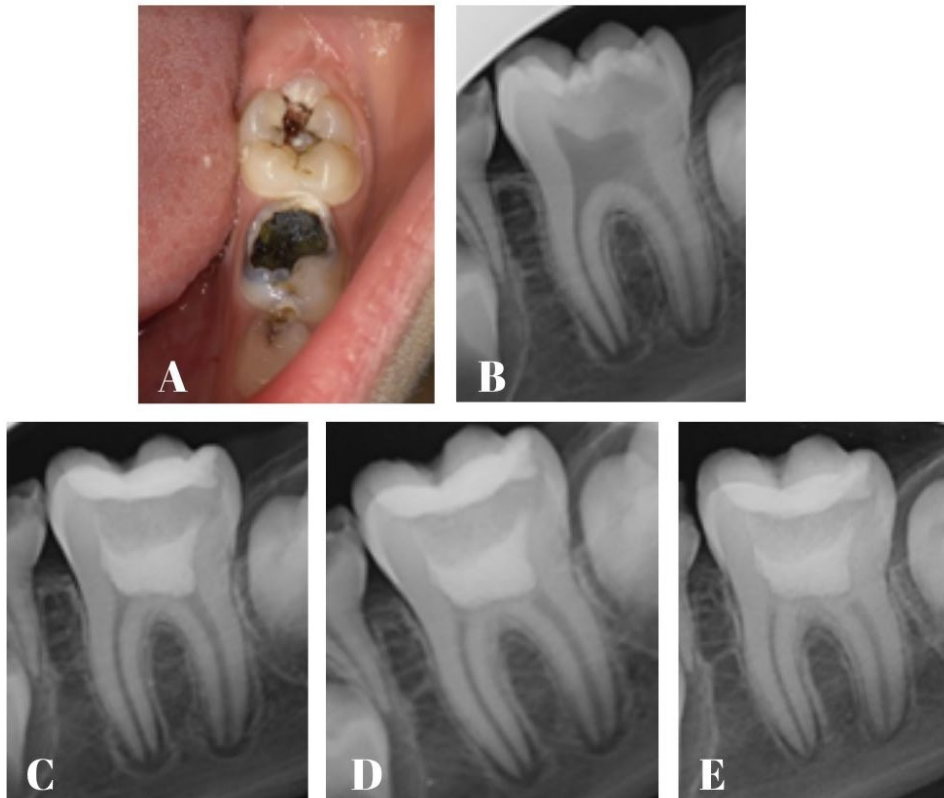


**Figure 2.** A: Preoperative photograph showing tooth 14 with deep dentin caries, B: Preoperative radiograph of tooth 14, C-D-E: 6,12 and 18 months follow-up.

### Case 3

An 8-year-old boy patient was applied to the our clinic with pain in the lower left region. The patient stated that the pain disappeared after the stimulus was removed. Intraoral examination showed deep dentin caries and percussion sensitivity in tooth 36 (Figure 3A). Radiographic examination did not reveal any negative findings in tooth 36, which had not completed root development (Figure 3B). After

clinical and radiographic examination, tooth 36 was diagnosed with reversible pulpitis. A coronal pulpotomy was performed after the caries were removed because the pulpal exposure area was more than 2 mm. Coronal pulpotomy treatment was performed according to the procedure. The tooth was asymptomatic at 6, 12 and 18 months (Figure 3C, 3D, 3E). At the end of the 18th month, root elongation, an increase in dentin thickness, closure of the apex and dentin bridge formation were observed.

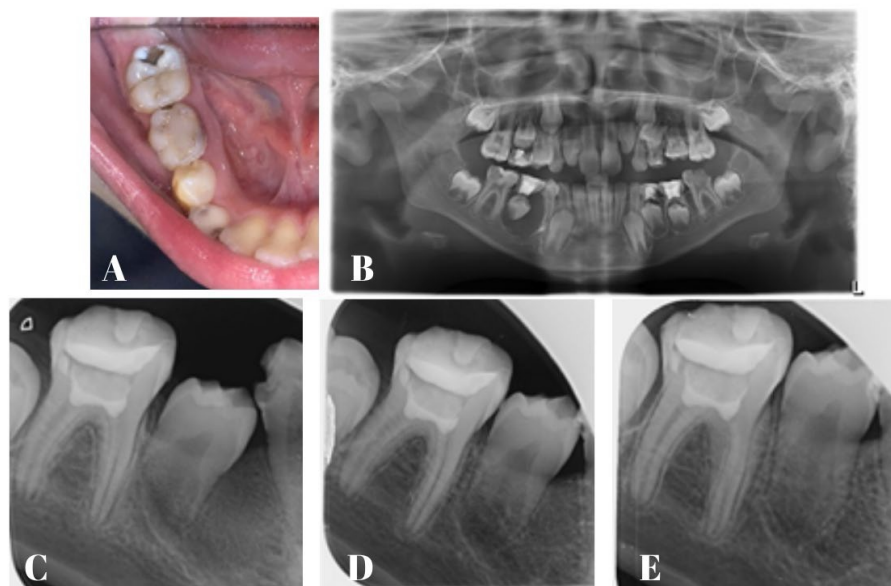


**Figure 3.** **A:** Preoperative photograph showing tooth 36 with deep dentin caries, **B:** Preoperative radiograph of tooth 36, **C-D-E:** 6,12 and 18 months follow-up.

#### Case 4

An 8-year-old boy patient was applied to our clinic with severe pain in the lower right region. The pain started spontaneously and was persistent. Intraoral examination of the patient revealed deep dentin caries in tooth 46 (Figure 4A). There was percussion sensitivity in the tooth. At the same time, hyperemia and swelling were observed in the buccal area of tooth number 85. A panoramic radiograph of the patient showed a lesion on the apical aspect of tooth 85 involving the permanent tooth germ. Deep dentin caries associated with the pulp was observed in tooth 46, which also complained of pain (Figure 4B). After clinical and radiologic examination, tooth 46 was diagnosed as symptomatic irreversible pulpitis and the lesion in the root of tooth 85 was consulted to the surgical department with a prediagnosis of inflammatory odontogenic cyst. In the first session, under local anesthesia and rubber dam

isolation, the coronal pulp was completely removed after caries removal in tooth 46. Since bleeding control was successfully achieved, coronal pulpotomy treatment was performed. The patient had no symptoms at 6, 12 and 18 months (Figure 4C, 4D, 4E). At the end of the 18th month, an increase in dentin thickness, root elongation and closure of the apex were observed.



**Figure 4.** **A:** Preoperative photograph showing tooth 46 with deep dentin caries, **B:** Preoperative radiograph, **C-D-E:** 6,12 and 18 months follow-up.

## DISCUSSION

Currently, it has been reported that coronal pulpotomy from VPT can be thought of as an alternative to RCT, including in teeth considered to have irreversibly inflamed pulp.<sup>24</sup> As a minimally invasive approximation to dentistry, VPT has advantages such as preservation of tooth tissue, elimination of complications associated with complex root canal anatomy, less painful procedure and reduced cost and time spent in the clinic.<sup>10</sup> The less painful and shorter duration of the clinical procedure also helps pediatric patients comply with the treatment.

Clinical signs of IP do not always indicate that the pulp has been damaged beyond repair.<sup>25</sup> Even in cases showing irreversible changes or signs of necrosis, these changes have been found to be limited to the coronal pulp tissue, with reactions less severe in the rest of the coronal tissues and normal uninflamed pulpal tissue in the roots as well as in the contralateral pulpal horn.<sup>9</sup> A meta-analysis by Ather et al. reported an 84% success rate of coronal pulpotomy in caries-exposed teeth with symptomatic IP, compared to 91.3% in teeth with asymptomatic IP, with no significant difference between them.<sup>26</sup>

The most important influencing factors for the success of coronal pulpotomy treatment are microbial contamination and bleeding status.<sup>13</sup> In this case series, a rubber dam was used to isolate the procedure site from the oral cavity and saliva. There is no reliable tool that can be used clinically to determine how deep the caries-induced inflammation has progressed into the pulp.<sup>27</sup> Researchers recommend observing and controlling bleeding rather than clinical symptoms to comment on pulp health.<sup>27,28</sup> Bleeding time has been used as an indicator of the spread of inflammation, and pulpectomy has been recommended if bleeding cannot be controlled within 5-10 minutes.<sup>29</sup> Researchers recommend NaOCl for both rapid bleeding control and disinfection of the area.<sup>23,30,31</sup> NaOCl concentration varies in different studies, and 2.5% NaOCl was used for bleeding control in the cases presented.<sup>32</sup>

It has been revealed that a vital dental pulp can be seen in a symptomatic carious tooth with a periapical lesion; therefore, apical periodontitis does not always indicate a necrotic pulp.<sup>33</sup> Only one of the 4 cases presented had periapical radiolucency. In this tooth, which was treated with coronal pulpotomy, hard tissue formation was observed at the end of the 18th month.

Studies in the literature have also revealed successful results of coronal pulpotomy in teeth with periapical radiolucency.<sup>34,35</sup> However, in the 4 cases presented, an increase in dentin thickness and root length elongation were observed after 18 months of follow-up.

The pulp capping material should create an artificial barrier between the vital pulp and the oral cavity to prevent the entry of microorganisms, be non-toxic to the pulp and have antimicrobial properties, and stimulate hard tissue regeneration. Due to its bioactive and biocompatible properties, MTA is a commonly used material with highly successful results.<sup>14,36</sup> Today, calcium silicate-containing bioceramic materials such as Biodentine and BioAggregate are also used in vital pulp treatments.<sup>37-39</sup> In our study, MTA, which is considered the gold standard, was used in all cases and successful results were obtained by determining that hard tissue regeneration occurred. It has been reporting that to evaluate the success of pulpotomy treatments, treated teeth should be followed up at 6 and 12 months postoperatively and then annually for four years if necessary.<sup>23</sup> All of the presented cases were followed up until the 18th month and no adverse findings were observed. However, long-term follow-up is still required to reveal late failures of VPT. When the study is evaluated in terms of its limitations, it is a case series conducted on 4 cases. Although the study results were successful, evidence-based clinical studies are needed.

## CONCLUSION

Within the restrictions of this case reports the 18-month follow-up results were found to be successful. According to these results, coronal pulpotomy treatment can be applied to symptomatic teeth in accordance with the minimally invasive dentistry approach.

## Ethical Approval

Since the present study did not use sources derived from humans or animals, ethics committee approval was not obtained.

## Financial Support

The authors declare that this study received no financial support.

## Conflict of Interest

The authors deny any conflicts of interest related to this study.

## Author Contributions

Design: MA, Data collection or data entry: MA, MB, Analysis and interpretation: MA, MB, Literature search: MA, Writing: MA.

## REFERENCES

1. Innes N, Frencken JE, Bjørndal L, Maltz M, Manton DJ, Ricketts D et al. Managing carious lesions: consensus recommendations on terminology. *Adv Dent Res.* 2016;28:49-57.
2. Careddu R and Duncan HF. A prospective clinical study investigating the effectiveness of partial pulpotomy after relating preoperative symptoms to a new and established classification of pulpitis. *Int Endod J.* 2021;54:2156-72.
3. Zhang W, and Yelick PC. Vital pulp therapy-current progress of dental pulp regeneration and revascularization. *Int J Dent.* 2010;856087.
4. Owatz CB, Khan AA, Schindler WG, Schwartz SA, Keiser K, and Hargreaves KM. The incidence of mechanical allodynia in patients with irreversible pulpitis. *J Endod.* 2007;33:552-6.
5. Chen E, and Abbott PV. Dental pulp testing: a review. *Int J Dent.* 2009;365785.
6. Baume LJ. Diagnosis of diseases of the pulp. *Oral Surg Oral Med, Oral Pathol.* 1970;29:102-16.
7. Dummer PMH, Hicks R, Huws D. Clinical signs and symptoms in pulp disease. *Int Endod J.* 1980;13:27-35.
8. Rechenberg DK, Zehnder M. Call for a review of diagnostic nomenclature and terminology used in endodontics. *Int Endod J.* 2020;53:1315-17.
9. Ricucci D, Siqueira Jr JF, Li Y, Tay FR. Vital pulp therapy: histopathology and histobacteriologybased guidelines to treat teeth with deep caries and pulp exposure. *J Dent.* 2019;86:41-52.



10. Wolters WJ, Duncan HF, Tomson PL, Karim IE, McKenna G, Dorri M et al. Minimally invasive endodontics: a new diagnostic system for assessing pulpitis and subsequent treatment needs. *Int Endod J.* 2017;50:825-9.
11. Bogen G, Dammaschke T, Chandler N. Vital pulp therapy. In: Berman L, Hargreaves KM, editors. *Pathways of the pulp.* 12th ed. St. Louis, MO: Elsevier; 2021. 902-38 p.
12. Lin LM, Ricucci D, Saoud TM, Sigurdsson A, Kahler, B. Vital pulp therapy of mature permanent teeth with irreversible pulpitis from the perspective of pulp biology. *Aust Endod J.* 2020;46:154-65.
13. Leong DJX, Yap AU. Vital pulp therapy in carious pulp-exposed permanent teeth: an umbrella review. *Clin Oral Investig.* 2021;25:6743-56.
14. Li Y, Sui B, Dahl C, Bergeron B, Shipman P, et al. Pulpotomy for carious pulp exposures in permanent teeth: A systematic review and meta-analysis. *J Dent.* 2019;84:1-8.
15. Camoni N, Cagetti MG, Cirio S, Esteves-Oliveira M, Campus G. Partial pulpotomy in young permanent teeth: A systematic review and meta-analysis. *Children.* 2023;10:1447.
16. El Meligy OA, Avery DR. Comparison of mineral trioxide aggregate and calcium hydroxide as pulpotomy agents in young permanent teeth (apexogenesis). *Pediatr Dent.* 2006;28:399-404.
17. Simon S, Perard M, Zanini M, Smith AJ, Charpentier E, et al. Should pulp chamber pulpotomy be seen as a permanent treatment? Some preliminary thoughts. *Int End J.* 2013;46:79-87.
18. Ghoddusi J, Shahrami F, Alizadeh M, Kianoush K, Forghani M. Clinical and radiographic evaluation of vital pulp therapy in open apex teeth with MTA and ZOE. *N Y State Dent J.* 2012;78:34-8.
19. Alqaderi HE, Al-Mutawa SA, Qudeimat MA. MTA pulpotomy as an alternative to root canal treatment in children's permanent teeth in a dental public health setting. *J Dent.* 2014;42:1390-5.
20. Qudeimat MA, Alyahya A, Hasan AA, Barrieshi-Nusair KM. Mineral trioxide aggregate pulpotomy for permanent molars with clinical signs indicative of irreversible pulpitis: a preliminary study. *Int Endod J.* 2017;50:126-34.
21. Elmas S, Kotan DA, Odabaş ME. Two-year outcomes of coronal pulpotomy in young permanent molars with clinical signs indicative of irreversible pulpitis. *Pediatr Dent.* 2023;45:46-52.
22. Barngkgei IH, Halboub ES, Alboni RS. Pulpotomy of symptomatic permanent teeth with carious exposure using mineral trioxide aggregate. *Iran Endod J.* 2013;8:65-8.
23. Duncan H, Galler K, Tomson P, Simon S, El-Karim I, Kundzina R, et al. European Society of Endodontology position statement: Management of deep caries and the exposed pulp. *Int End J.* 2019;52:923-34.
24. American Association of Endodontists. AAE position statement on vital pulp therapy. Erişim tarihi: 01.06.2024, [https://www.aae.org/wp-content/uploads/2021/05/VitalPulpTherapyPositionStatement\\_v2.pdf](https://www.aae.org/wp-content/uploads/2021/05/VitalPulpTherapyPositionStatement_v2.pdf).
25. Mobarak A, Genena S, Zaazou A, Mokhless NA, Moussa SM. Regenerative pulpotomy as a novel technique for treatment of permanent mature molars diagnosed with irreversible pulpitis using platelet-rich fibrin: a case series study. *Alex Dent J.* 2021;46:129-35.
26. Ather A, Patel B, Gelfond JA, and Ruparel NB. Outcome of pulpotomy in permanent teeth with irreversible pulpitis: a systematic review and meta-analysis. *Sci Rep.* 2022;12:19664.
27. Aguilar P, Linsuwanont P. Vital pulp therapy in vital permanent teeth with cariously exposed pulp: A systematic review. *J Dent.* 2011;37:581-7.
28. Zanini M, Hennequin M, Cousson PY. A review of criteria for the evaluation of pulpotomy outcomes in mature permanent teeth. *J Endod.* 2016;42:1167-74.
29. Duncan HF, El-Karim I, Dummer PM, Whitworth J, Nagendrababu V. Factors that influence the outcome of pulpotomy in permanent teeth. *Int Endod J.* 2023;56:62-81.

30. Taha NA, Abdelkhader SZ. Outcome of full pulpotomy using Biodentine in adult patients with symptoms indicative of irreversible pulpitis. *Int Endod J.* 2018;8:819-28.
31. Galani M, Tewari S, Sangwan P, Mittal S, Kumar V, Duhan J. Comparative evaluation of postoperative pain and success rate after pulpotomy and root canal treatment in cariously exposed mature permanent molars: A randomized controlled trial. *J Endod.* 2017;43:1953-62.
32. Hafez AA, Cox CF, Tarim B, Otsuki M, Akimoto N. An in vivo evaluation of haemorrhage control using sodium hypochlorite and direct capping with a one-or two-component adhesive system in exposed nonhuman primate pulps. *Quintessence Int.* 2002;33:261-72.
33. Abella F, Patel S, Duran-Sindreu F, Mercadé M, Bueno R, Roig M. Evaluating the periapical status of teeth with irreversible pulpitis by using cone-beam computed tomography scanning and periapical radiographs. *J Endod.* 2012;38:1588-91.
34. Taha NA, and Abdulkhader SZ. Full pulpotomy with biodentine in symptomatic young permanent teeth with carious exposure. *J Endod.* 2018;44:932-7.
35. Qudeimat M, Alyahya A, Hasan A, and Barrieshi-Nusair K. Mineral trioxide aggregate pulpotomy for permanent molars with clinical signs indicative of irreversible pulpitis: a preliminary study. *Int Endod J.* 2017;50:126-34.
36. Chen Y, Chen X, Zhang Y, Zhou F, Deng J, et. all. Materials for pulpotomy in immature permanent teeth: a systematic review and meta-analysis. *BMC Oral Health.* 2019;19:227.
37. Parirokh M, Torabinejad M, Dummer PMH. Mineral trioxide aggregate and other bioactive endodontic cements: An updated overview - part I: Vital pulp therapy. *Int Endod J.* 2018;51:177-205.
38. Dawood AE, Parashos P, Wong RHK, Reynolds EC, Manton DJ. Calcium silicate-based cements: Composition, properties, and clinical applications. *J Investig Clin Dent.* 2017;8:e12195.
39. Cho SY, Seo DG, Lee SJ, Lee J, Lee SJ, Jung IY. Prognostic factors for clinical outcomes according to time after direct pulp capping. *J Endod.* 2013;39:327-31.